

# distal femur; extra-articular resection

♂ 63

lateral knee pain since August 2007

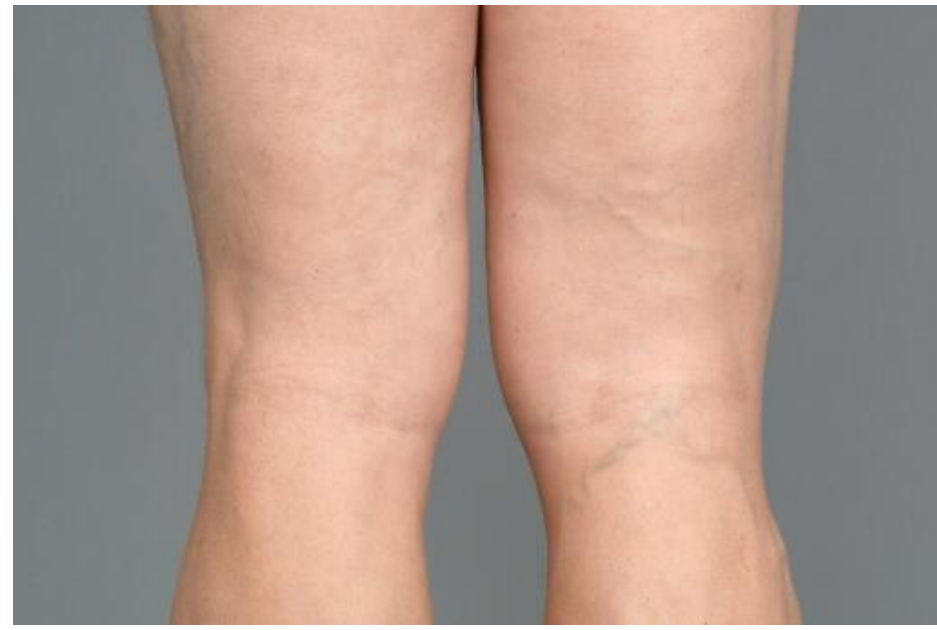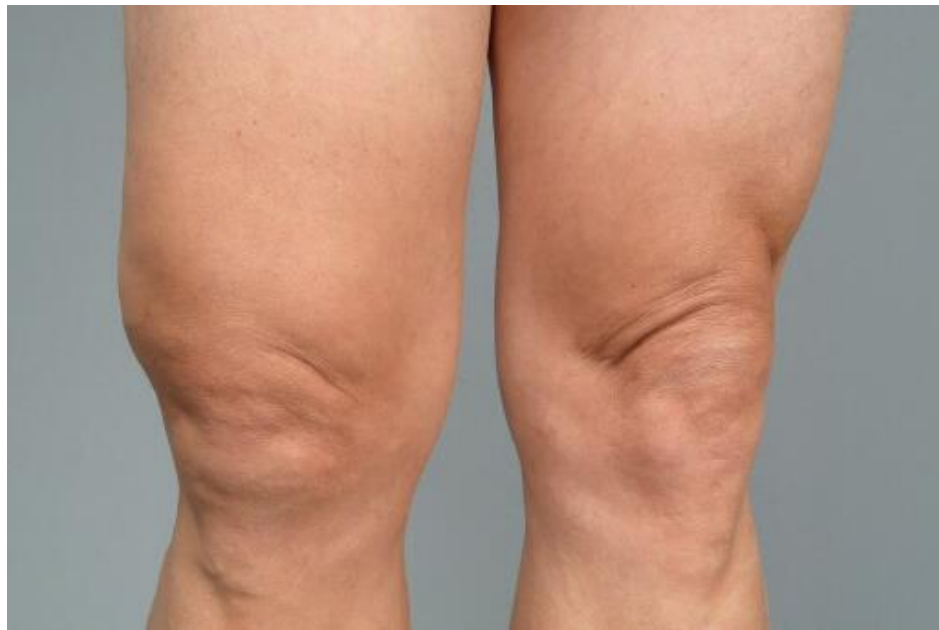fullness, F/E 100/0/0

PMH:

heavy smoker, otherwise  
uneventful

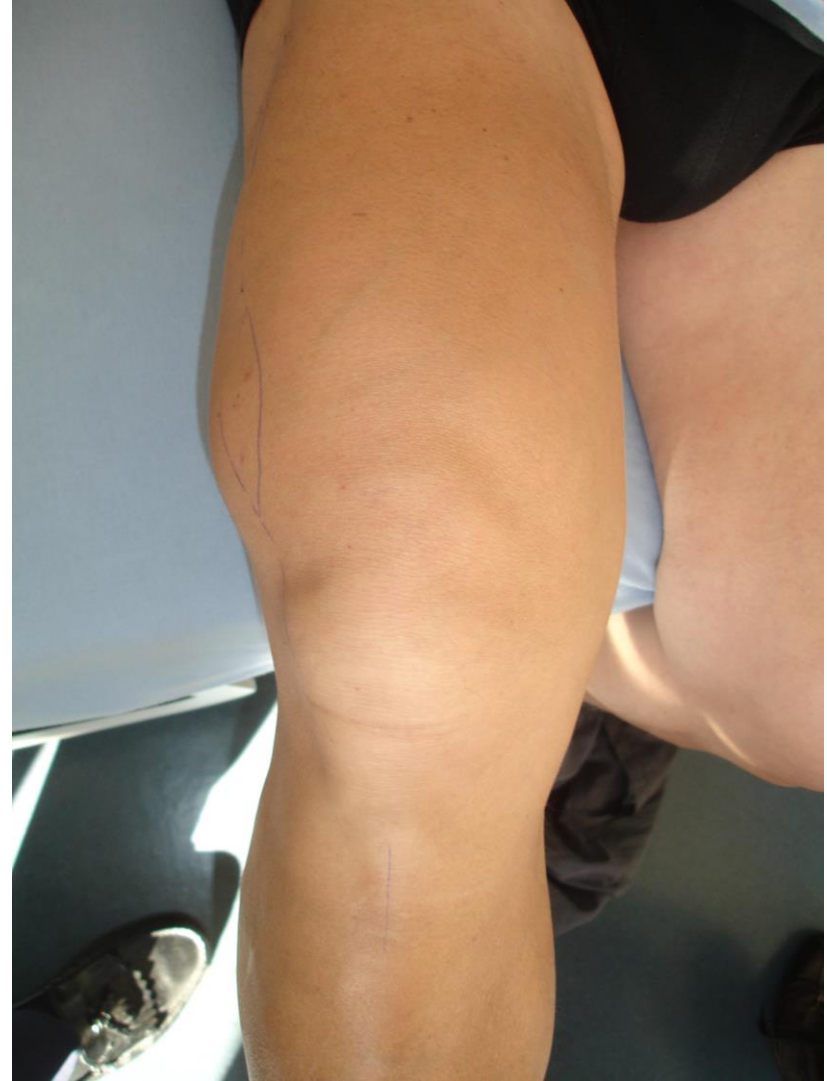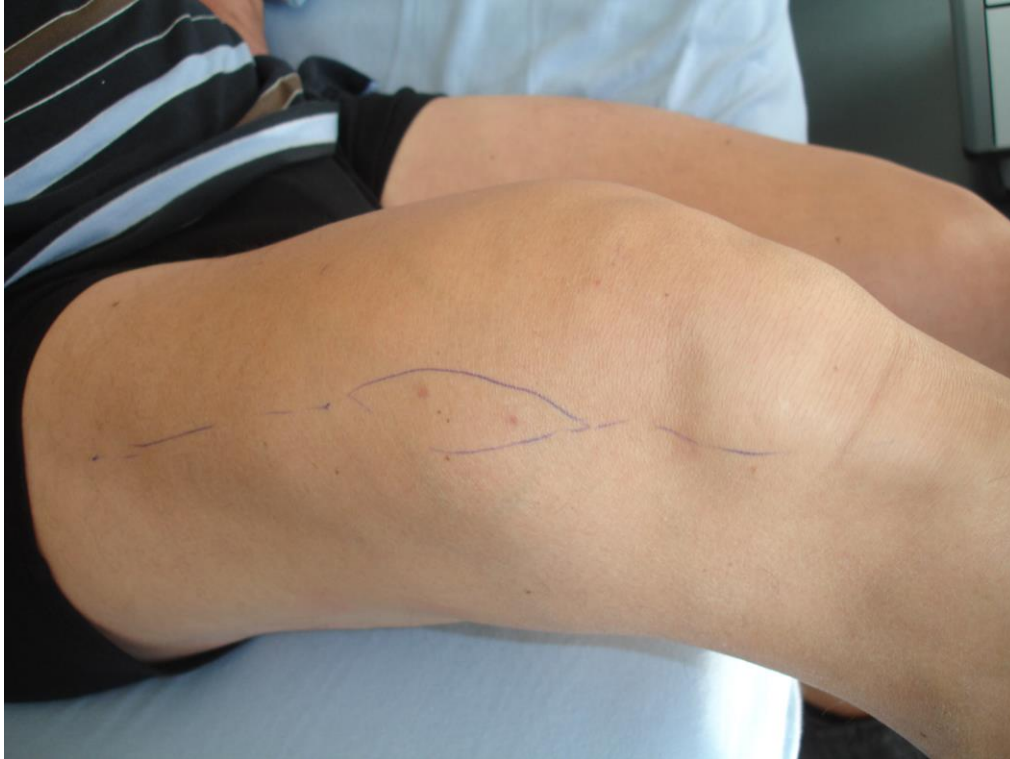# distal femur; extra-articular resection

Aug 6 2008



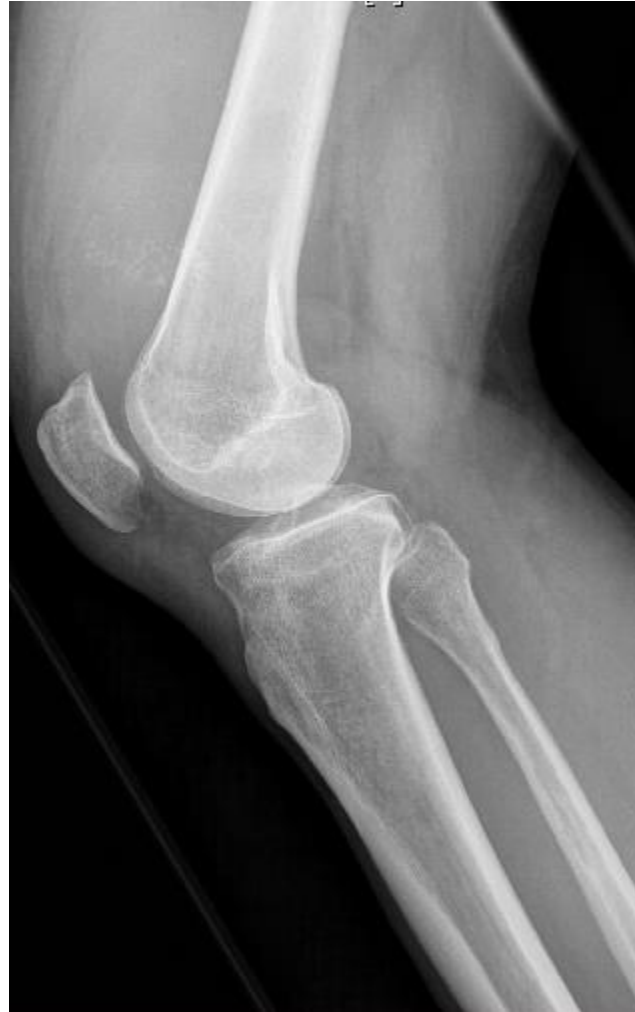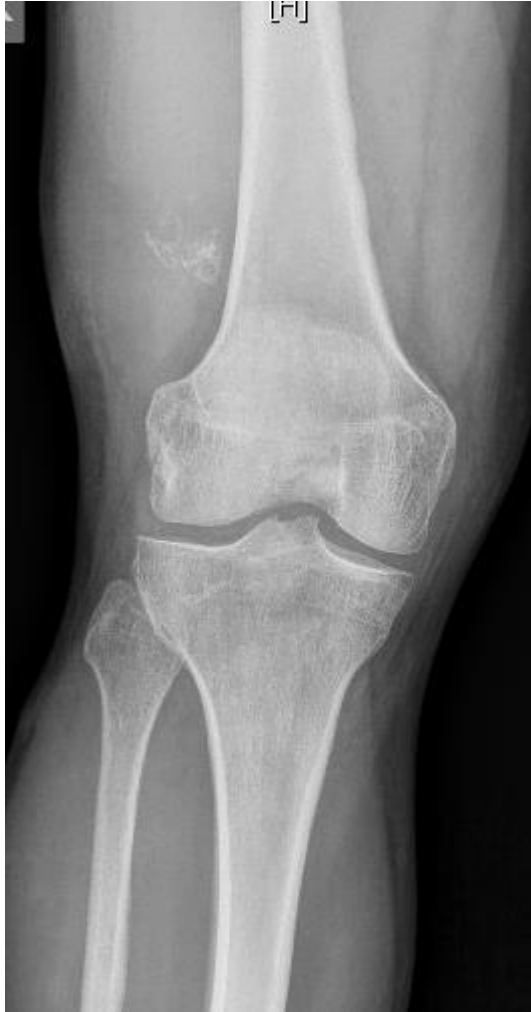# distal femur; extra-articular resection

Sept 8 2008



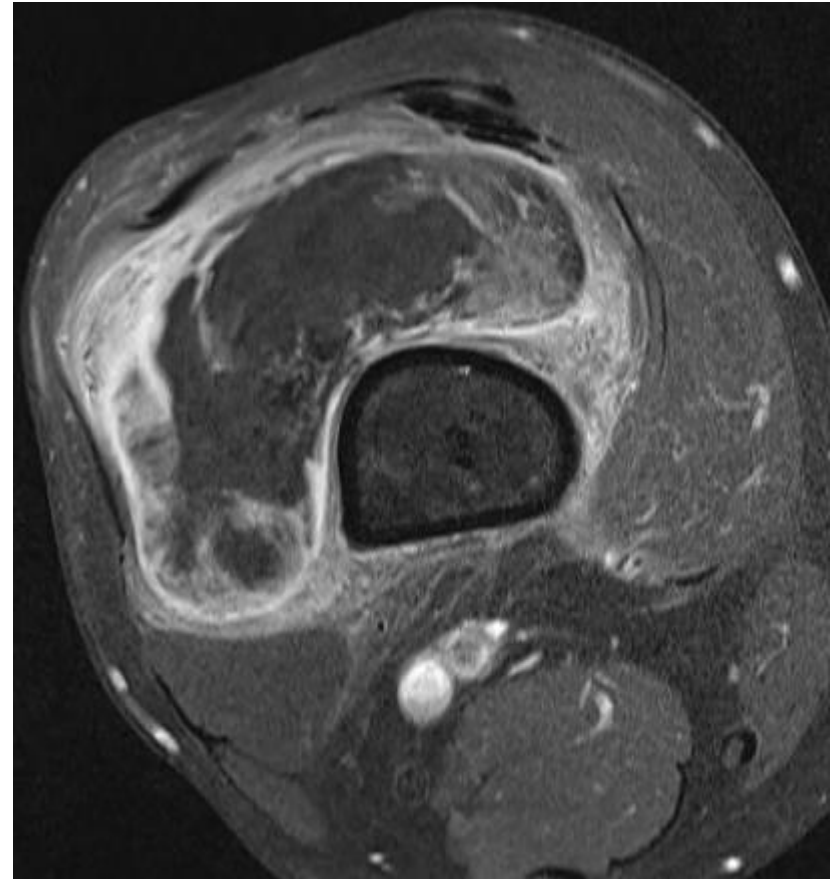
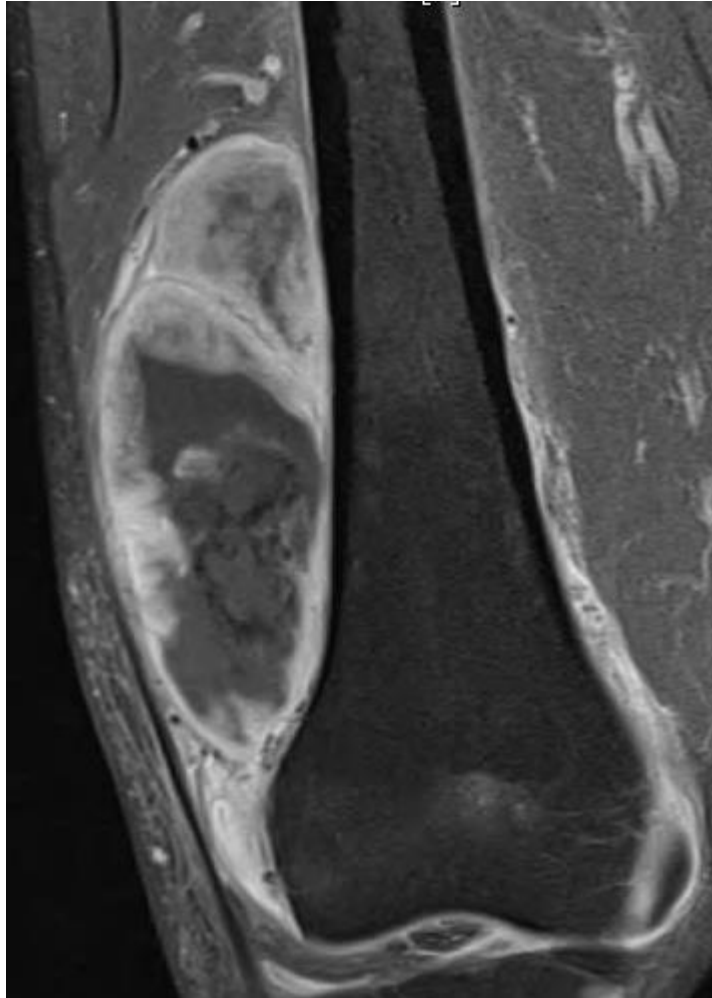
# distal femur; extra-articular resection

Aug 6, 2008



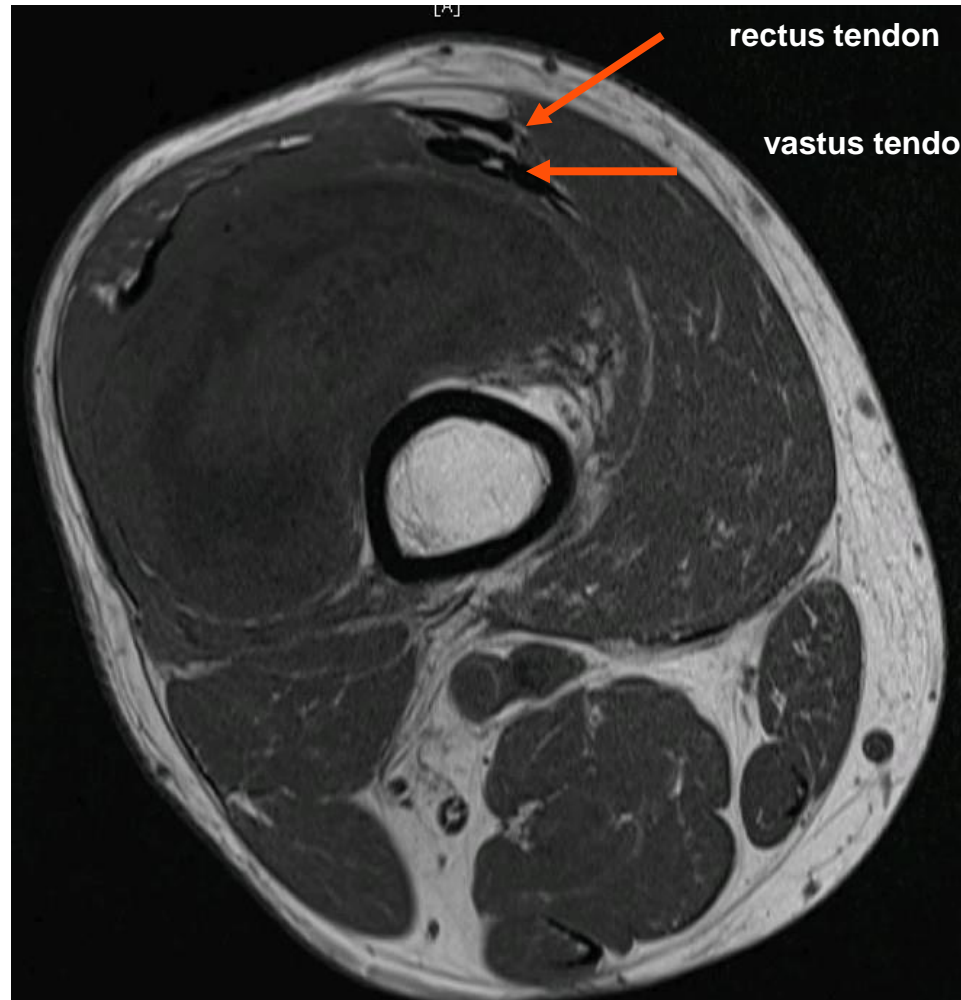# distal femur; extra-articular resection

June 20, 2008



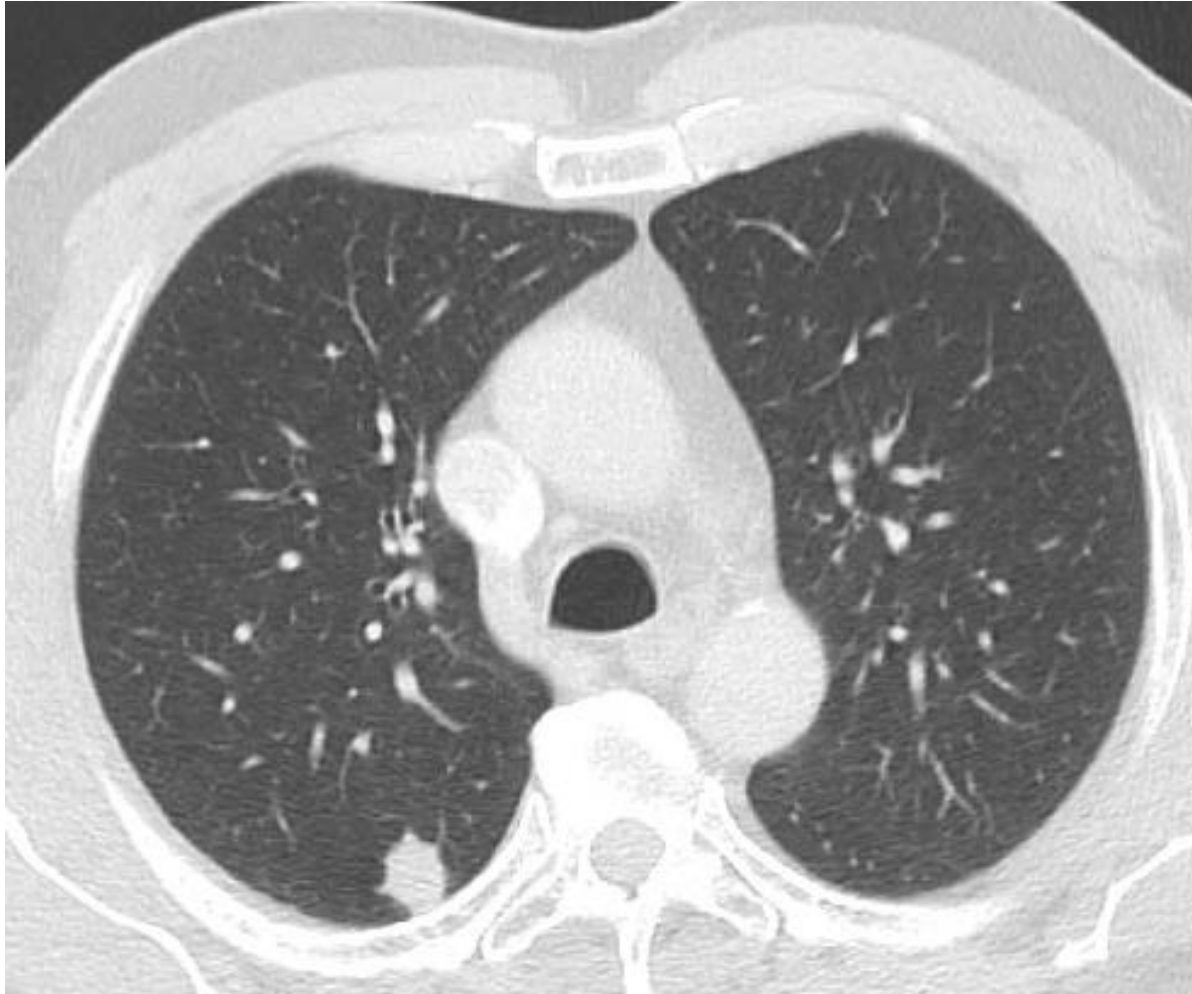
# distal femur; extra-articular resection

June 20, 2008



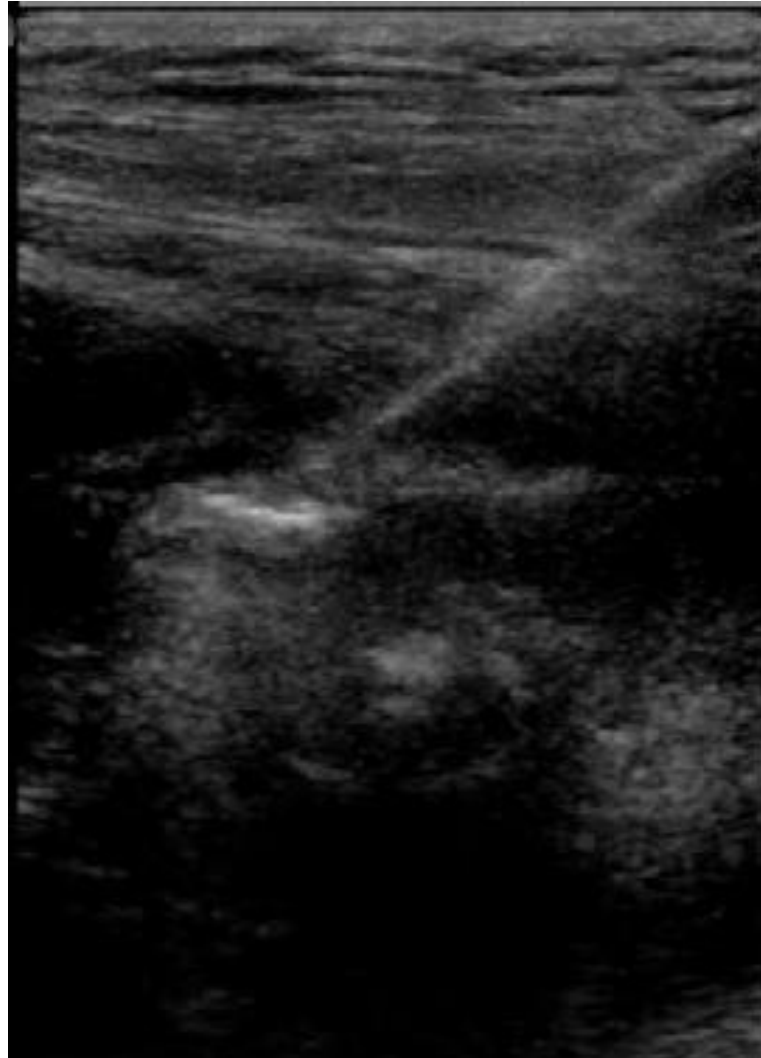# distal femur; extra-articular resection

Aug 6 2008

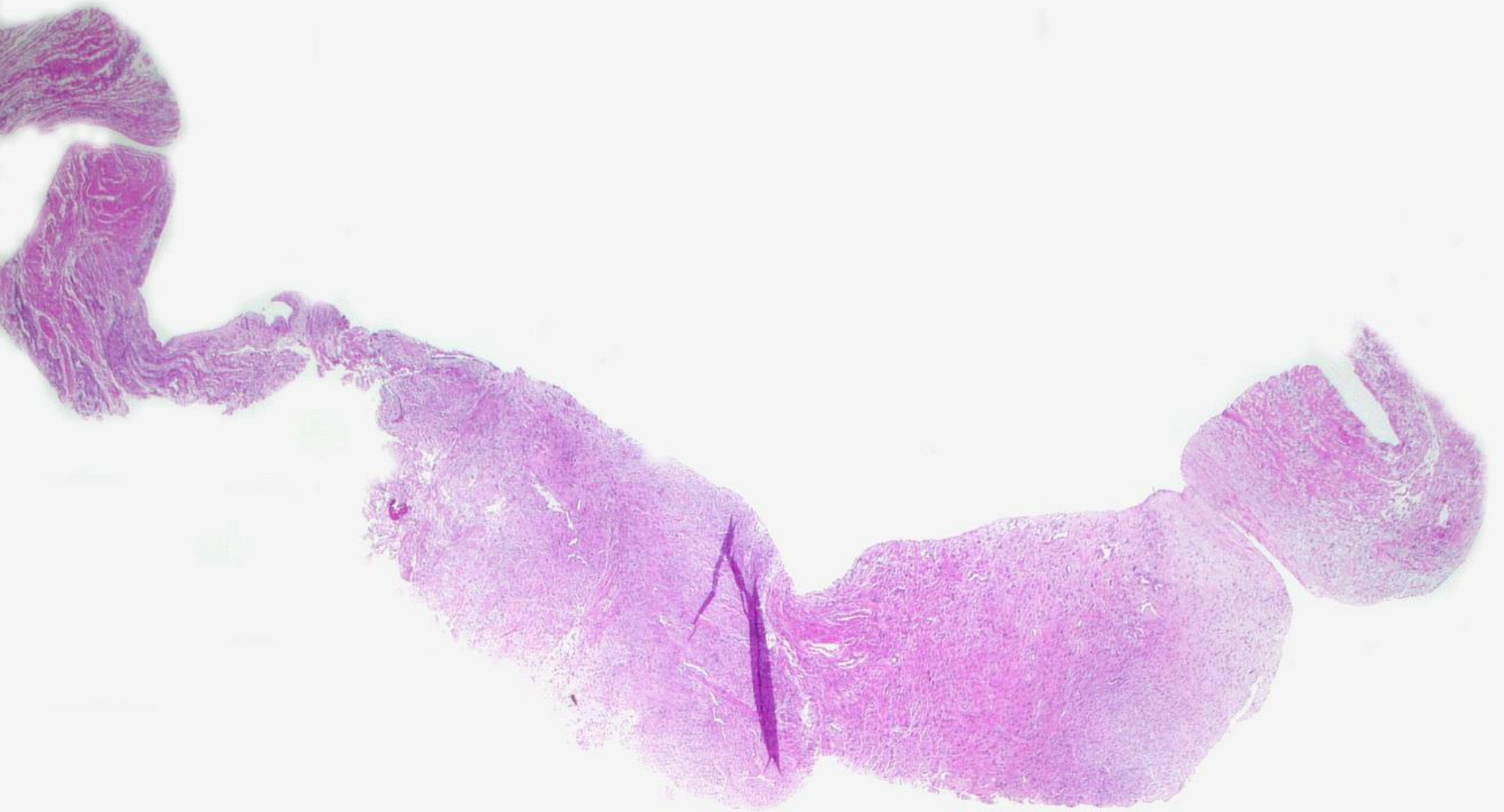


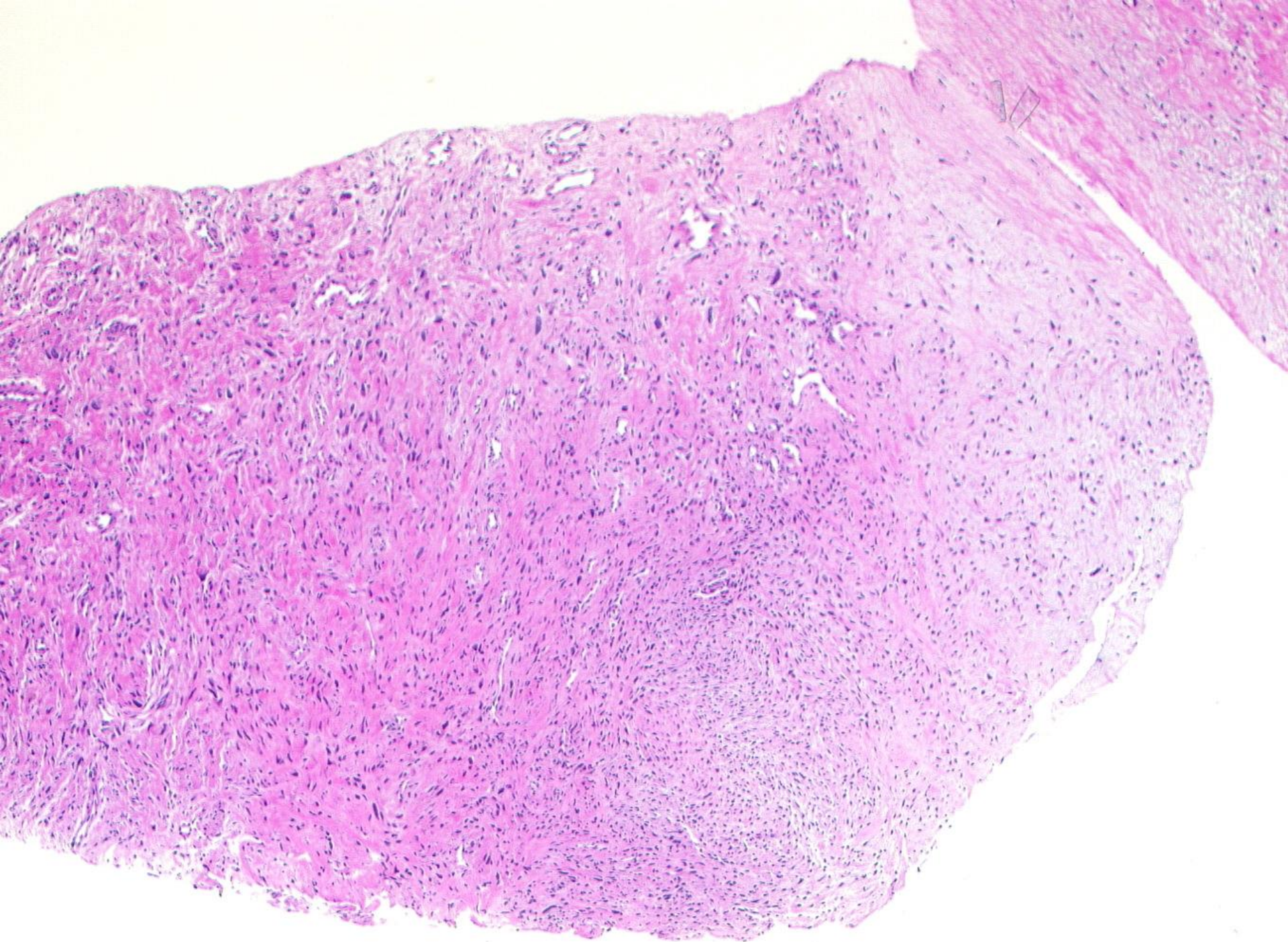
# distal femur; extra-articular resection

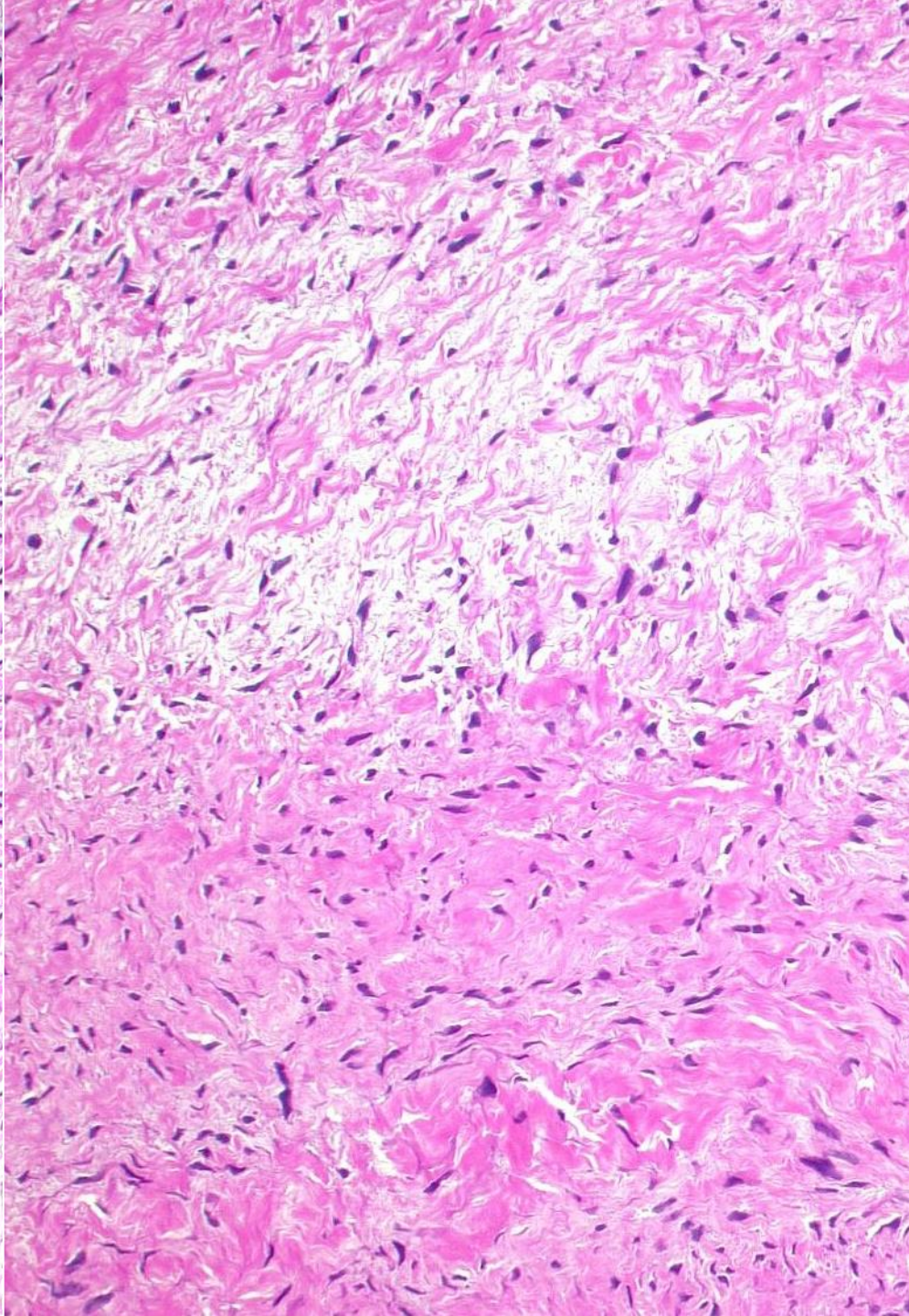
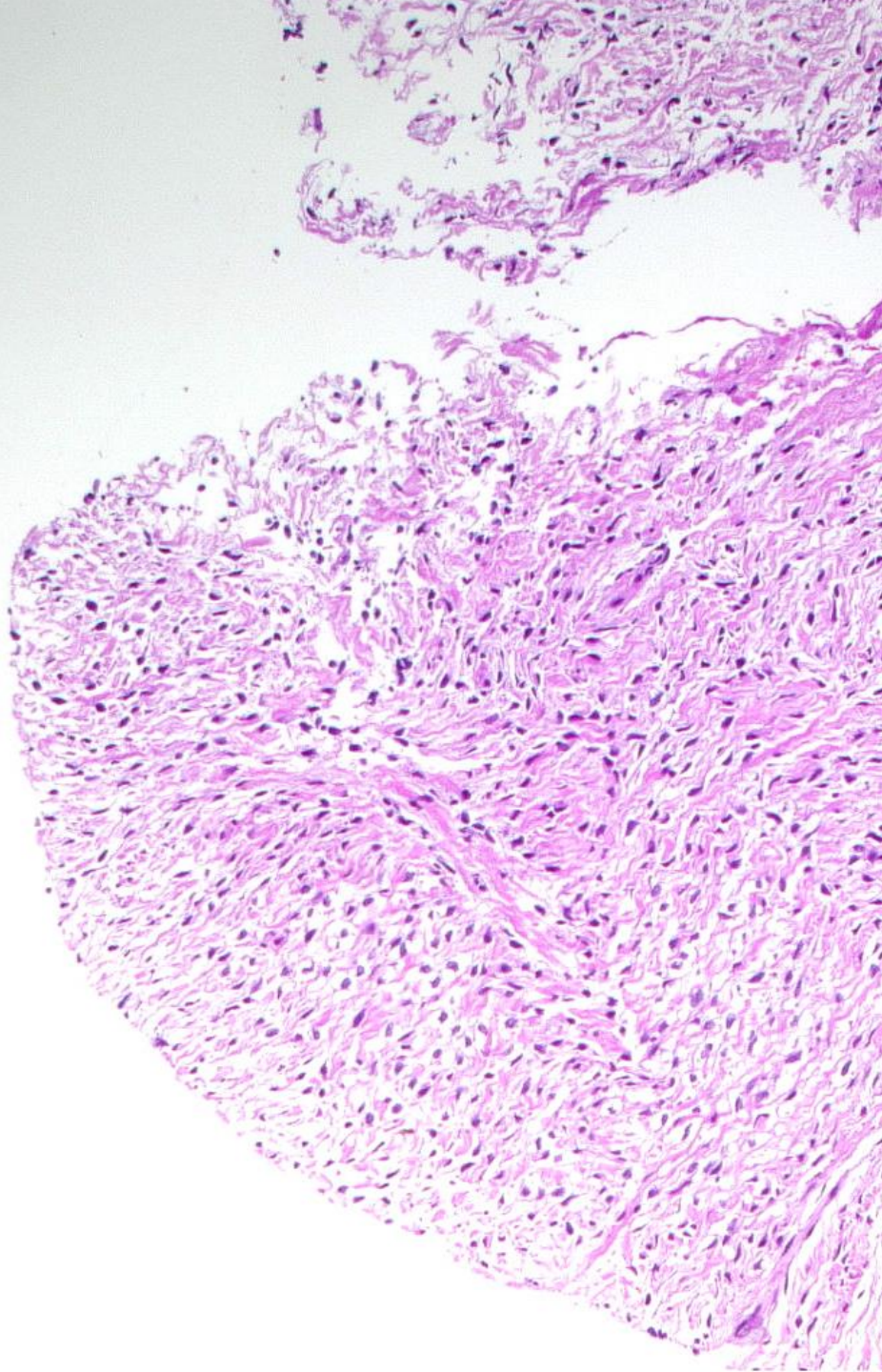
July 22, 2008











# distal femur; extra-articular resection

## Pathology

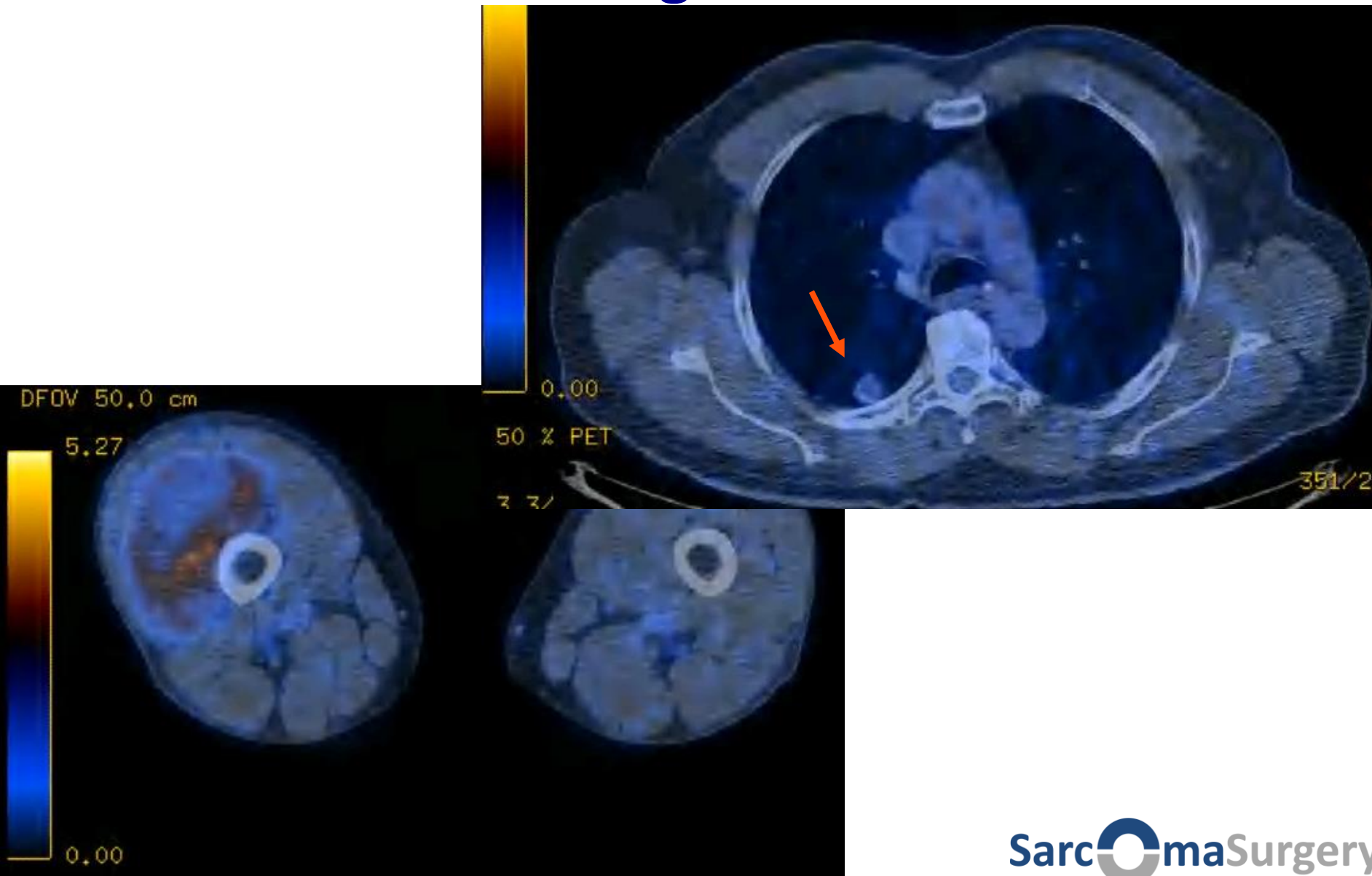
**Biopsy Knee**

**low grade sarcoma**

**„myxofibrosarcoma-type“**

# distal femur; extra-articular resection

## PET-CT August 21 2008



# distal femur; extra-articular resection

**August 29, 2008:**

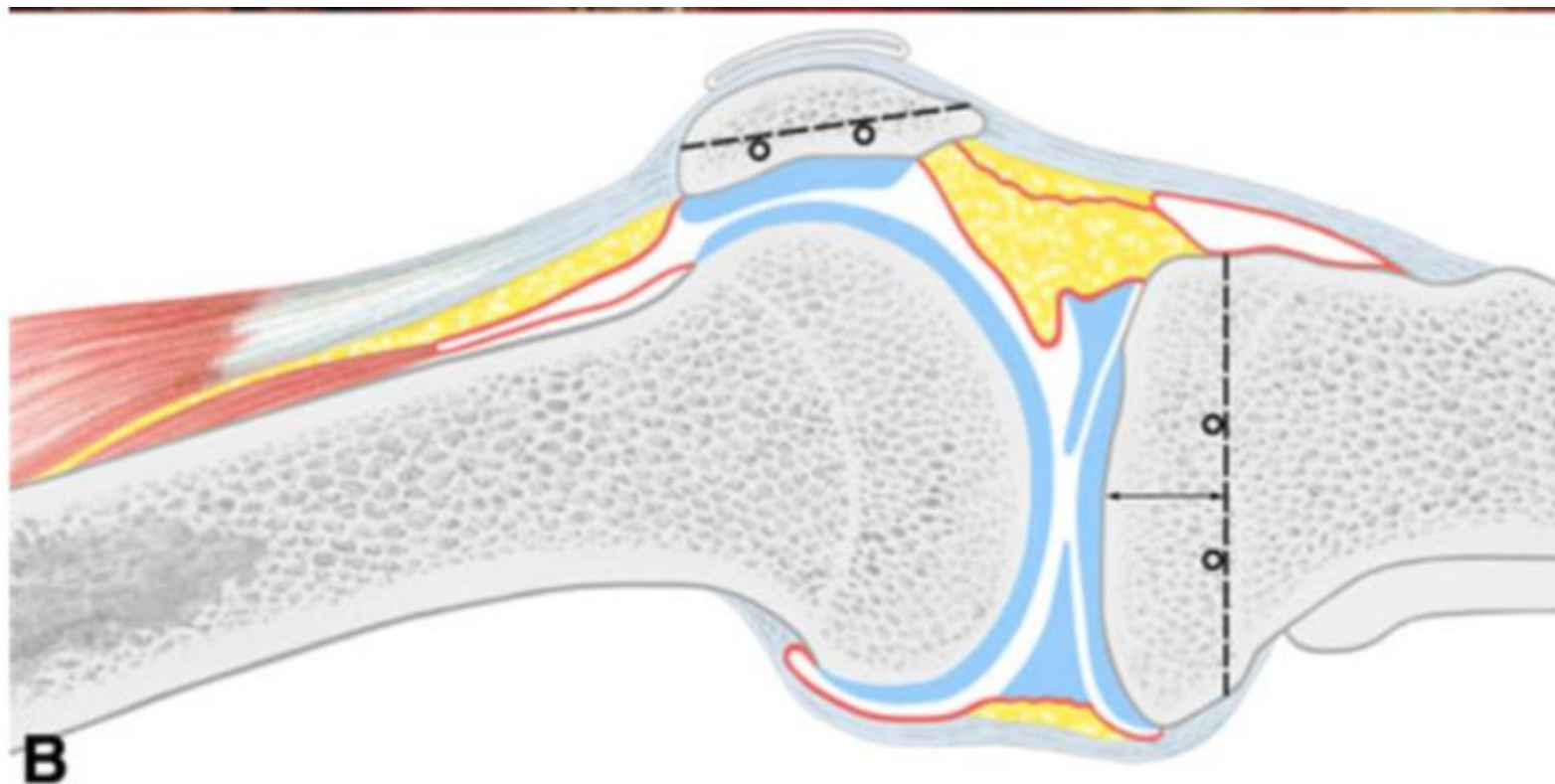
**thoracoscopic wedge resection for  
lung nodule (USZ, Prof.Weder)**

**→ Pathology: metastasis**

# distal femur; extra-articular resection

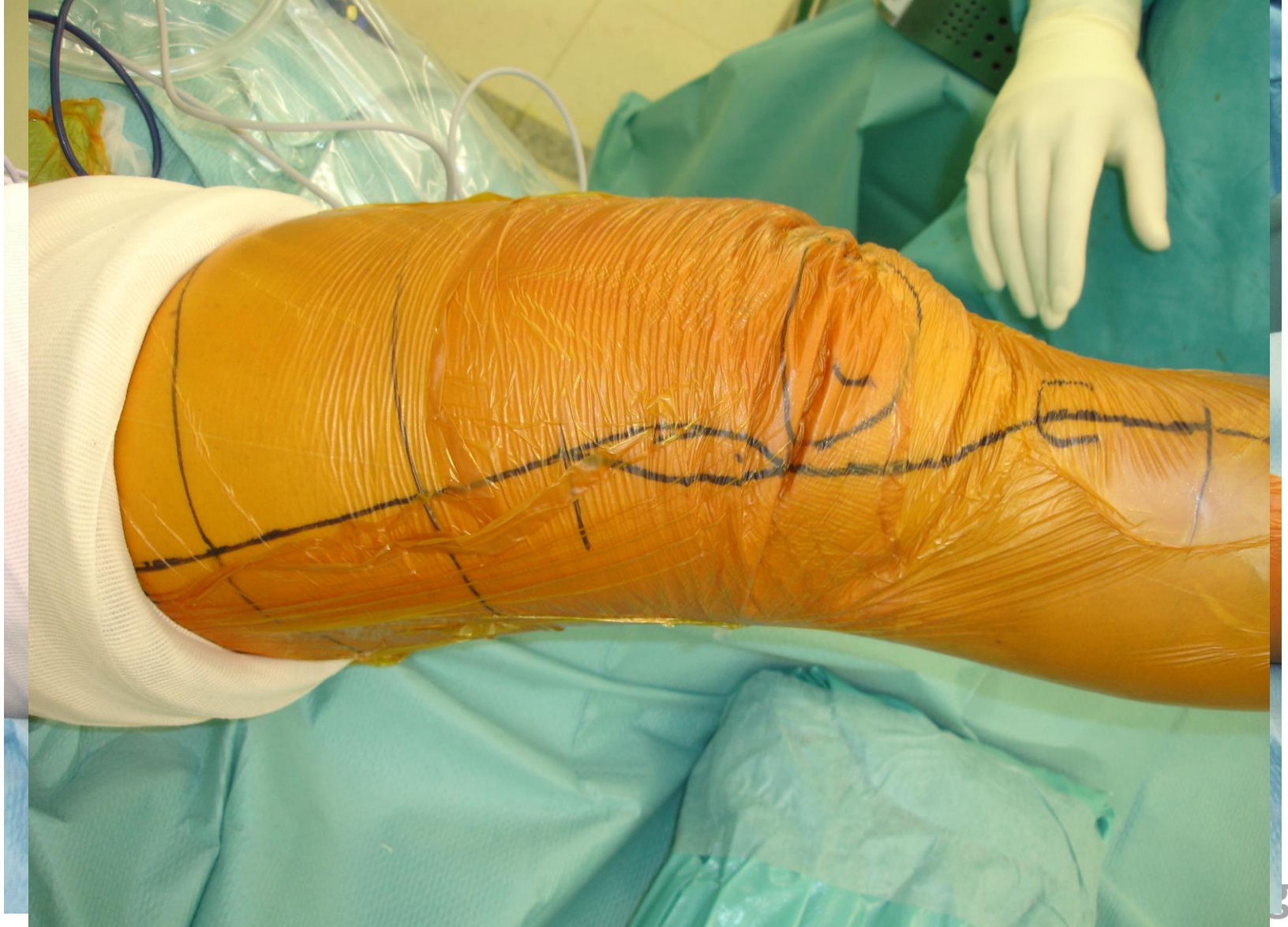Sept 9, 2008:

extra-articular resection of distal femur / knee joint  
(18cm), reconstruction with MUTARS tumor prosthesis  
(hybrid cementation), resurfacing of the patella

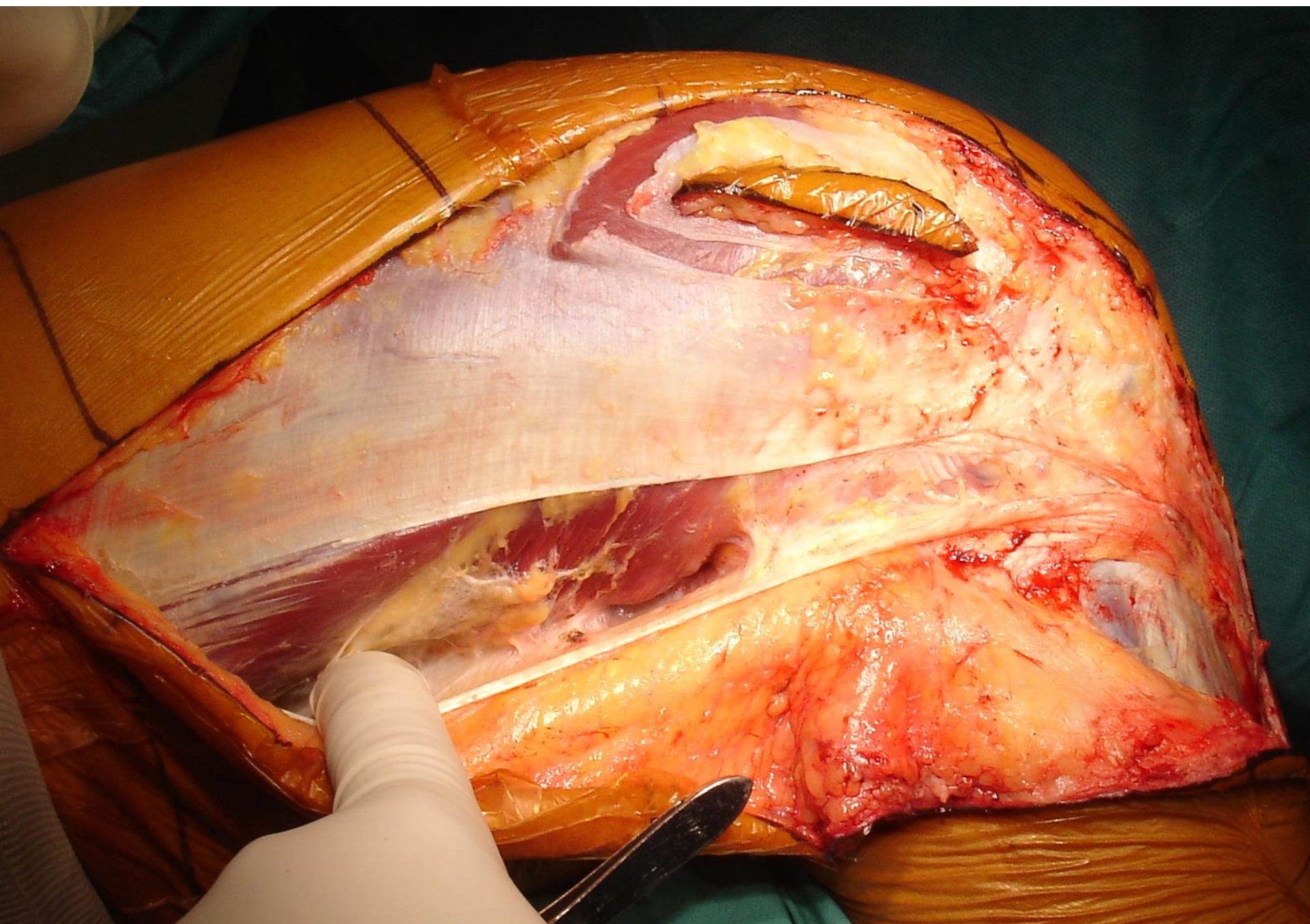


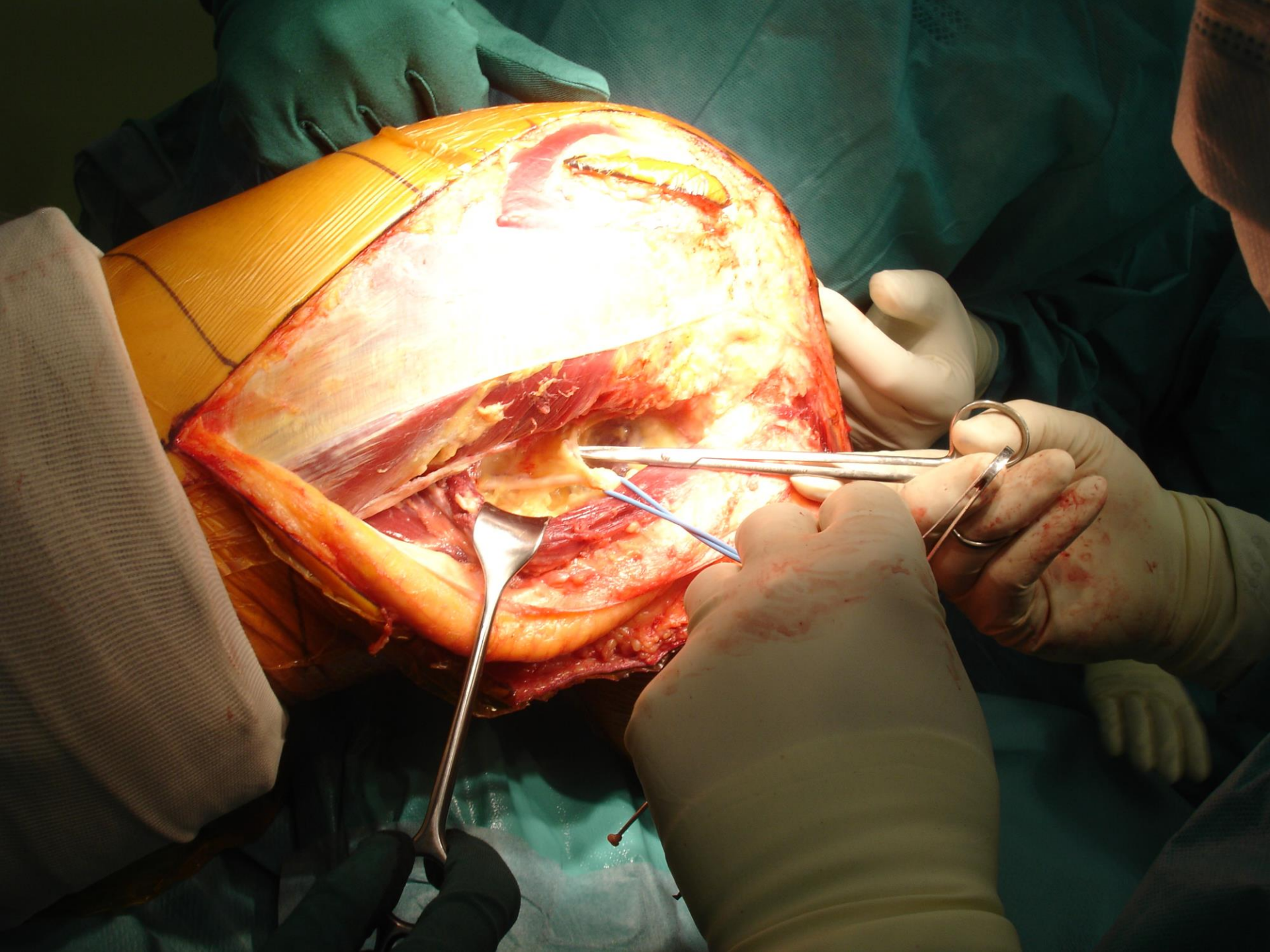
# distal femur; extra-articular resection

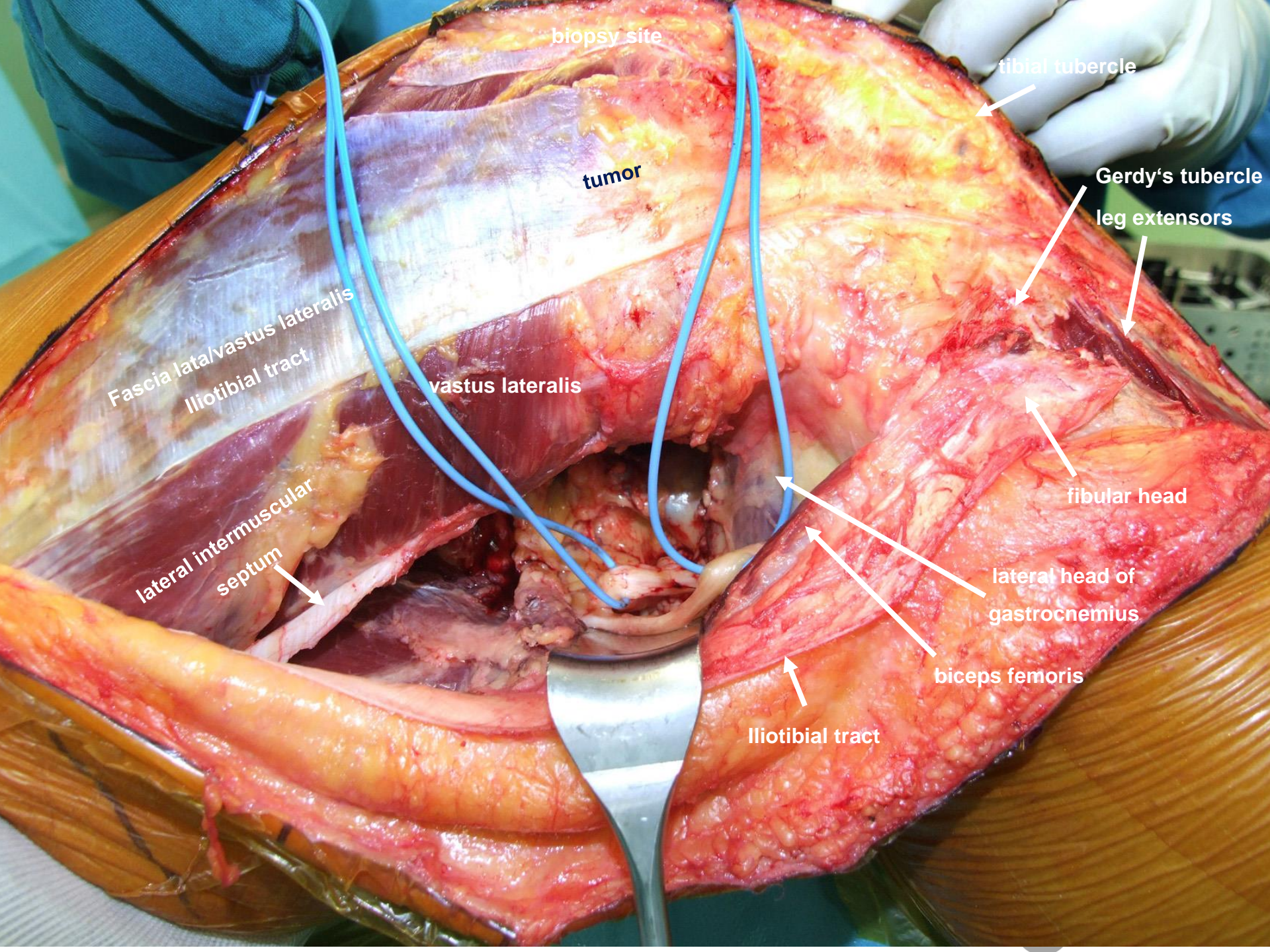
09-09-2008











biopsy site

tibial tubercle

tumor

Gerdy's tubercle

leg extensors

Fascia lata/vastus lateralis  
Iliotibial tract

vastus lateralis

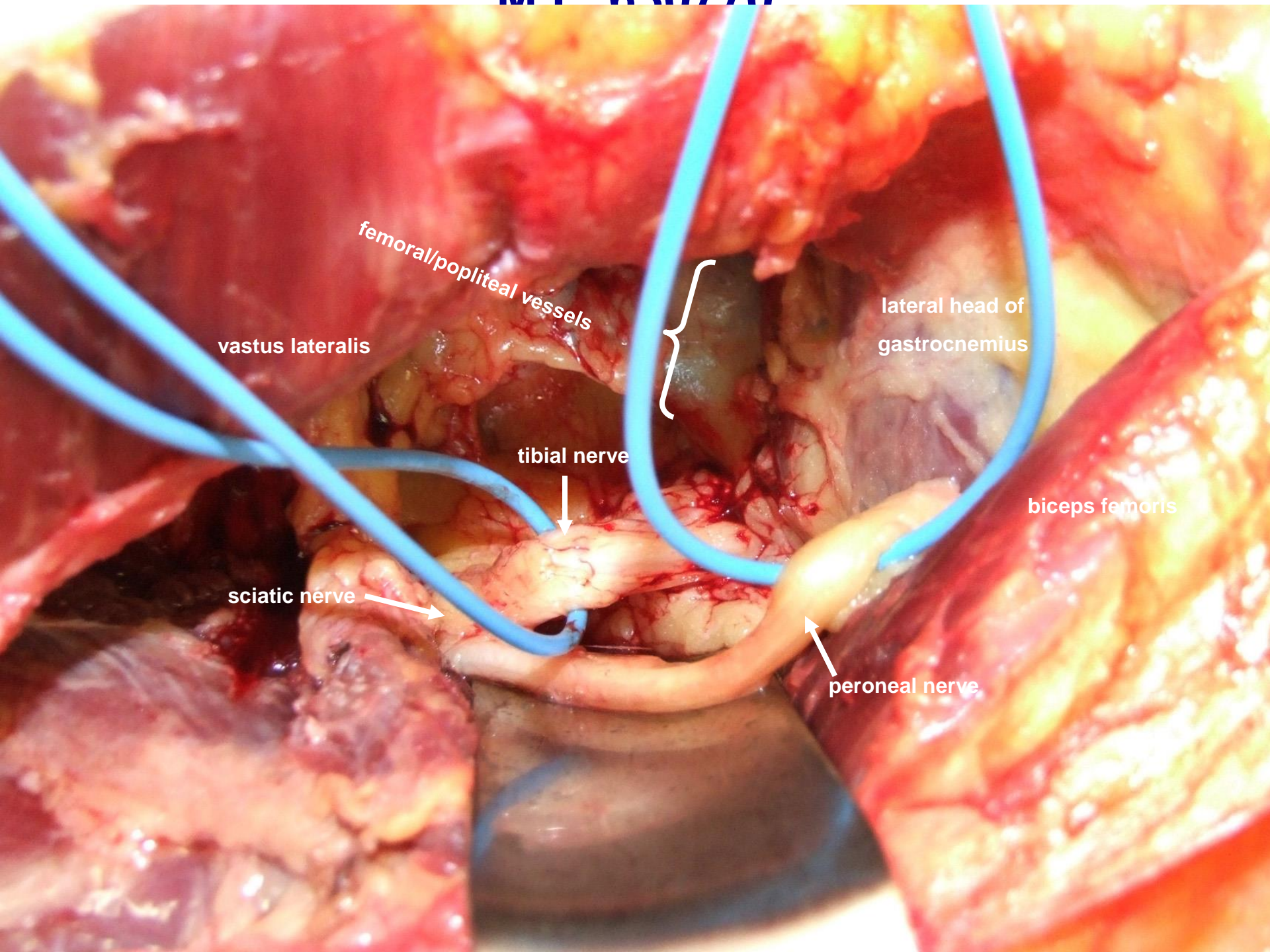
fibular head

lateral intermuscular  
septum

lateral head of  
gastrocnemius

biceps femoris

Iliotibial tract



femoral/popliteal vessels

vastus lateralis

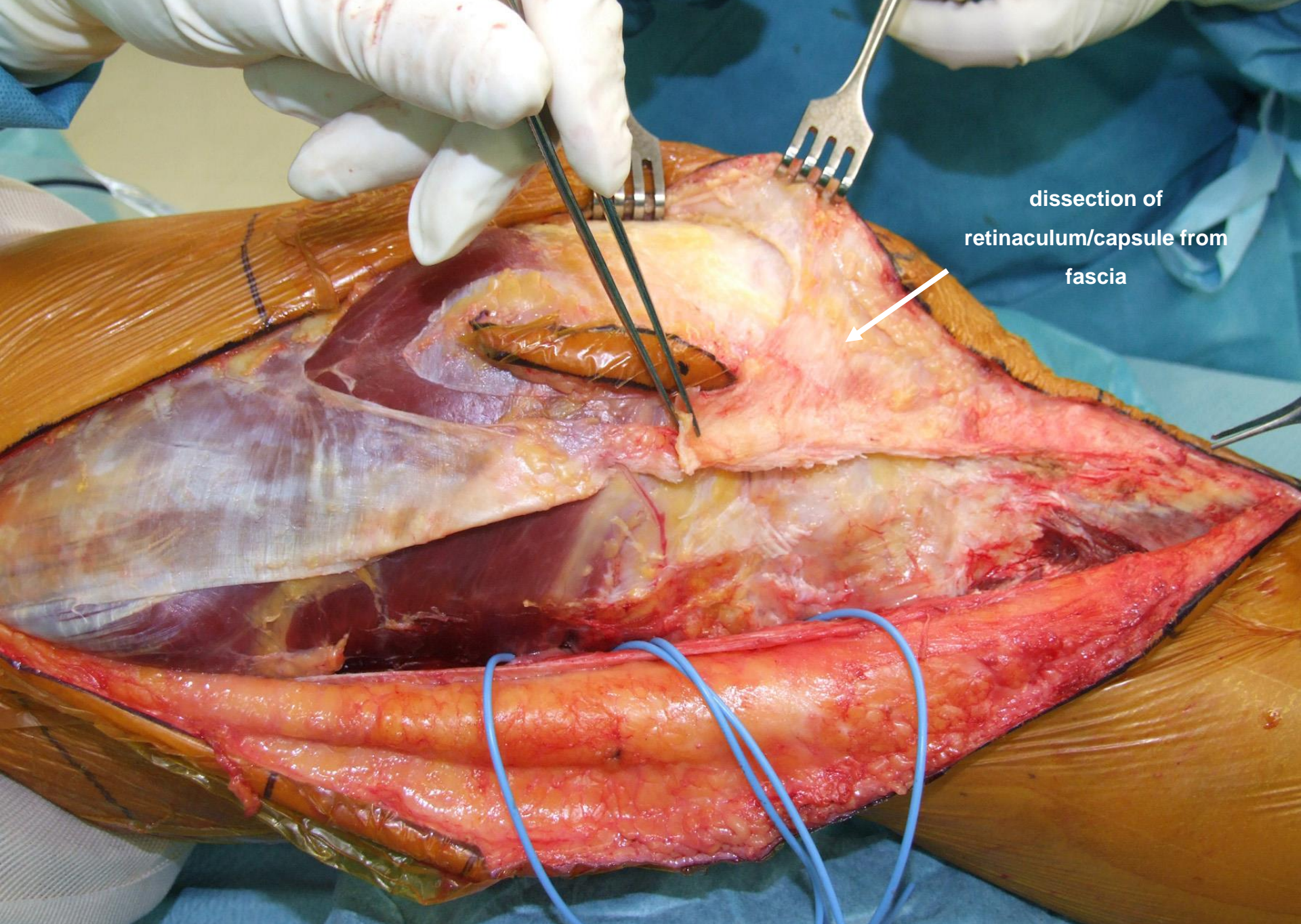
lateral head of gastrocnemius

tibial nerve

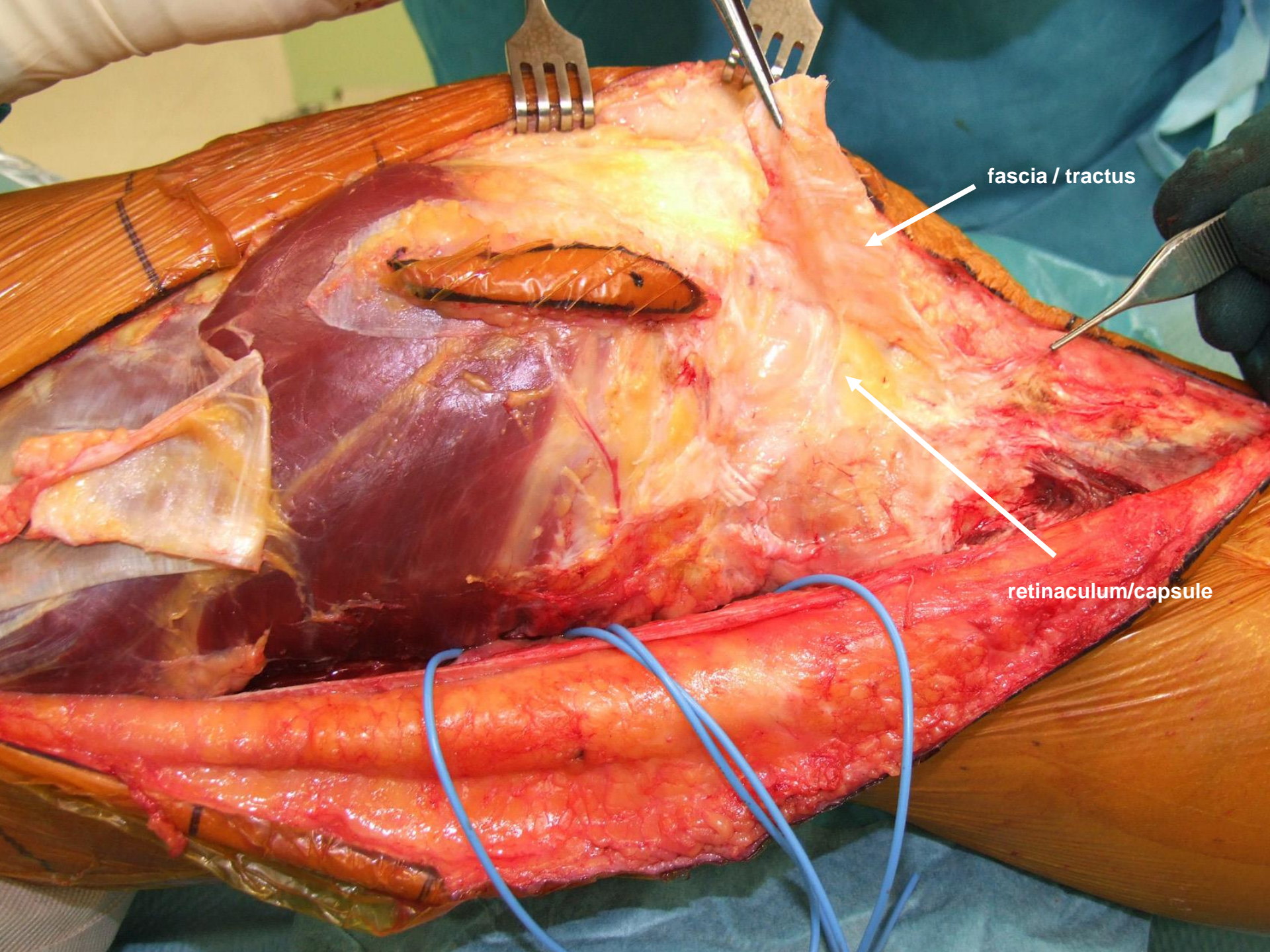
biceps femoris

sciatic nerve

peroneal nerve

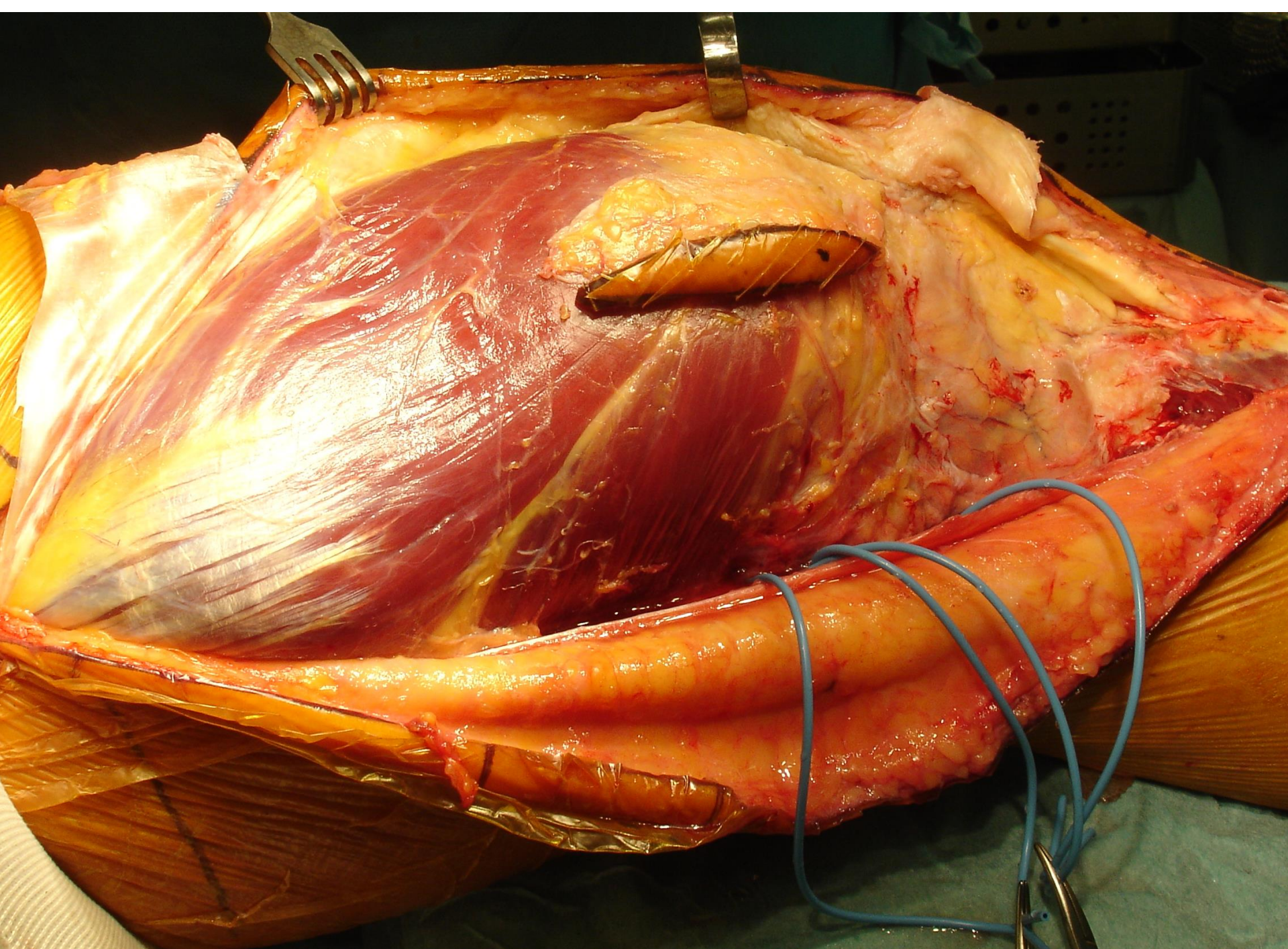


dissection of  
retinaculum/capsule from  
fascia

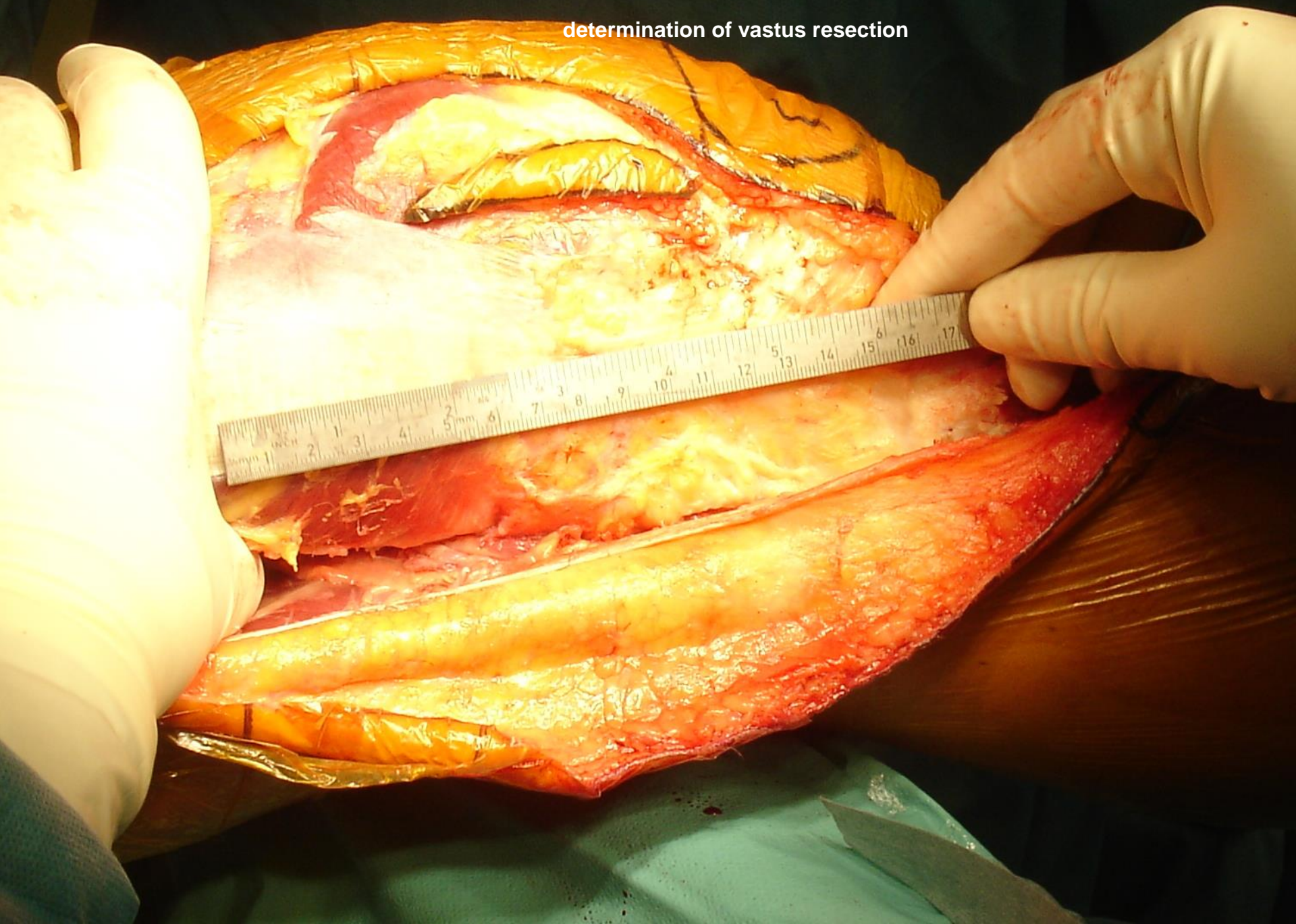


fascia / tractus

retinaculum/capsule

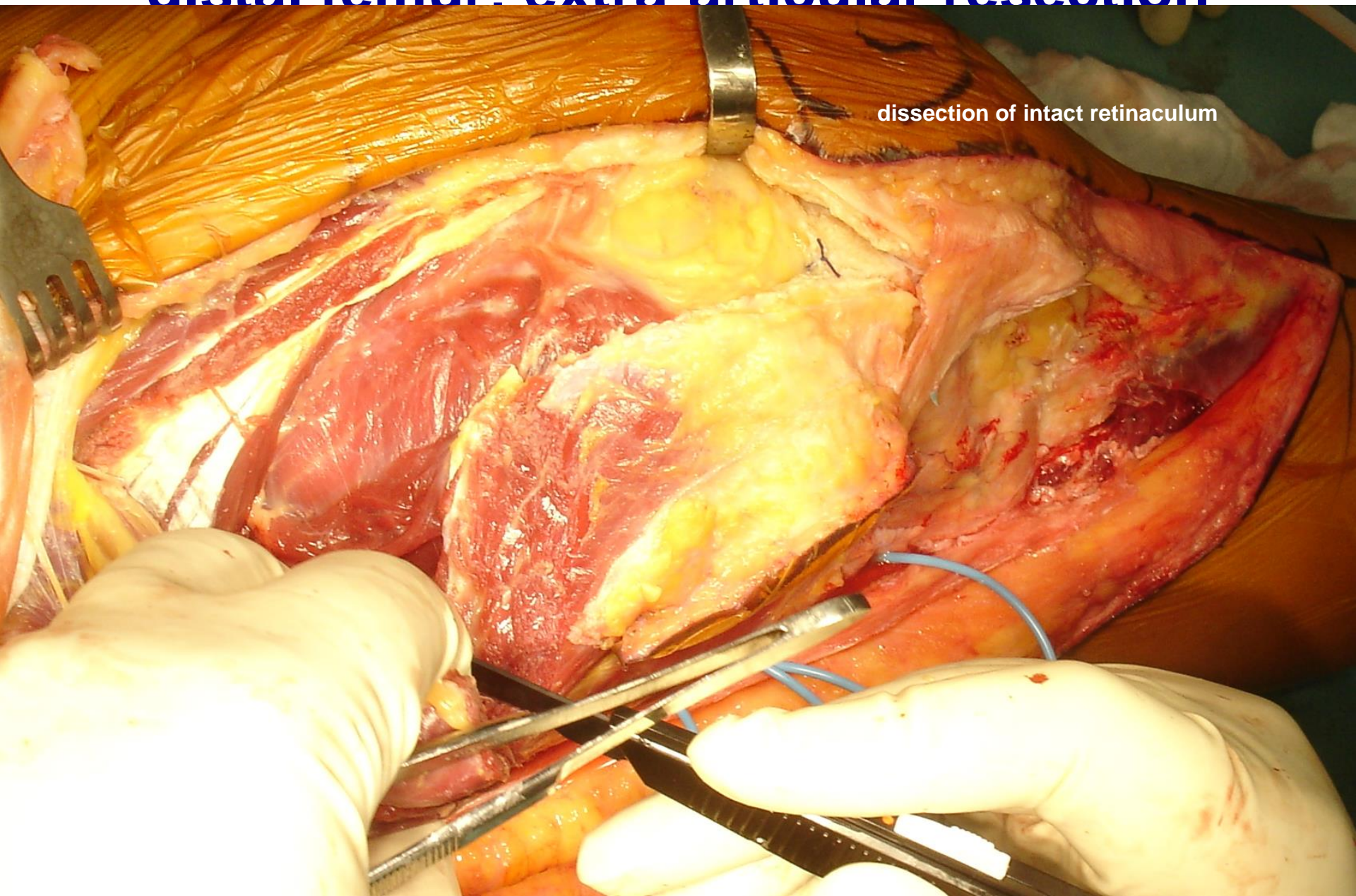


determination of vastus resection

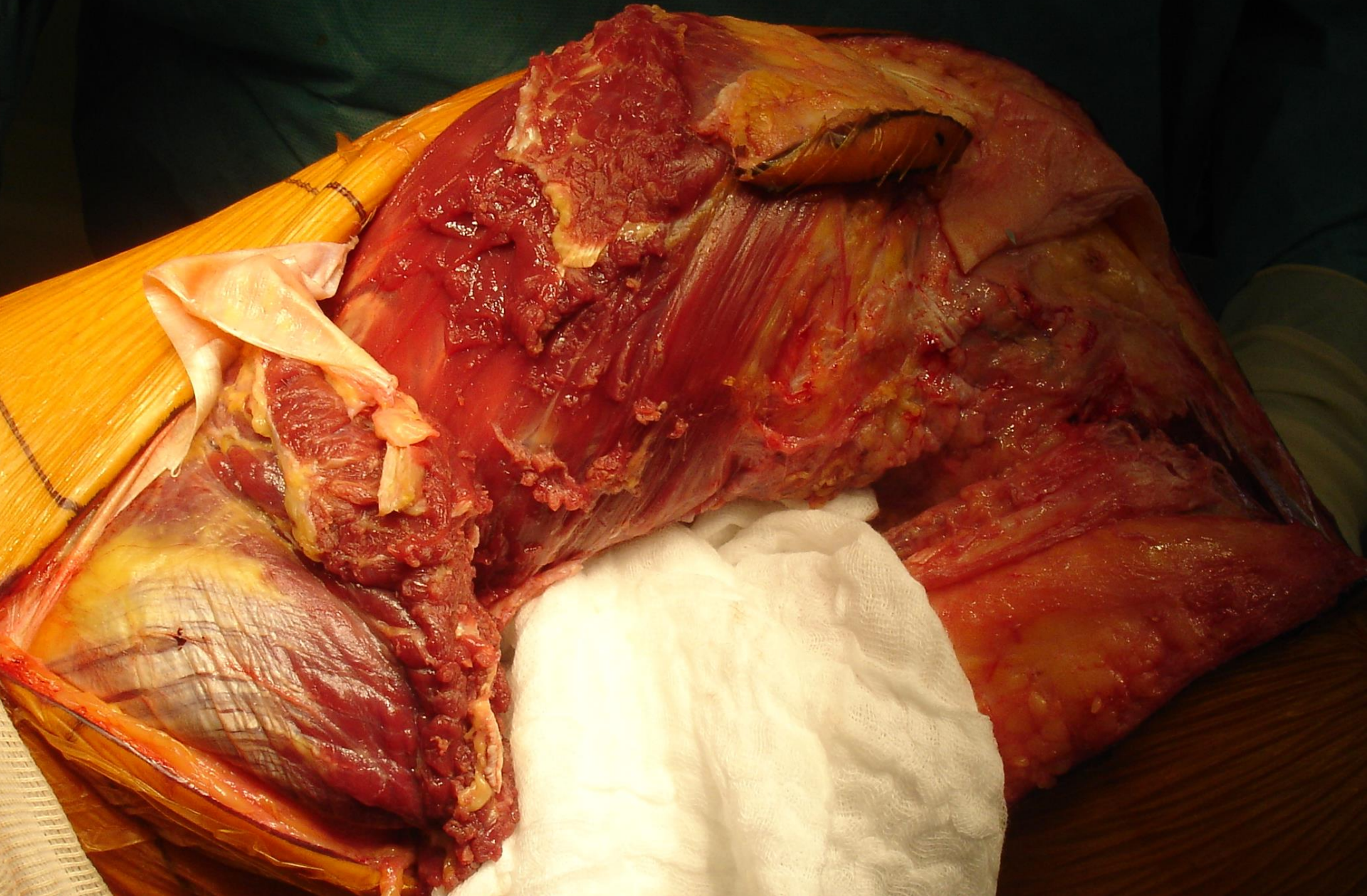

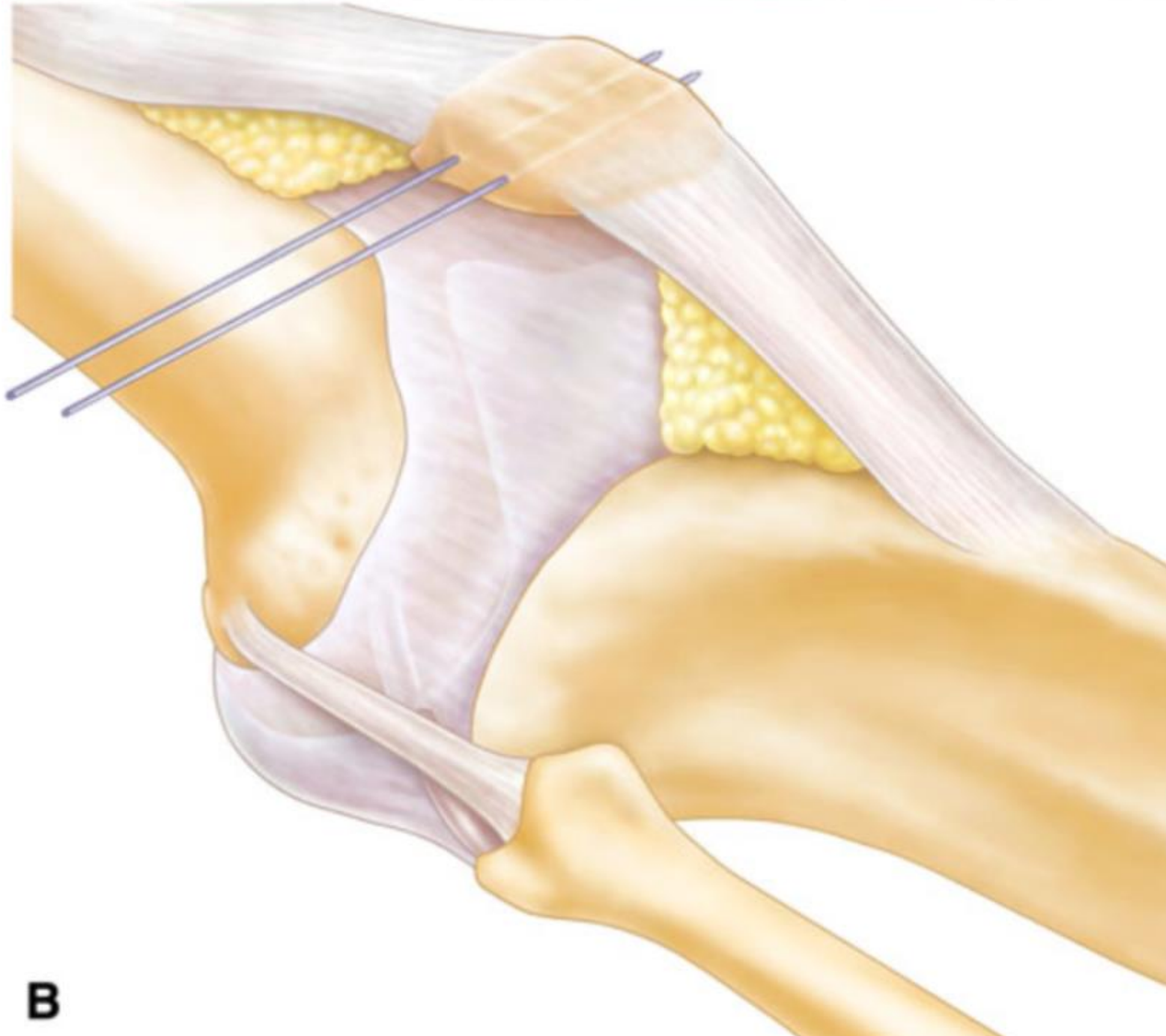


# distal femur: extra-articular resection



dissection of intact retinaculum

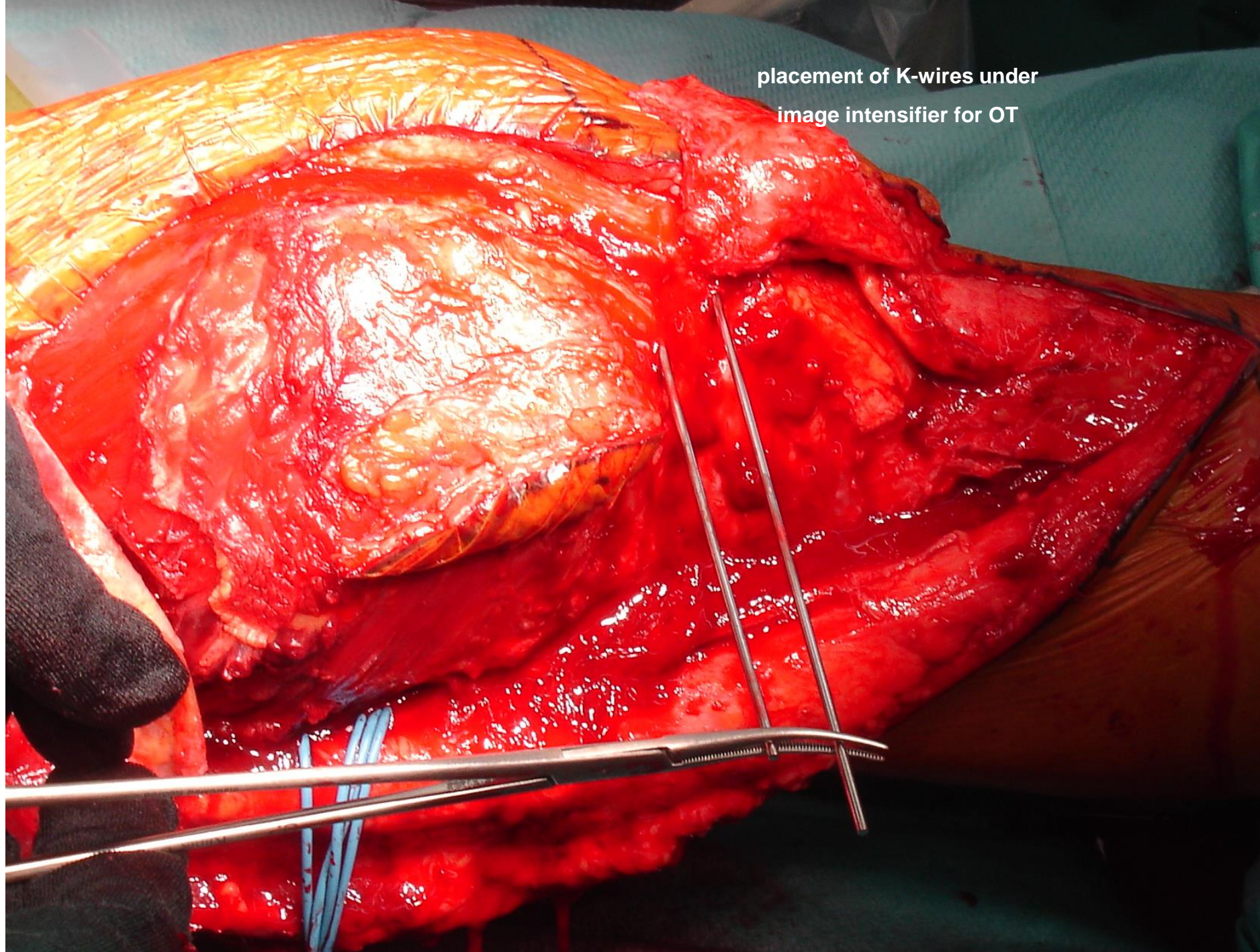




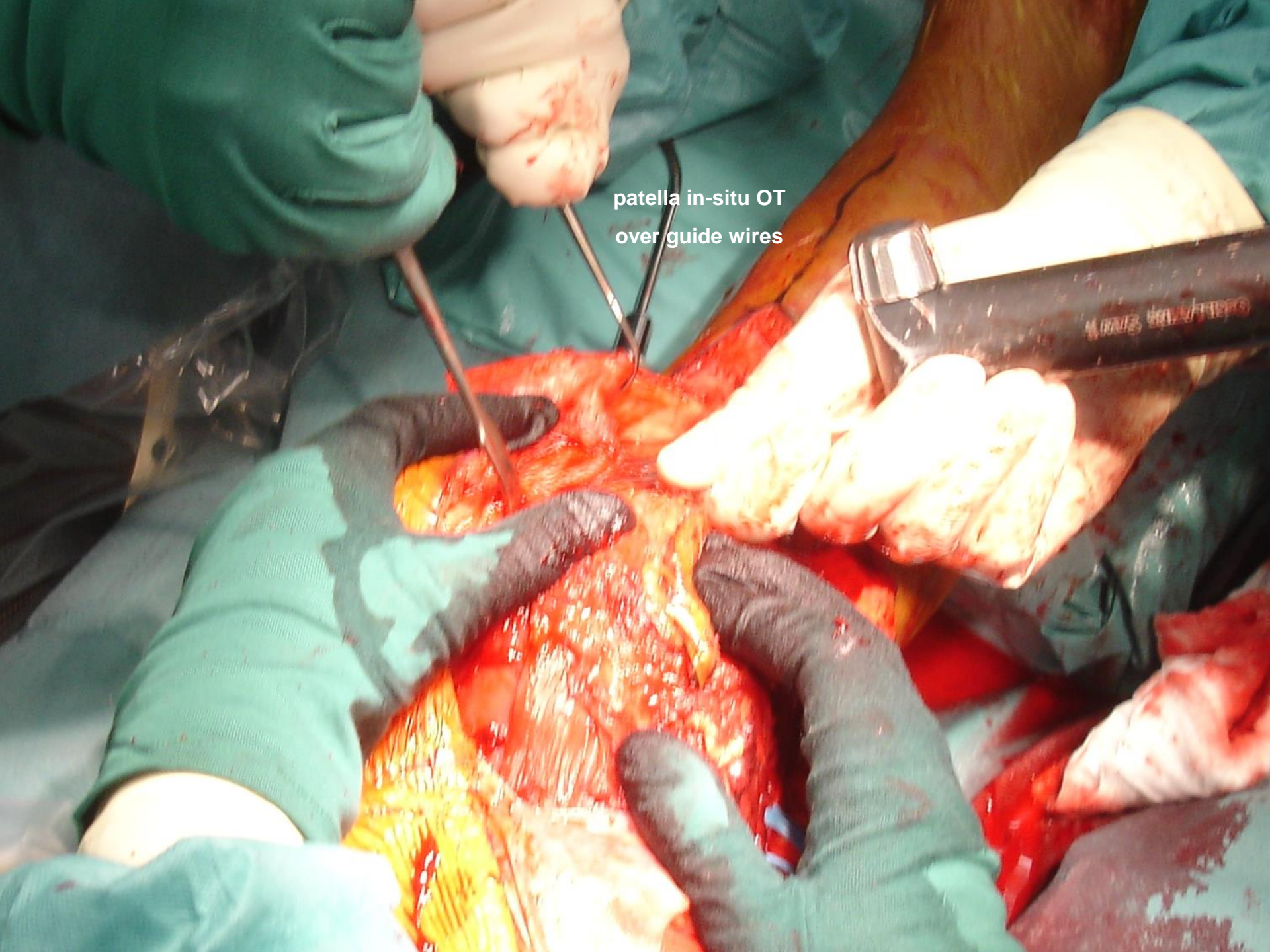**B**

urgery

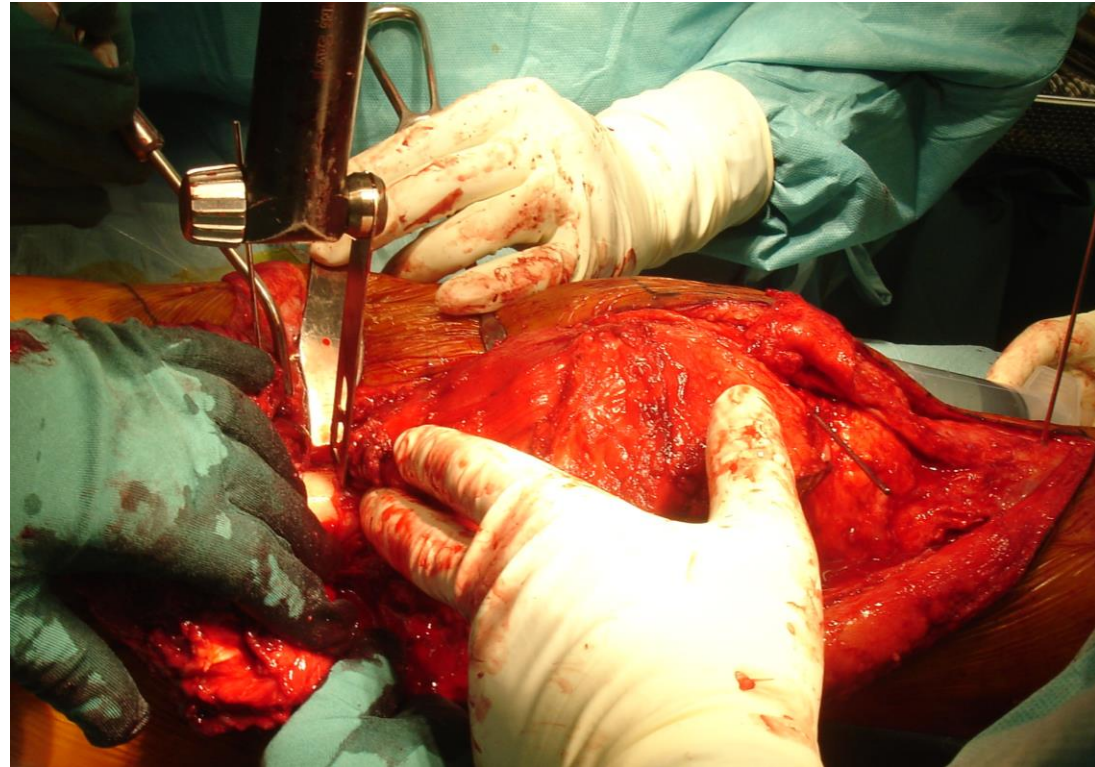
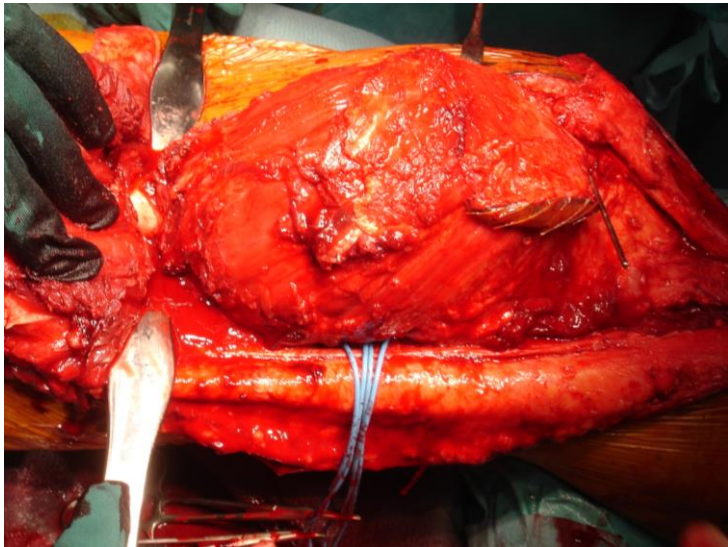
placement of K-wires under  
image intensifier for OT



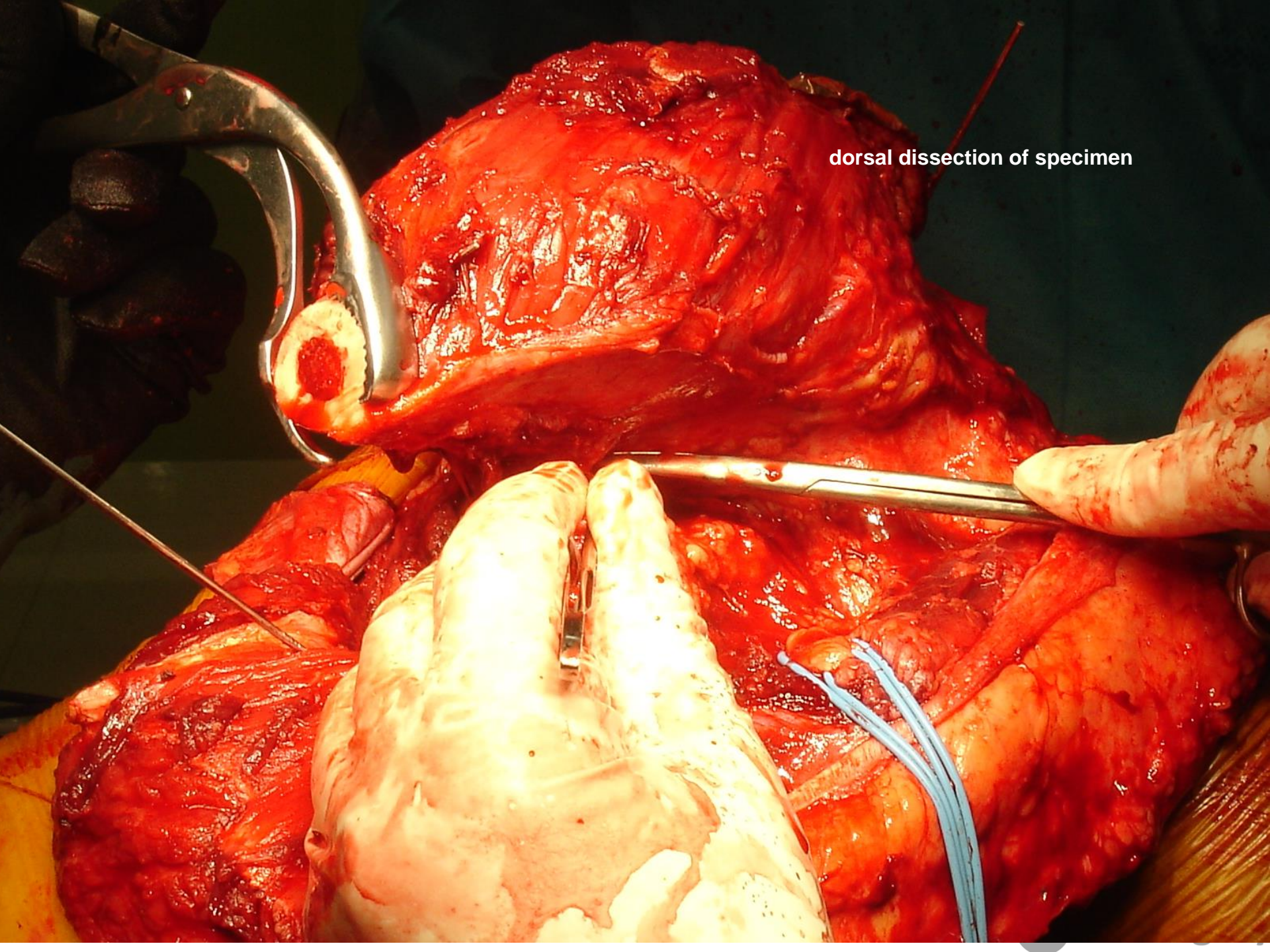
patella in-situ OT  
over guide wires

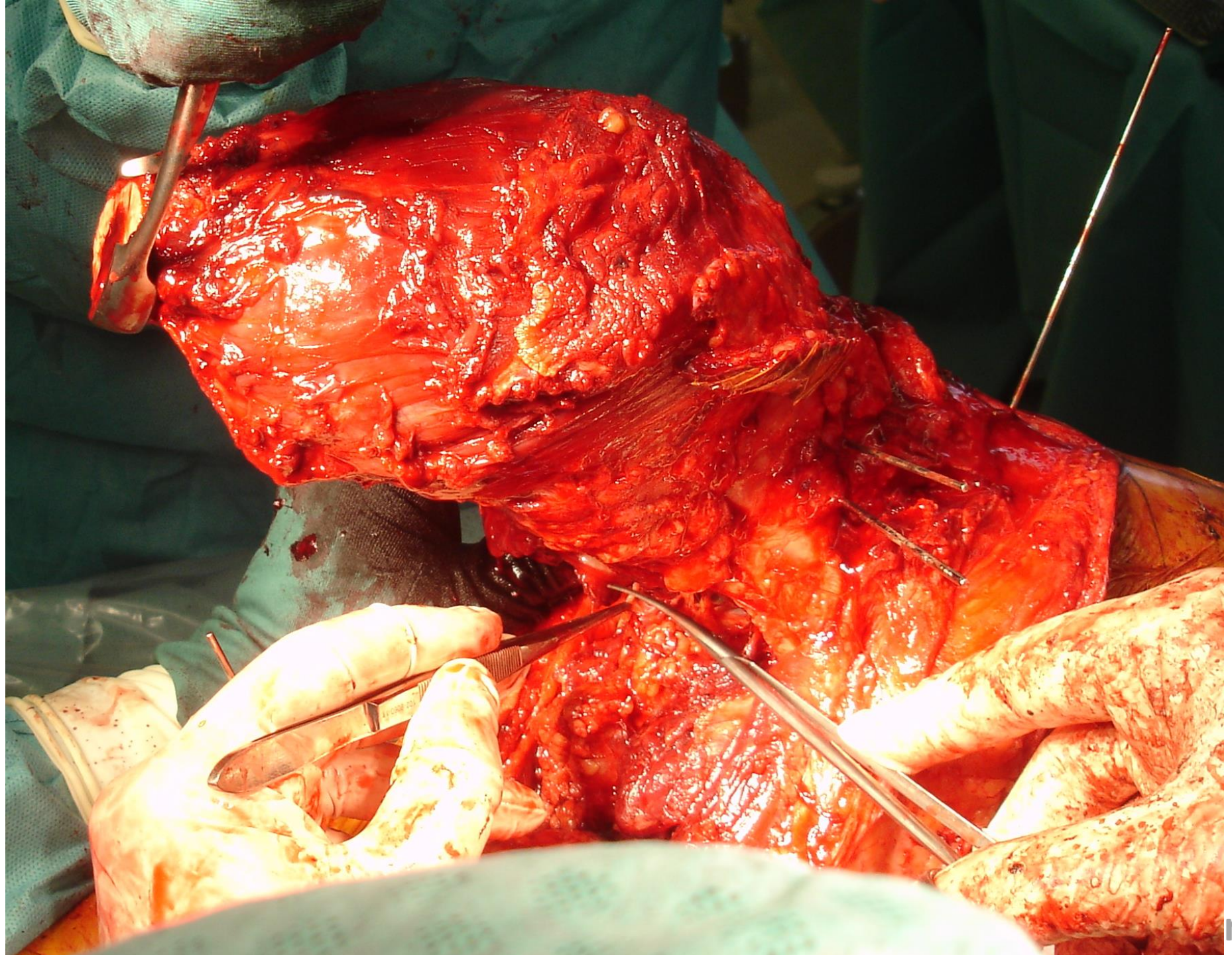


# distal femur; extra-articular resection

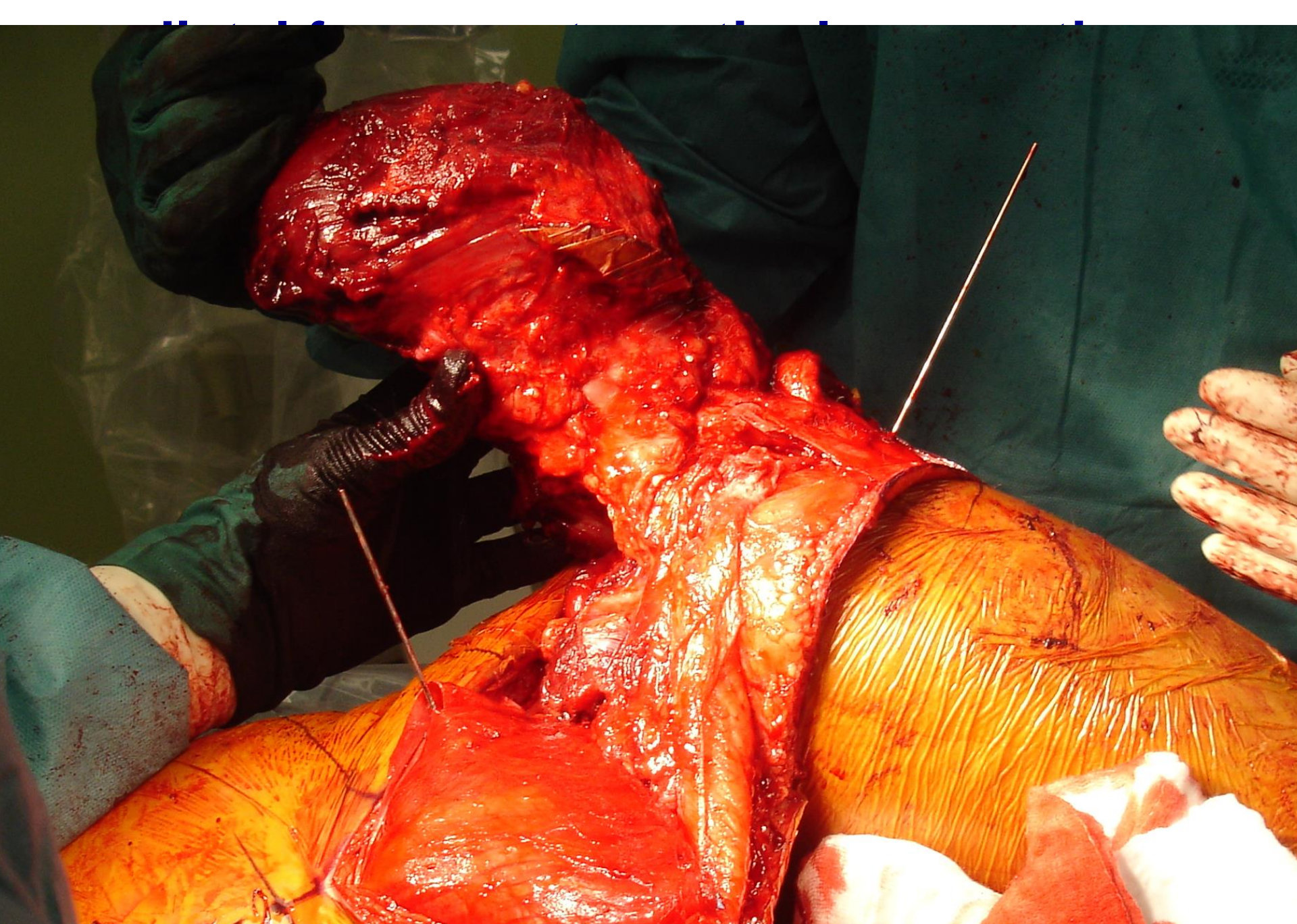


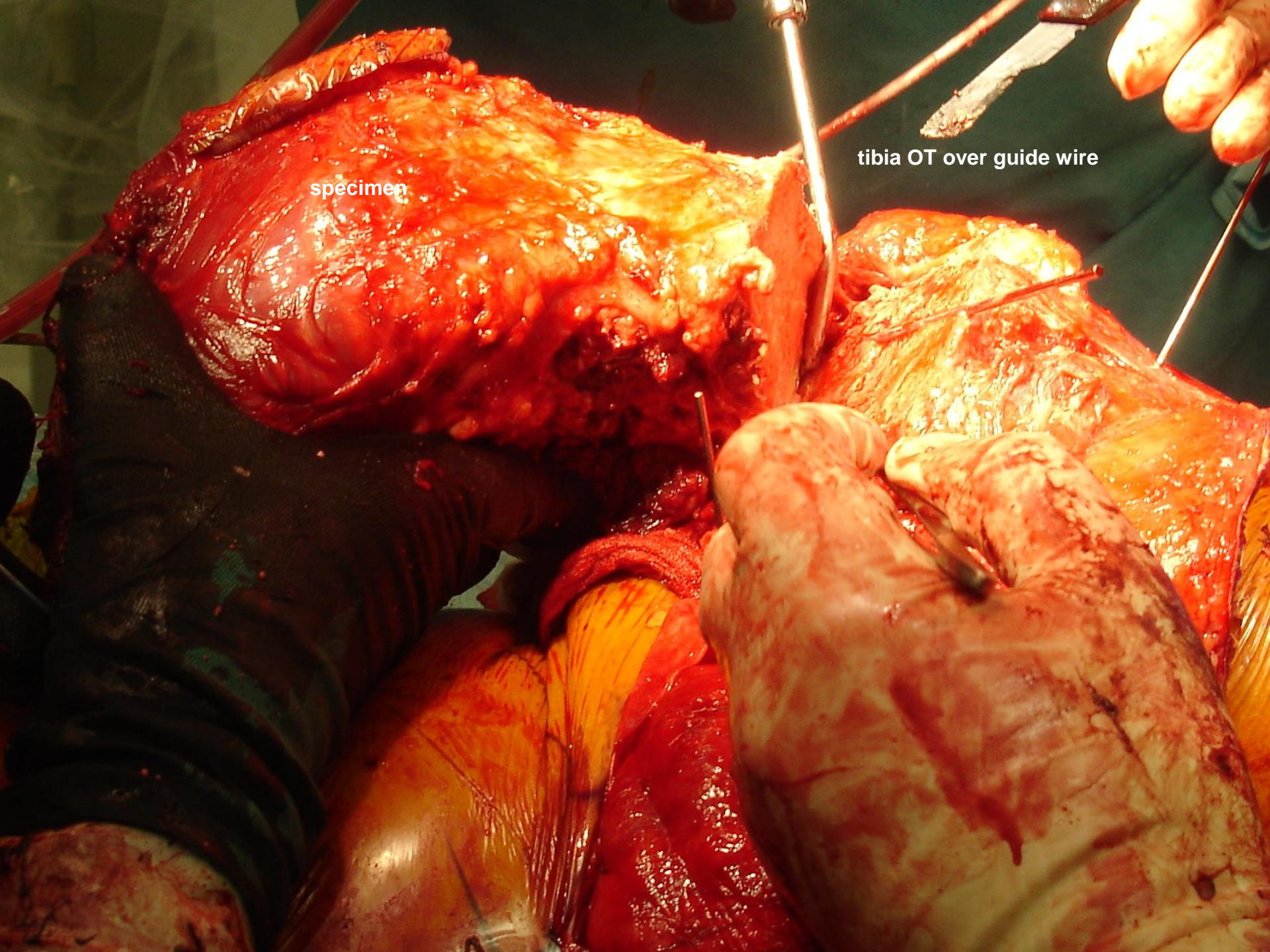
dorsal dissection of specimen





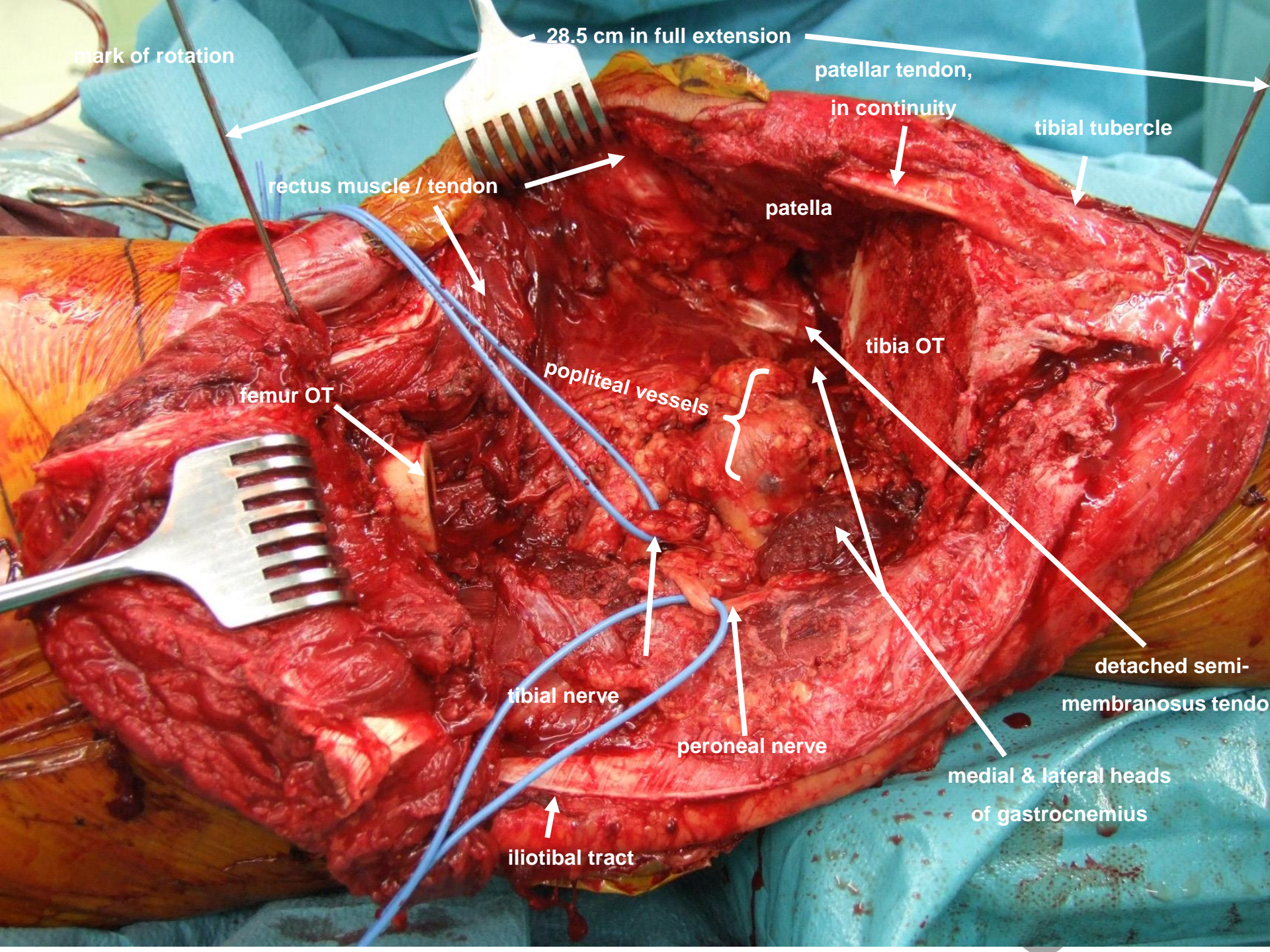






specimen

tibia OT over guide wire



mark of rotation

28.5 cm in full extension

patellar tendon,  
in continuity

tibial tubercle

rectus muscle / tendon

patella

tibia OT

femur OT

popliteal vessels

detached semi-  
membranous tendo

tibial nerve

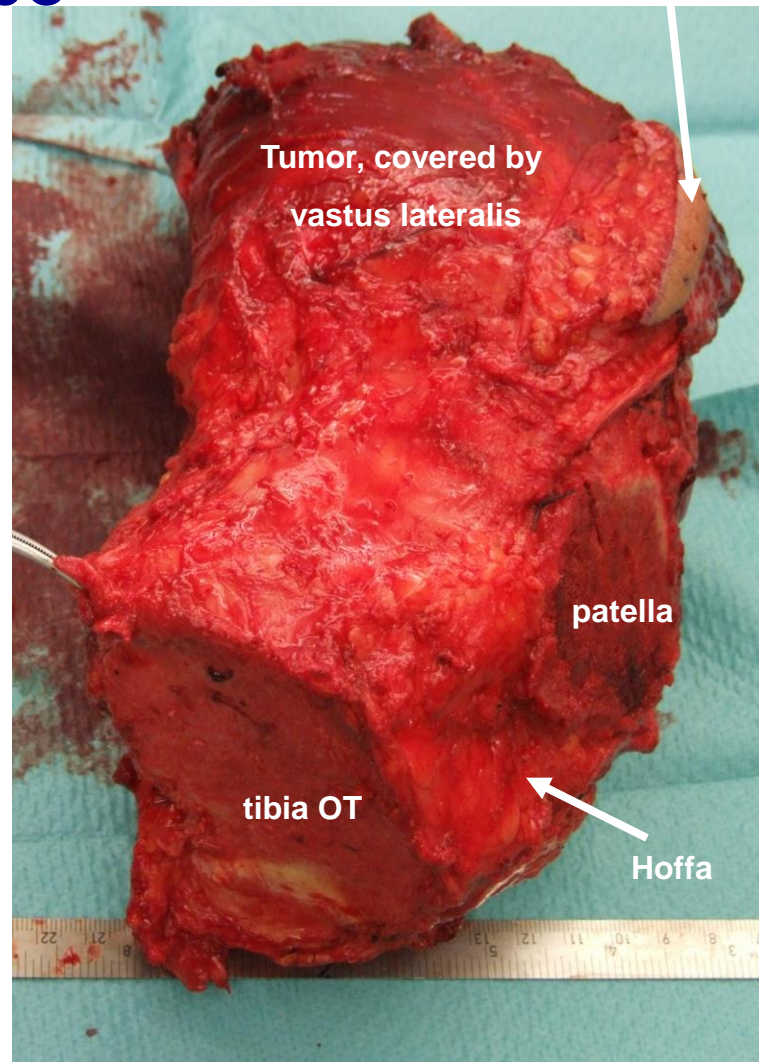
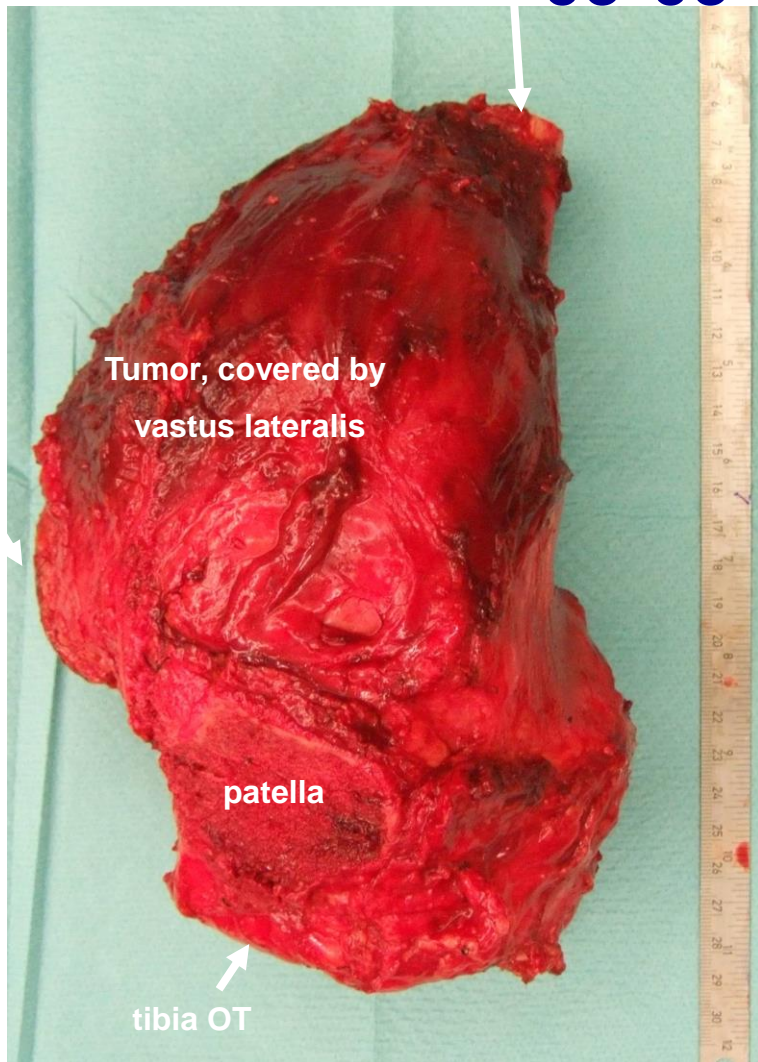
peroneal nerve

medial & lateral heads  
of gastrocnemius

iliotibial tract

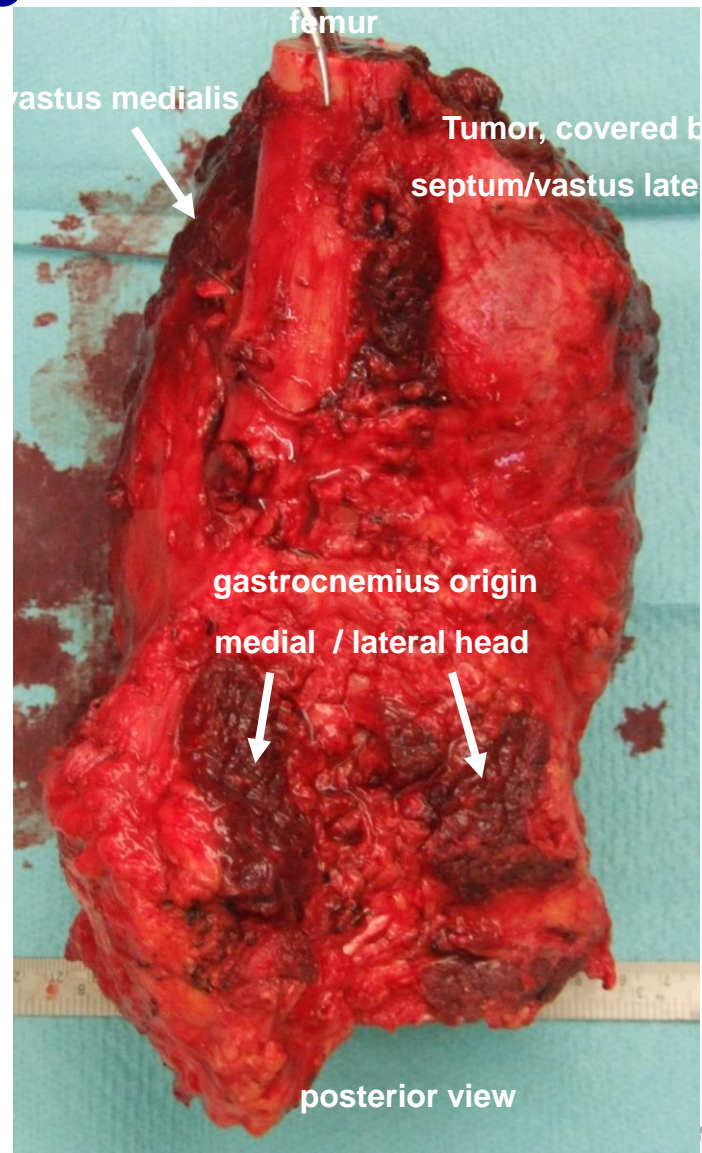
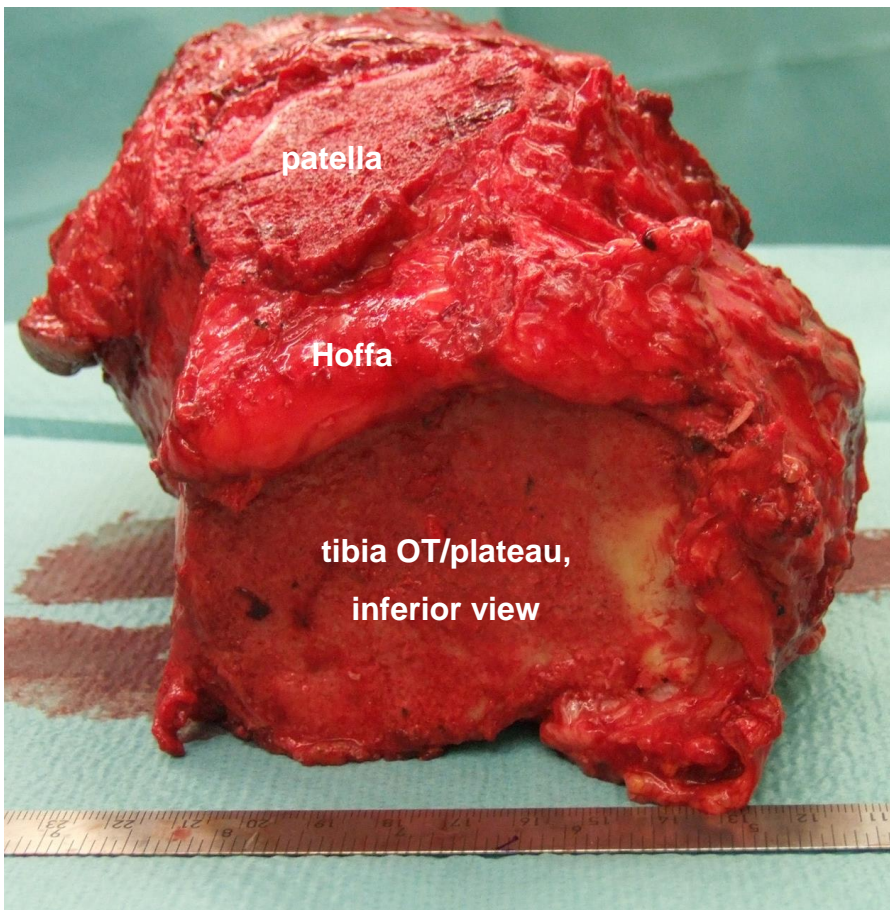
# distal femur; extra-articular resection

09-09-2008

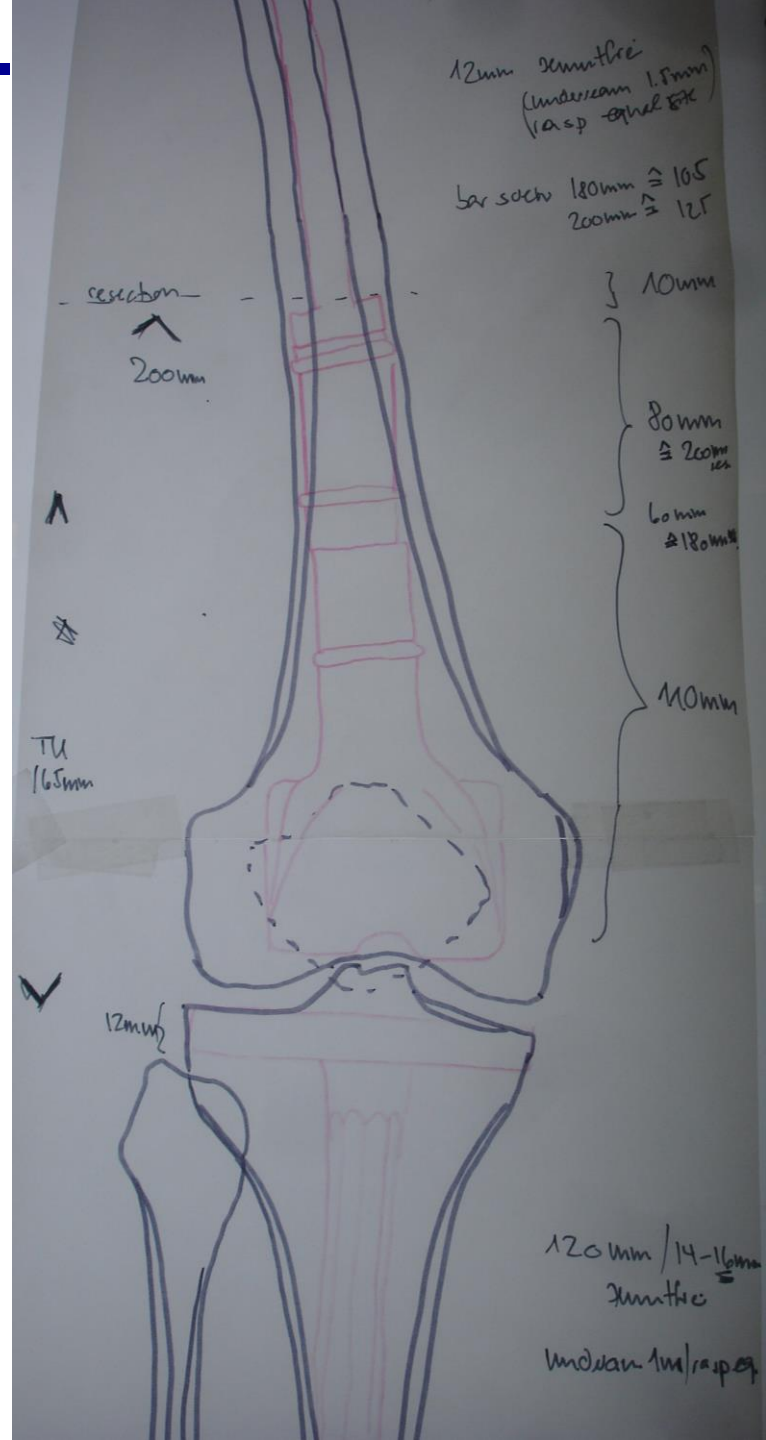


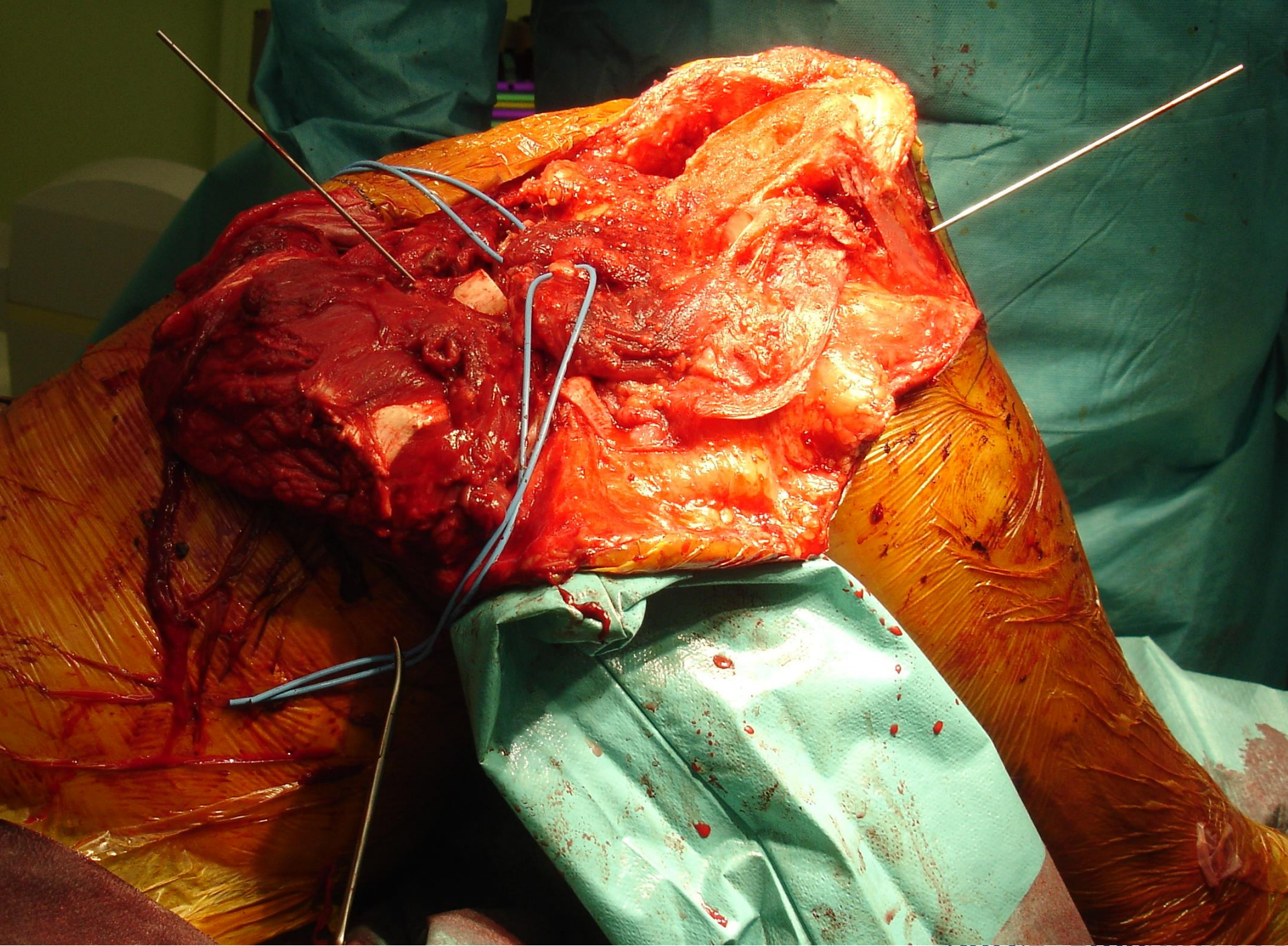
# distal femur; extra-articular resection

09-09-2008

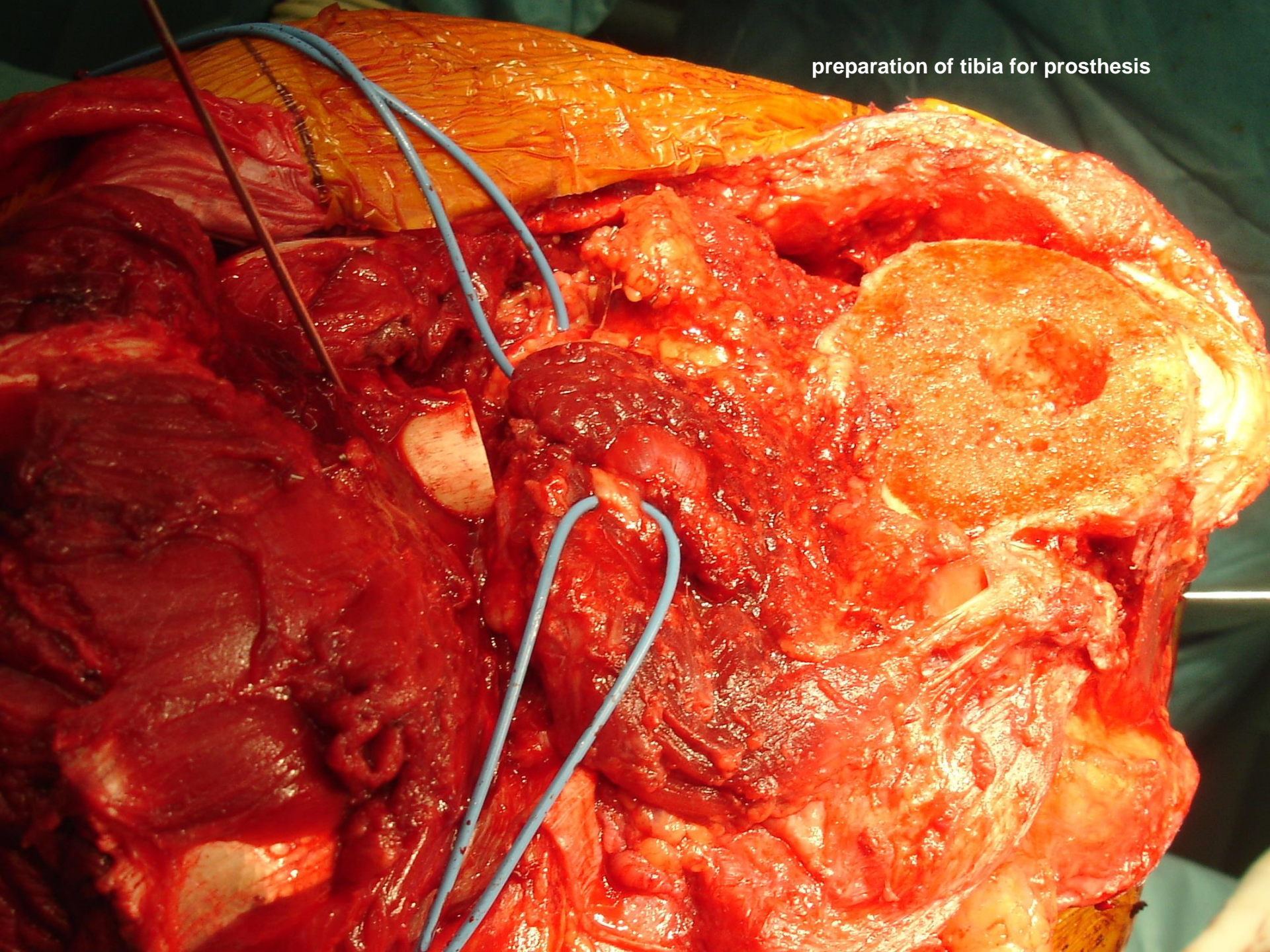


# distal femur; extra-



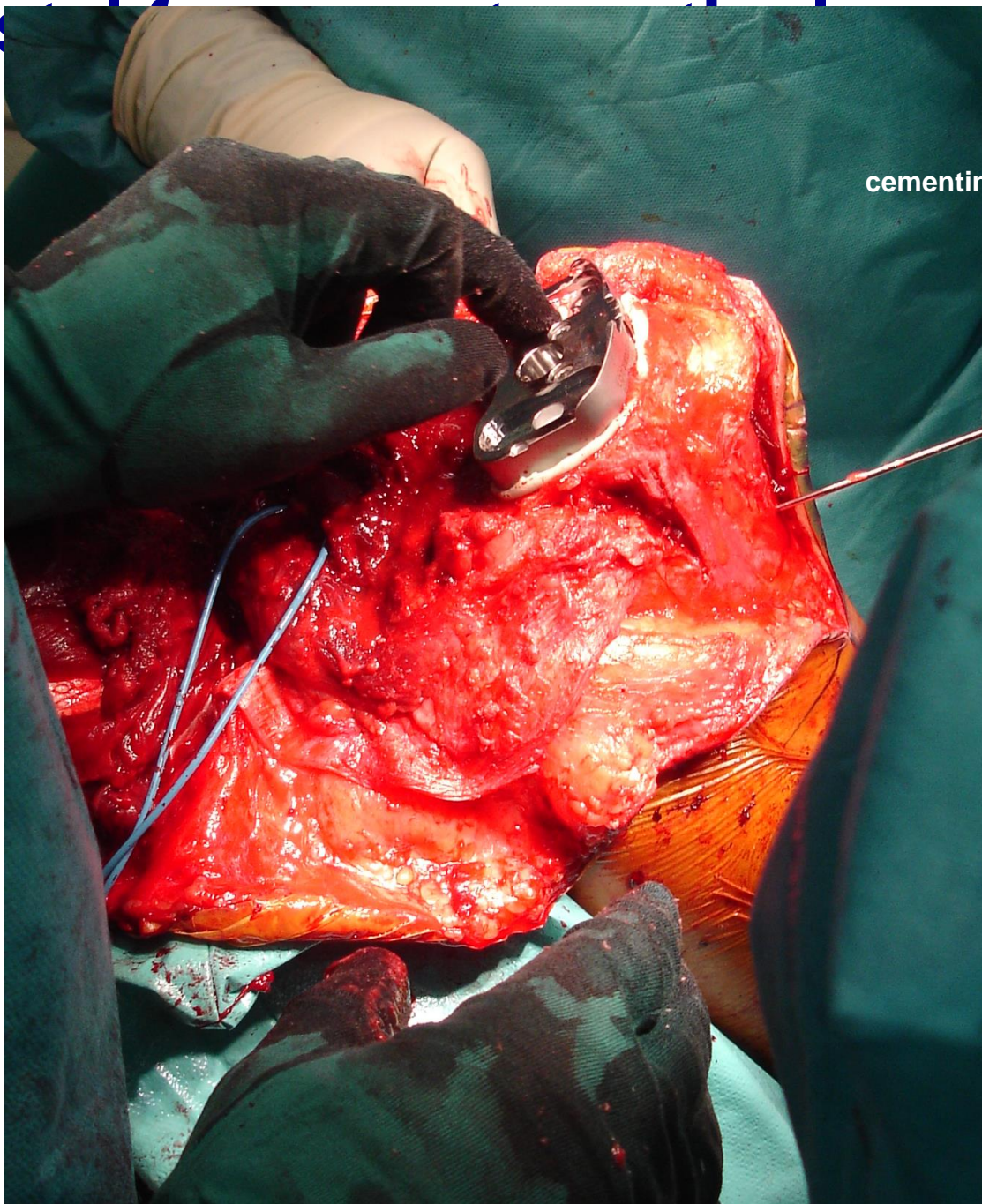


preparation of tibia for prosthesis

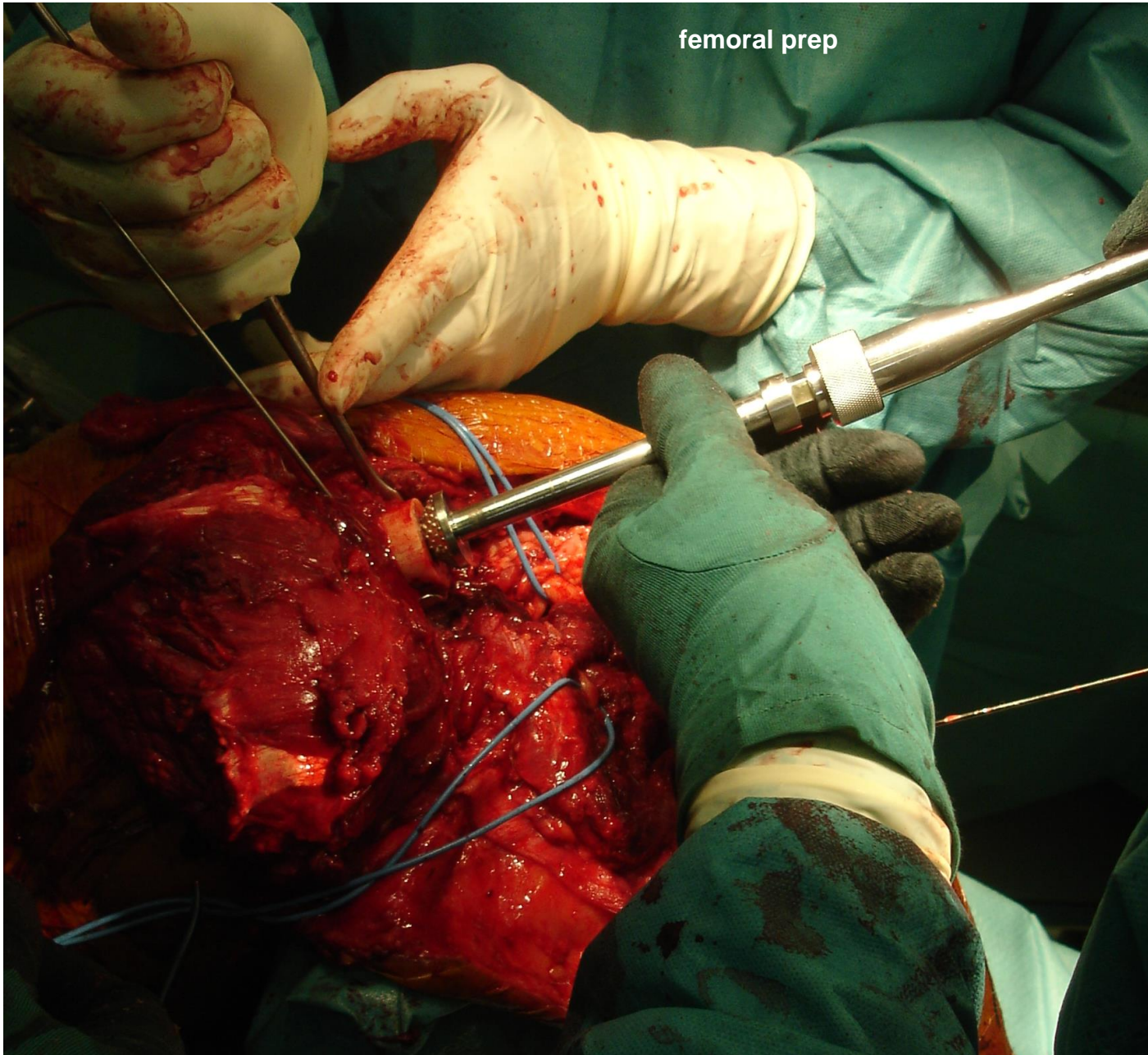


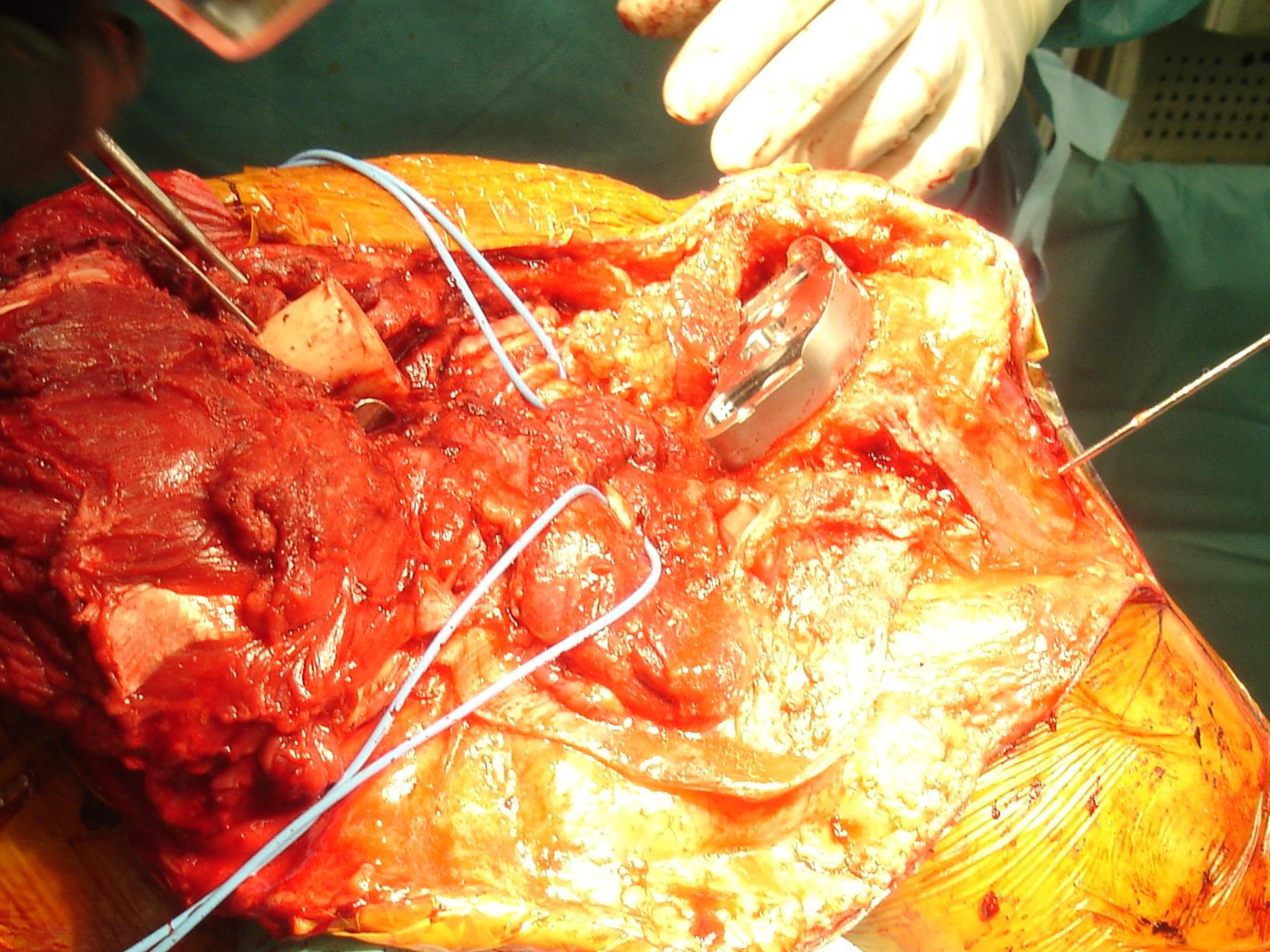


# distal femoral resection

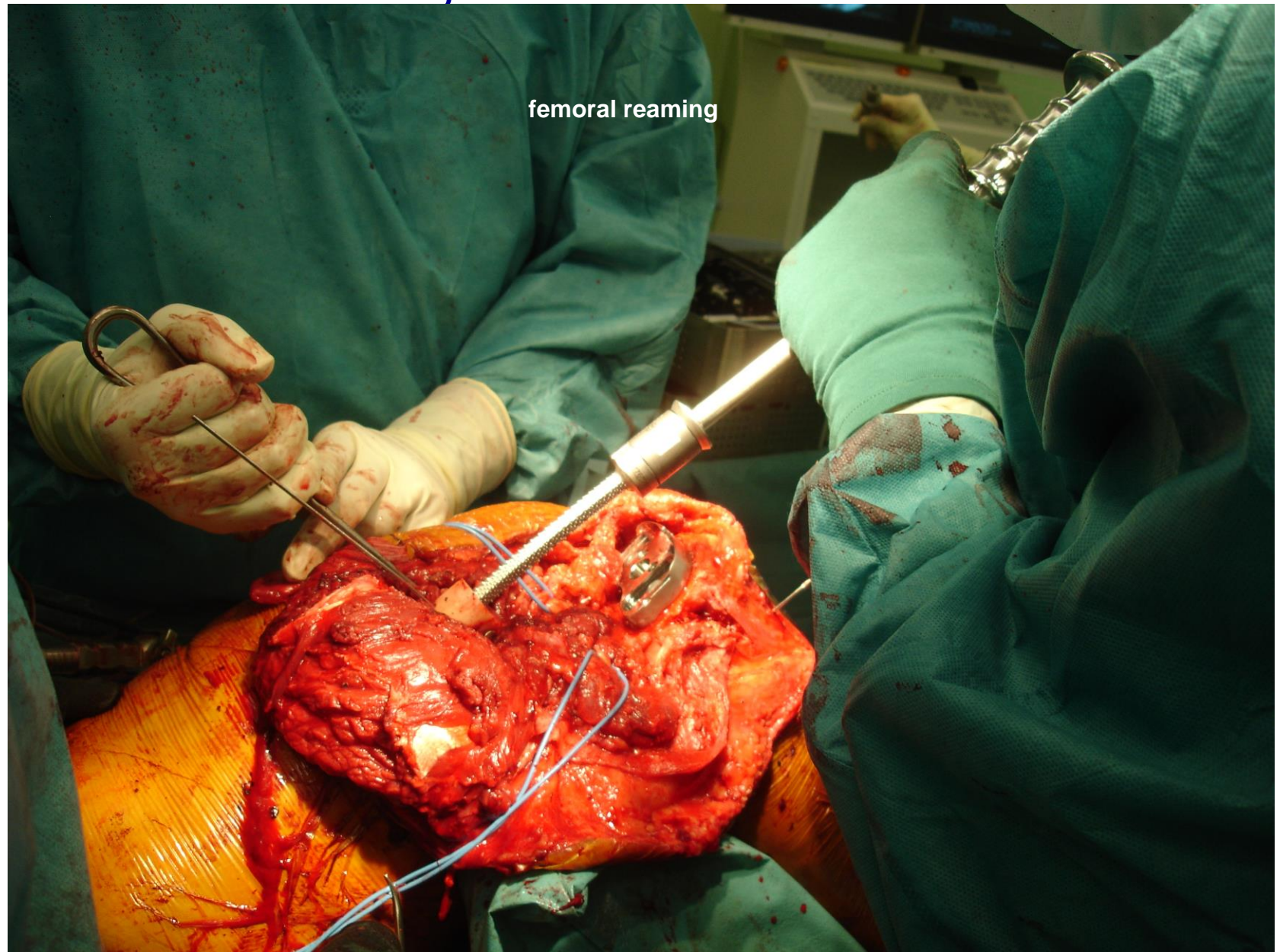

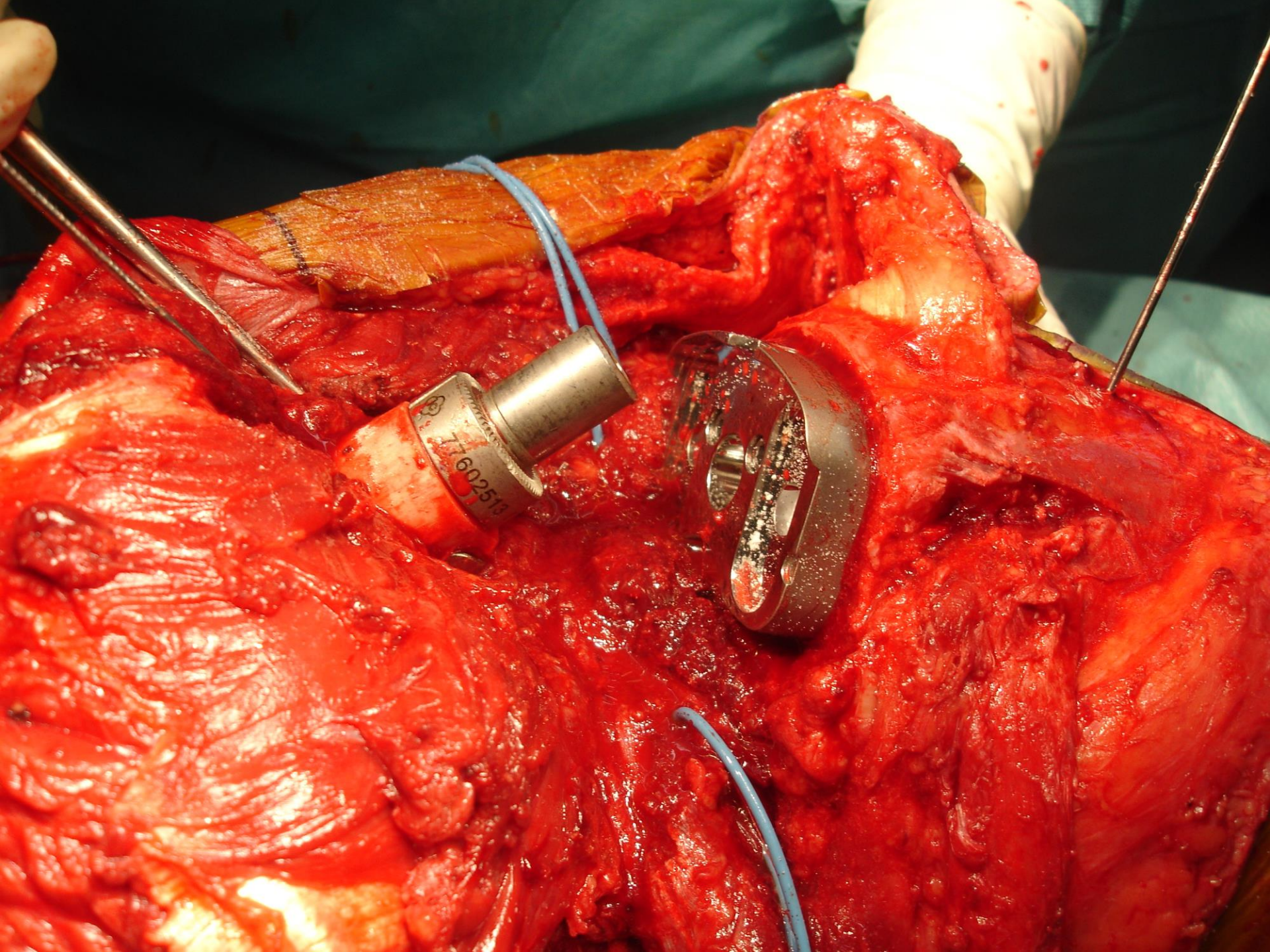
# distal femur; extra-articular resection





# distal femur; extra-articular resection

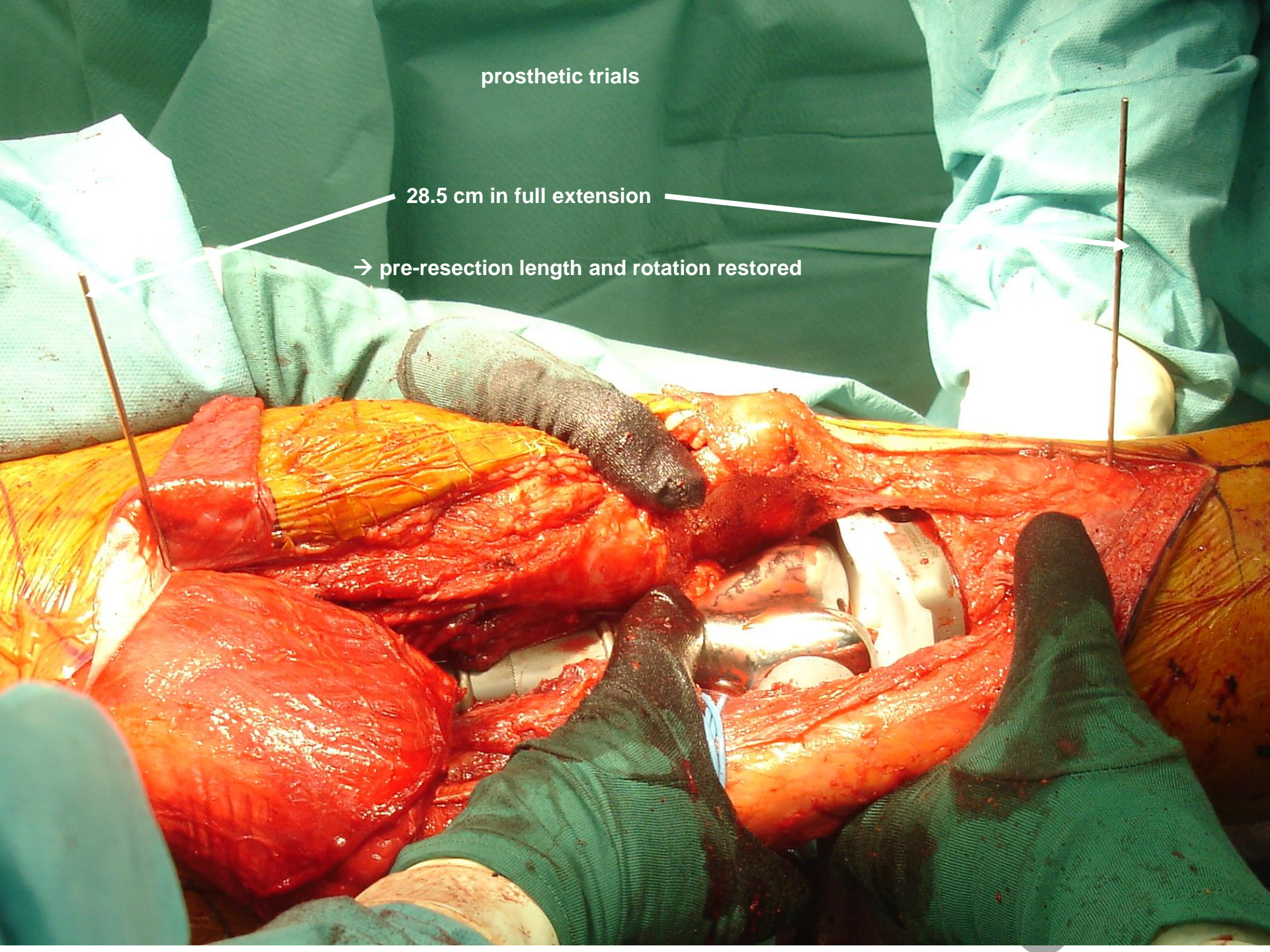




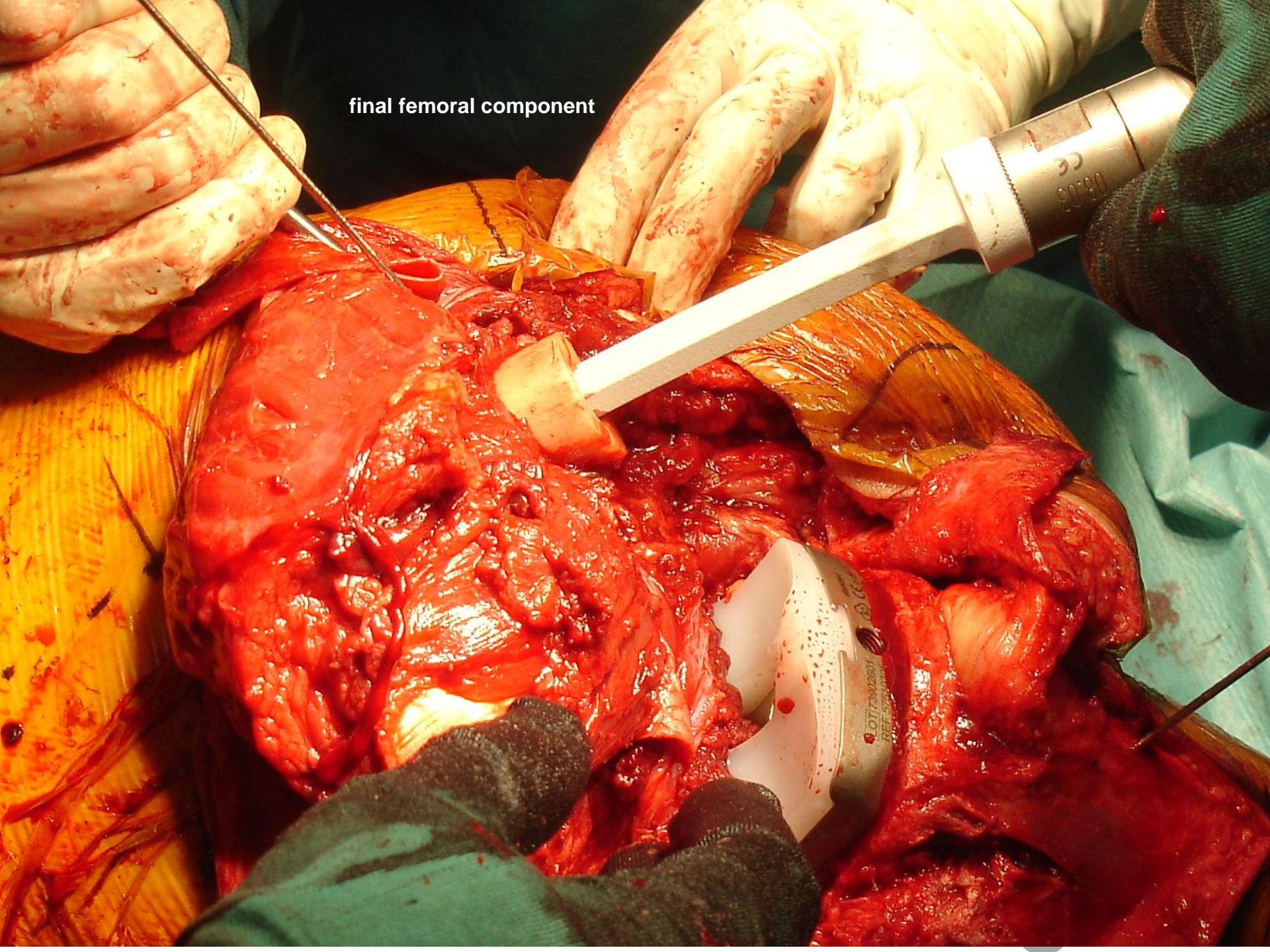
prosthetic trials

28.5 cm in full extension

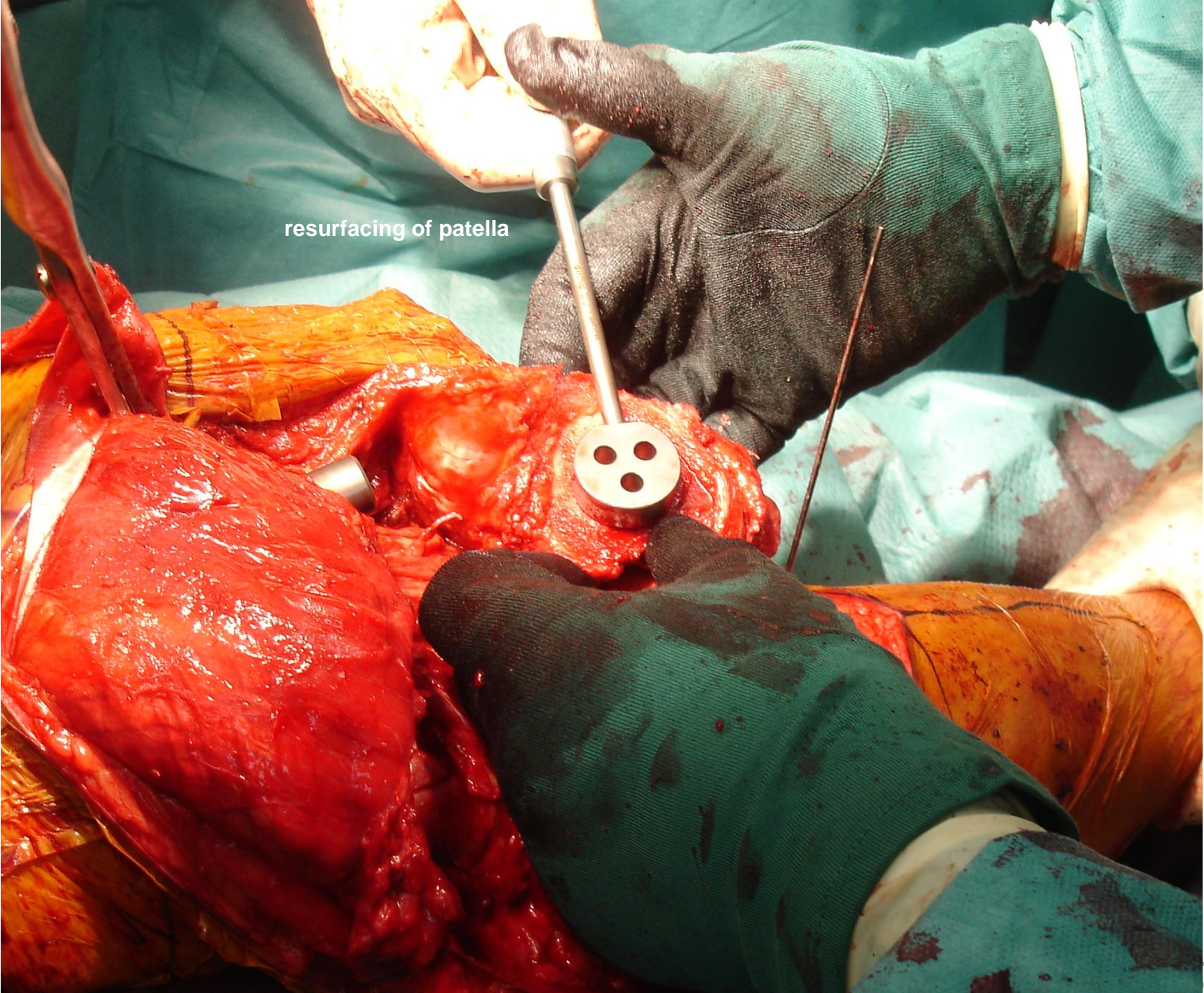
→ pre-resection length and rotation restored



final femoral component

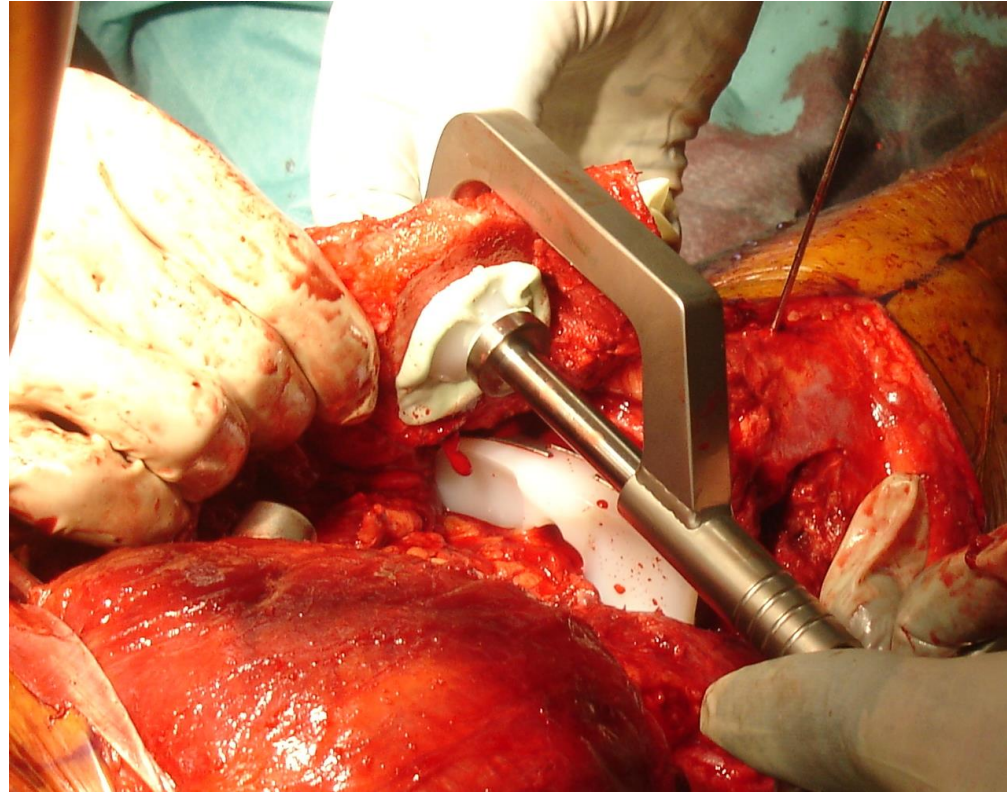
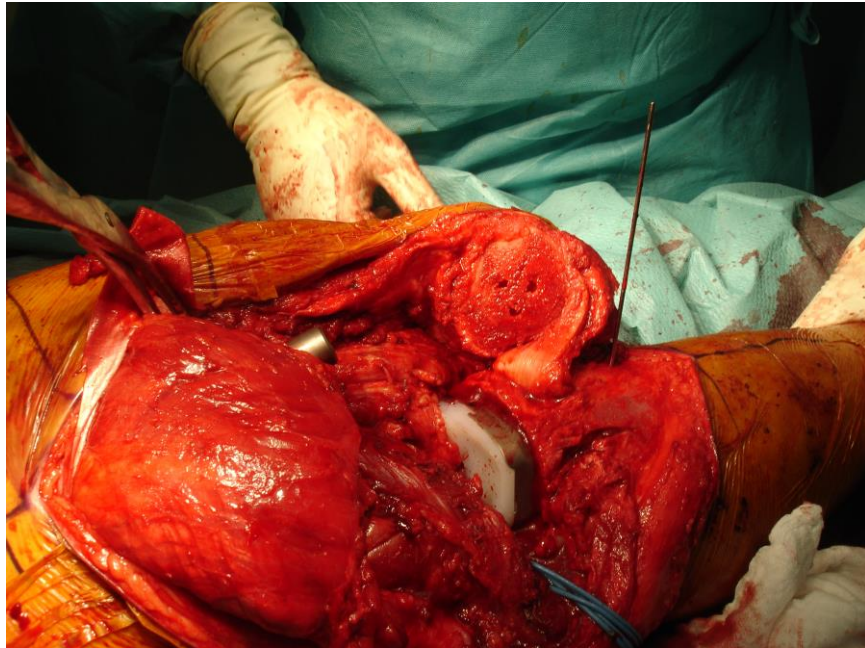


resurfacing of patella



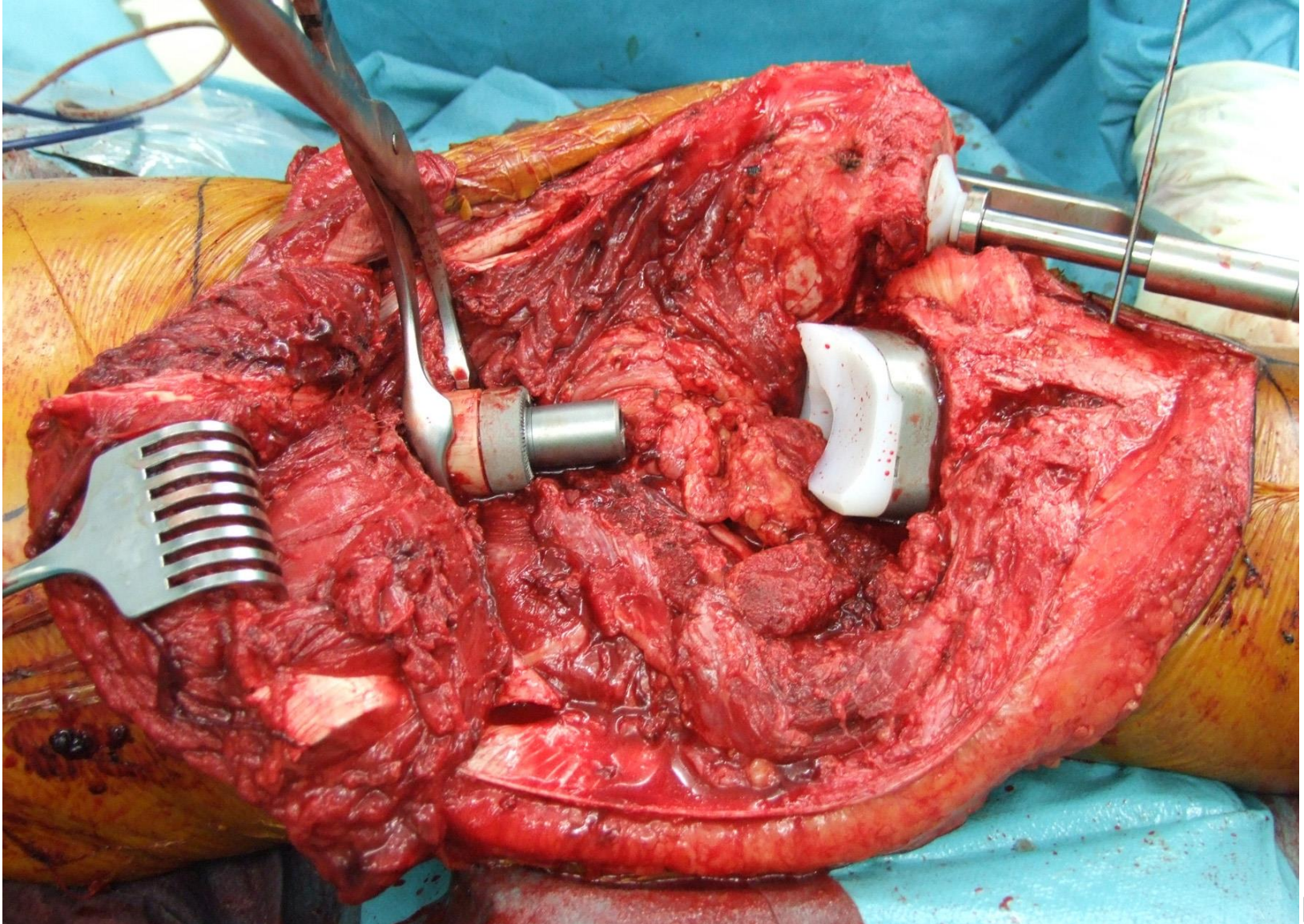


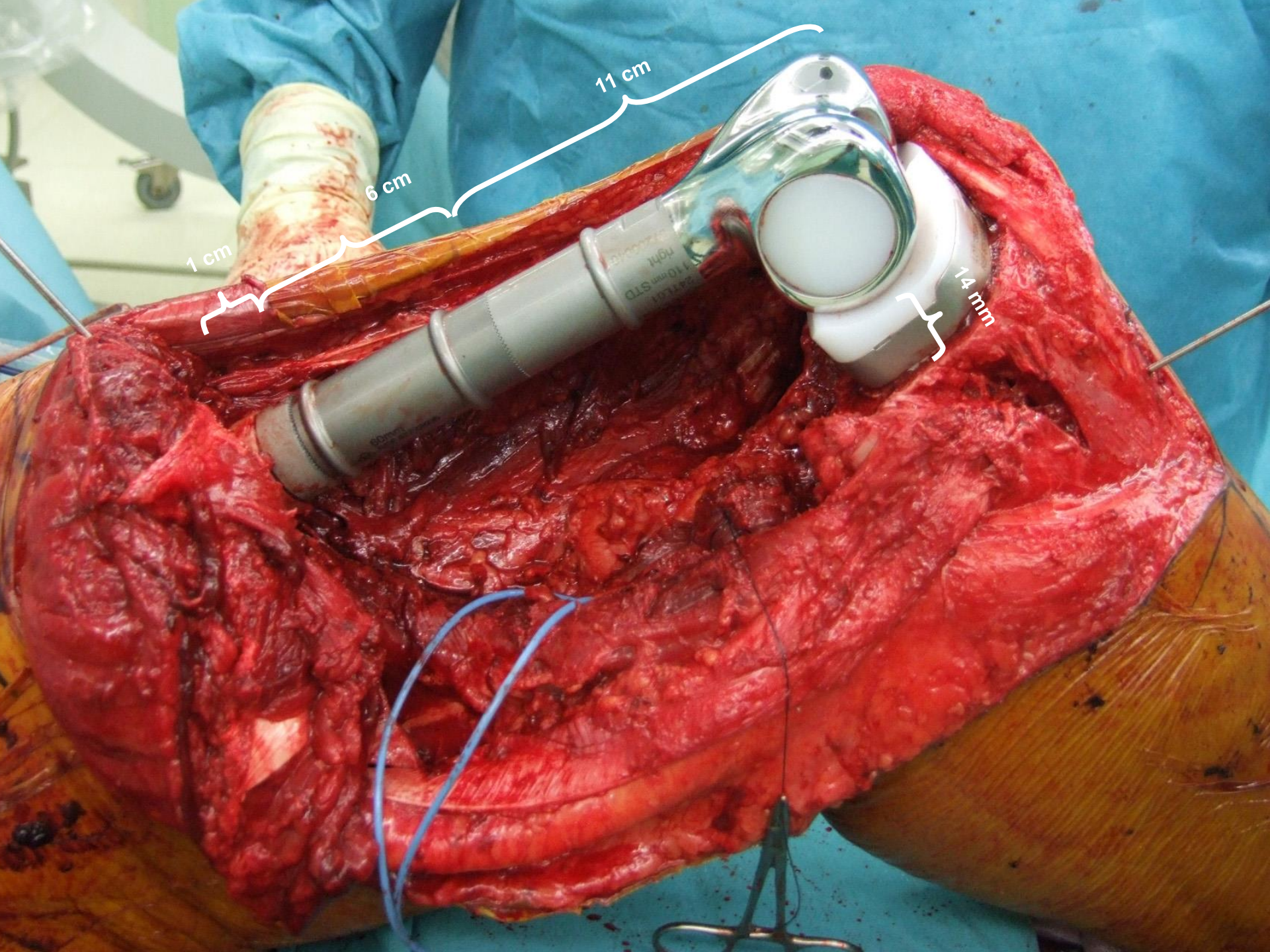
# distal femur; extra-articular resection



# distal femur; extra-articular resection

09-09-2008





11 cm

6 cm

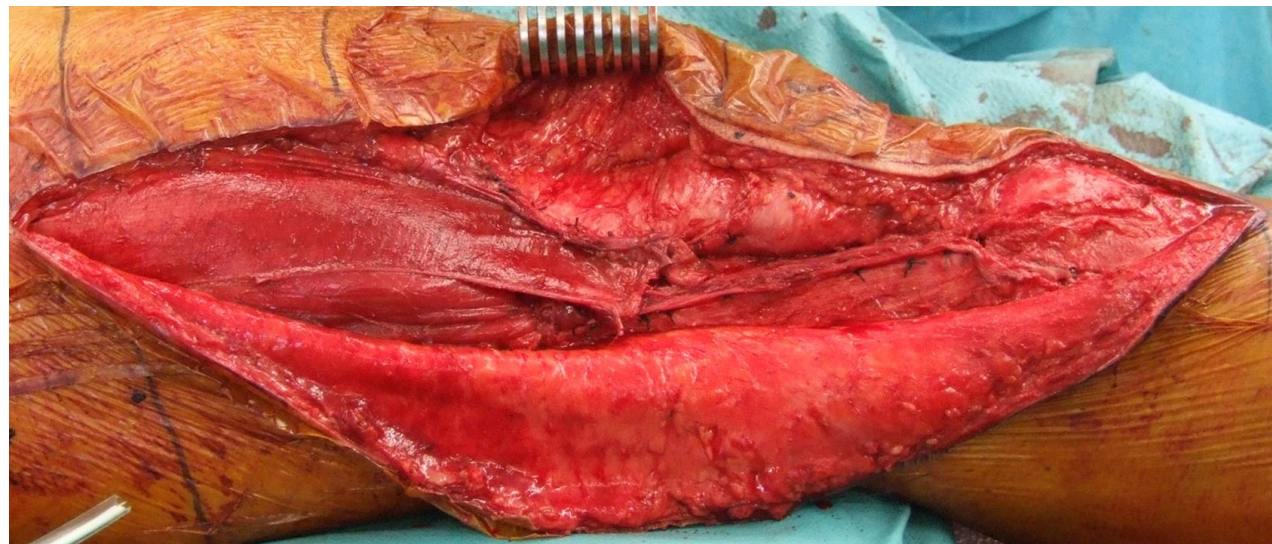
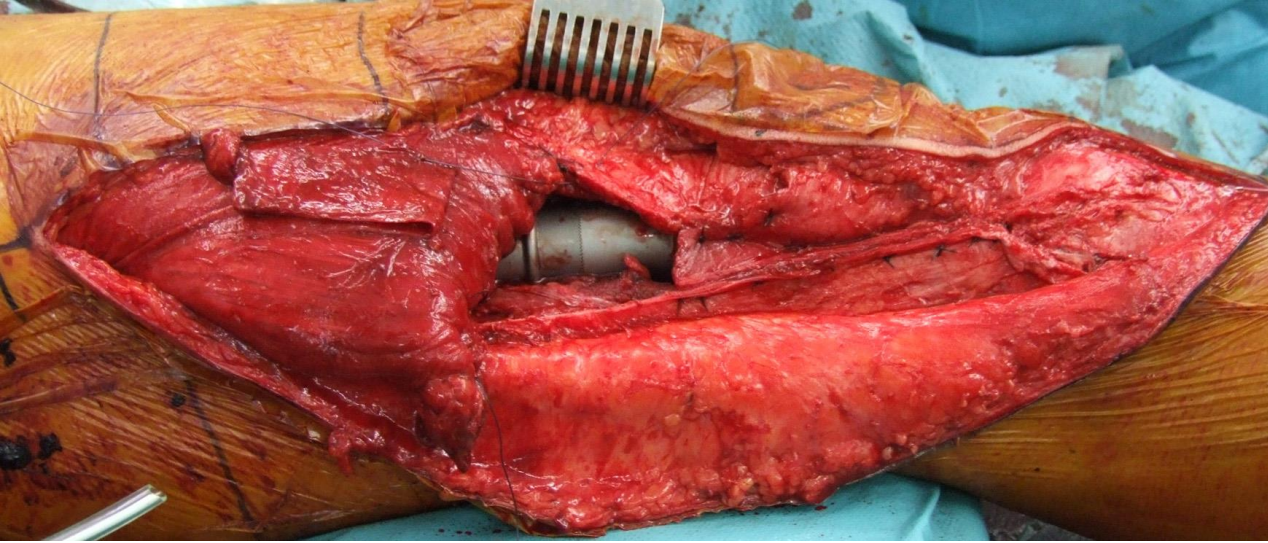
1 cm

14 mm

110 STD  
140N  
107188

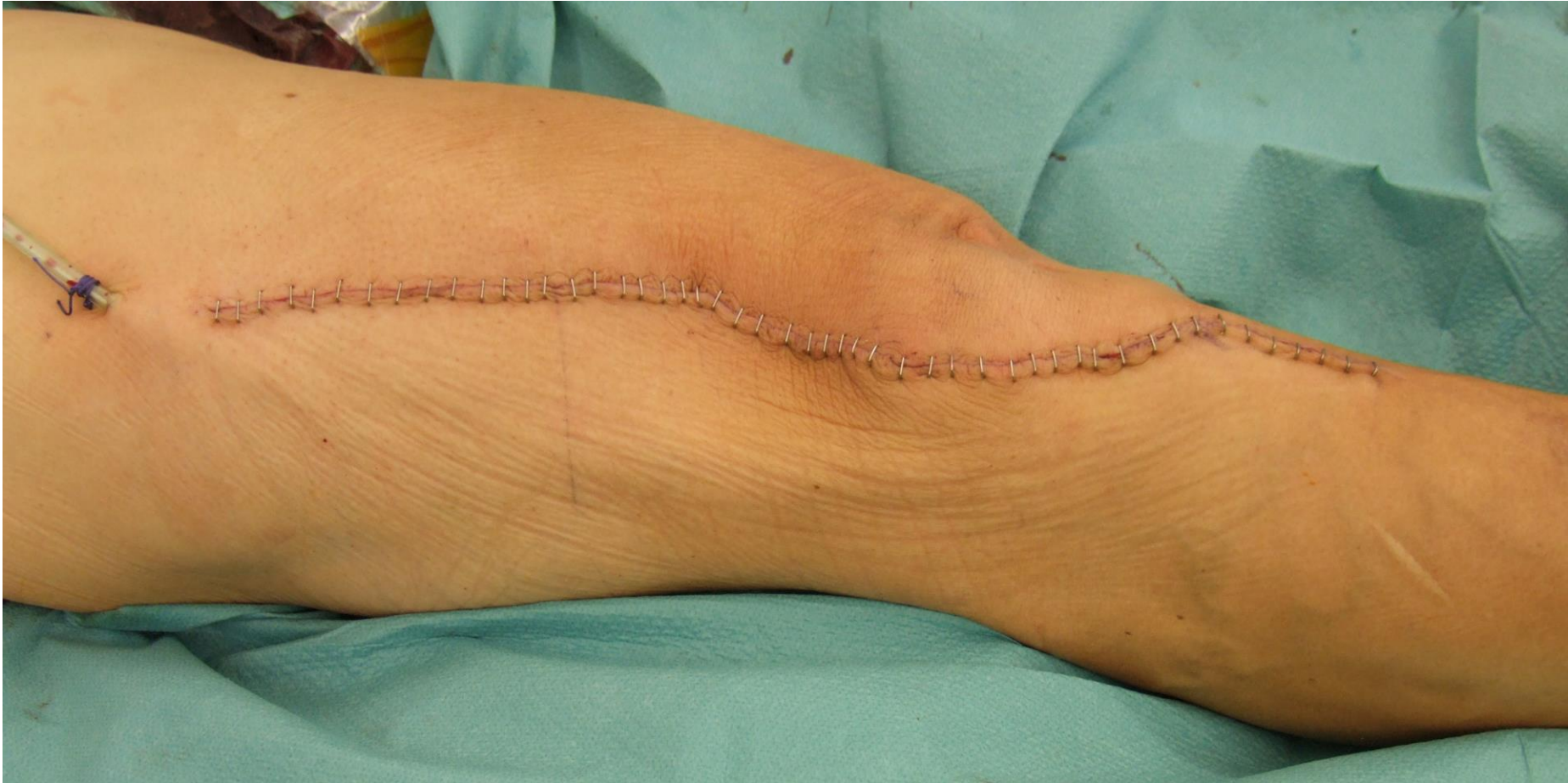# distal femur; extra-articular resection

09-09-2008

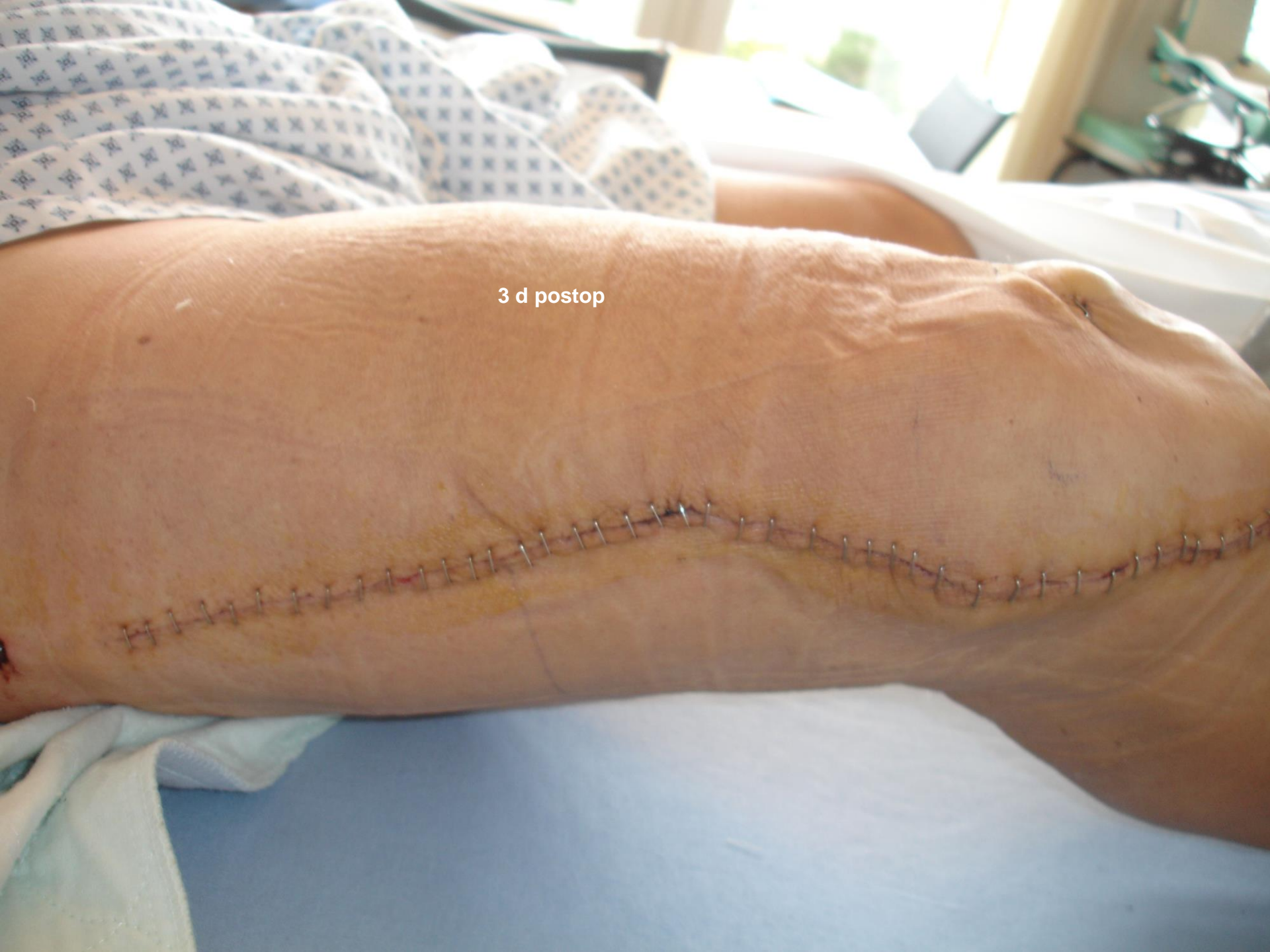


# distal femur; extra-articular resection

09-09-2008

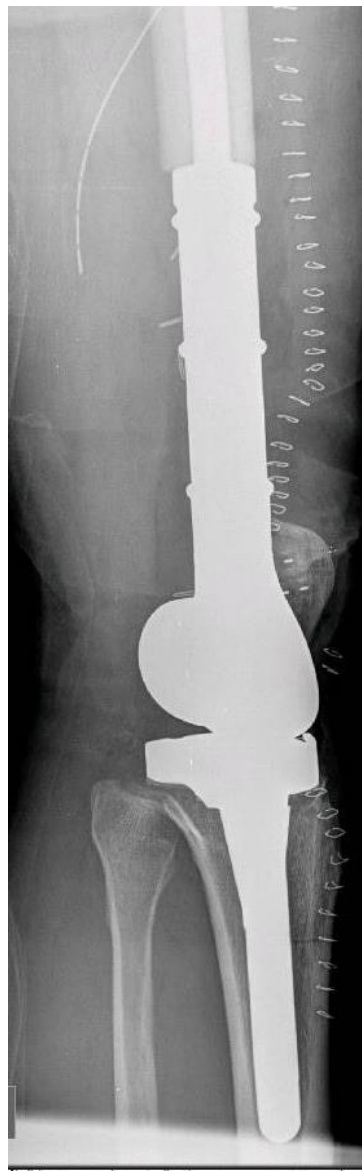
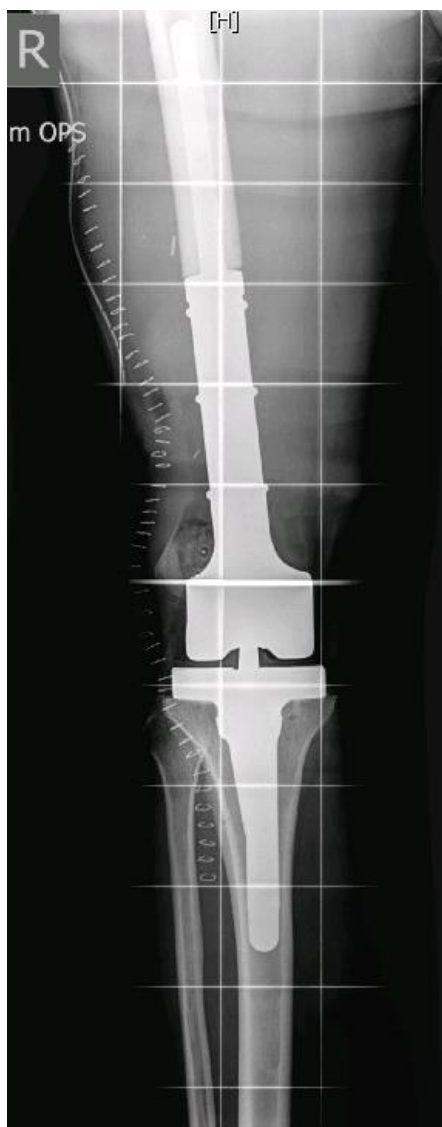
3 d postop



# distal femur; extra-articular resection

09-09-2008



# **distal femur; extra-articular resection**

## **Pathology**

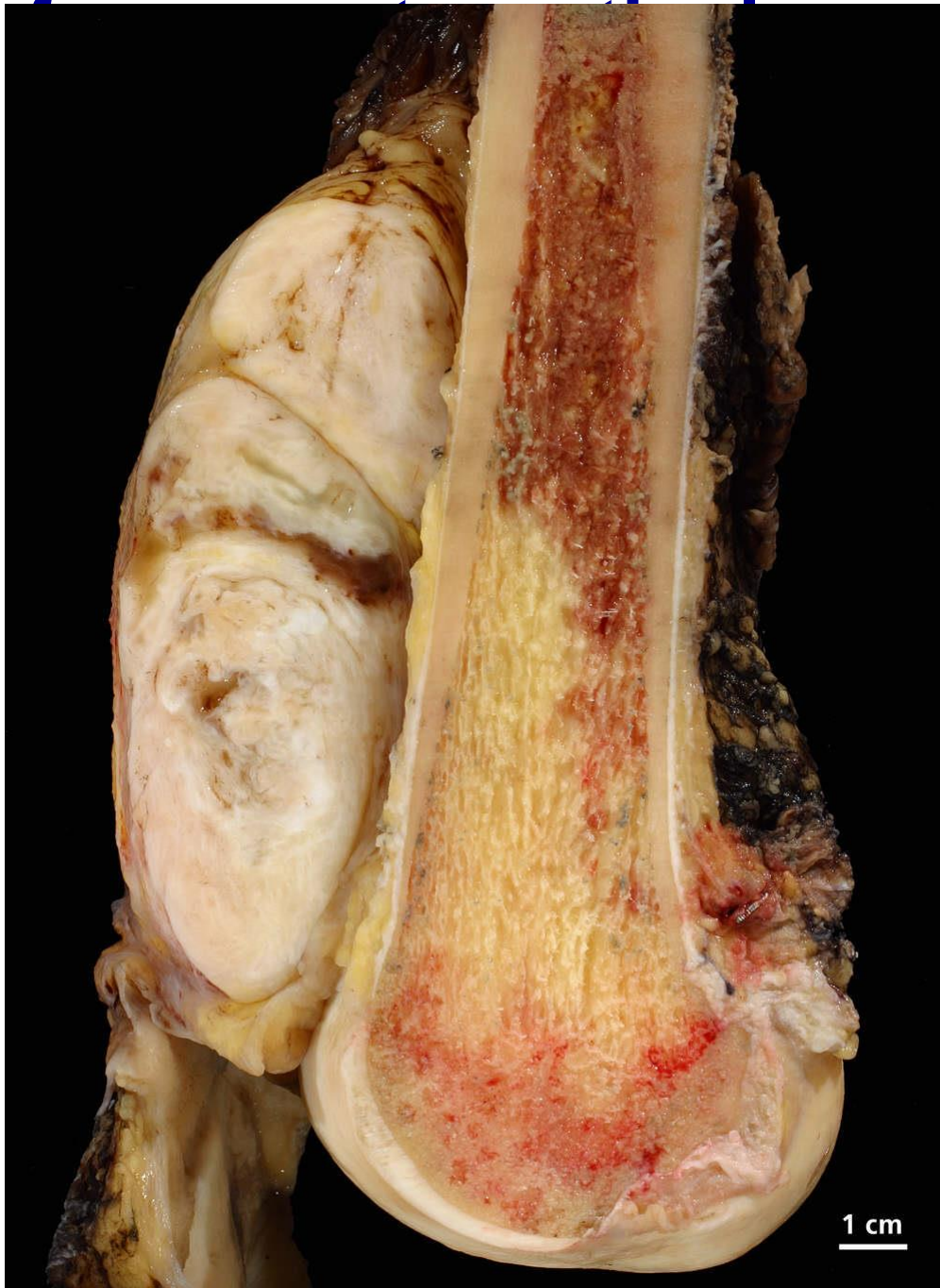**Knee resection**

**extra- and intraarticular myxoid spindle cell sarcoma, with osteosarcomatous differentiation; FNCLCC Grade 2;  
margins free of tumor**



distal

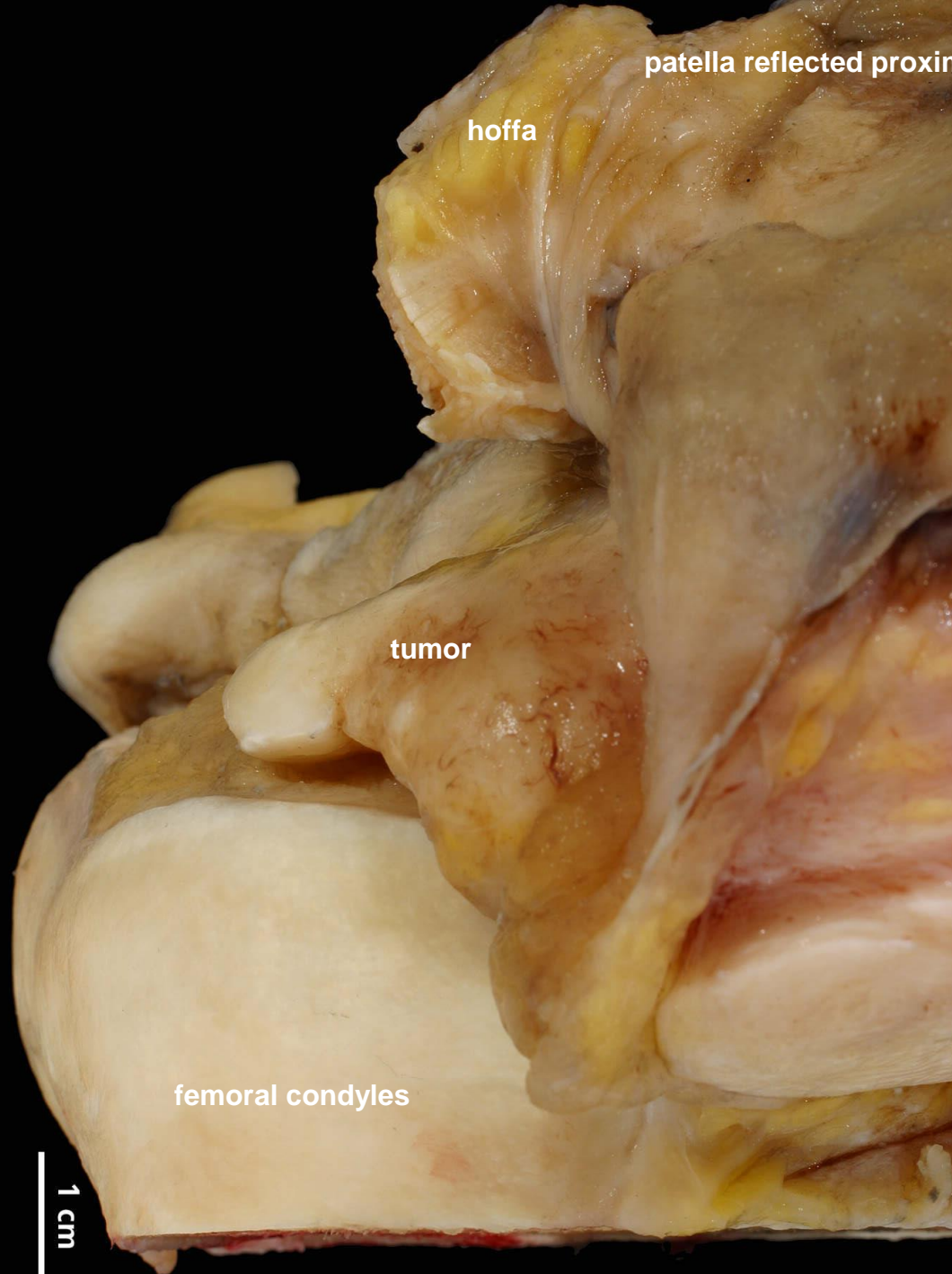
section



1 cm

distal

patella reflected proximal section



hoffa

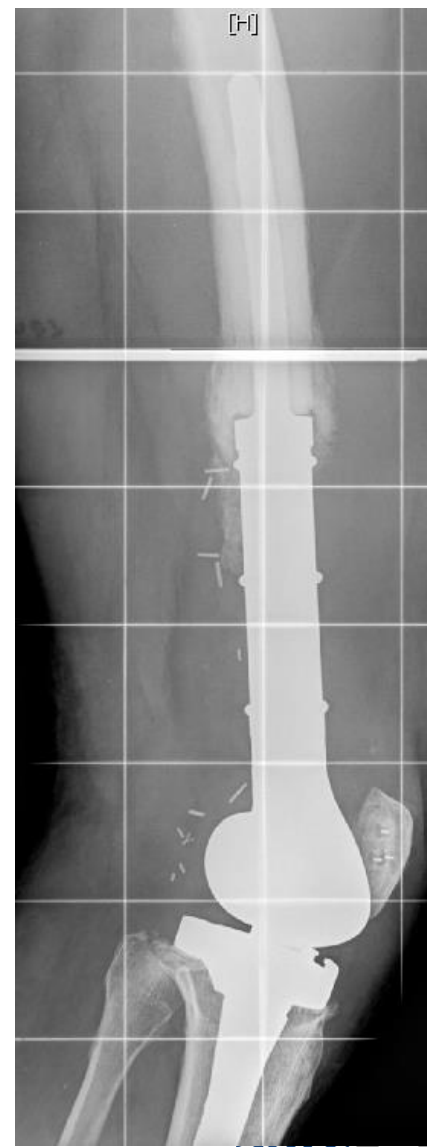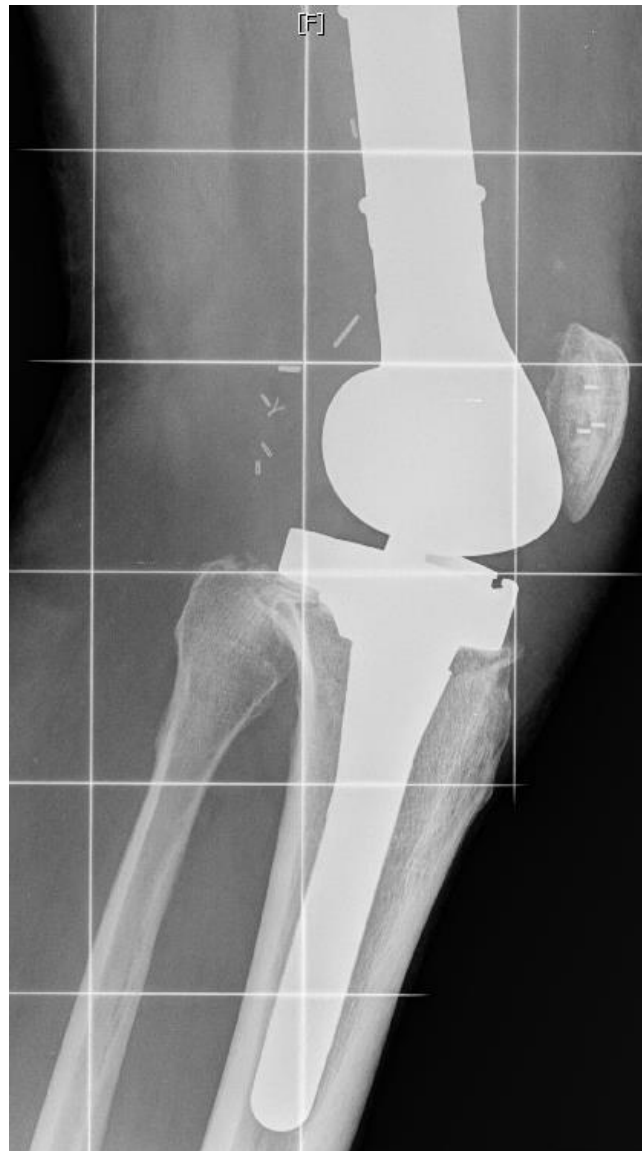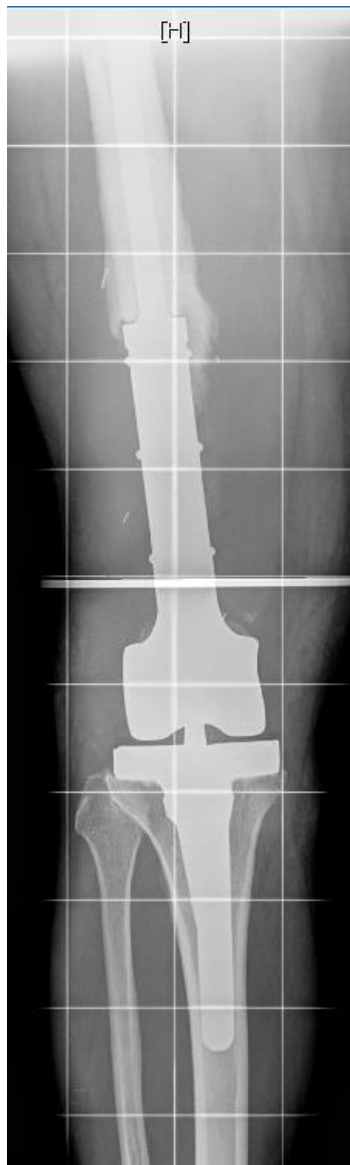tumor

femoral condyles

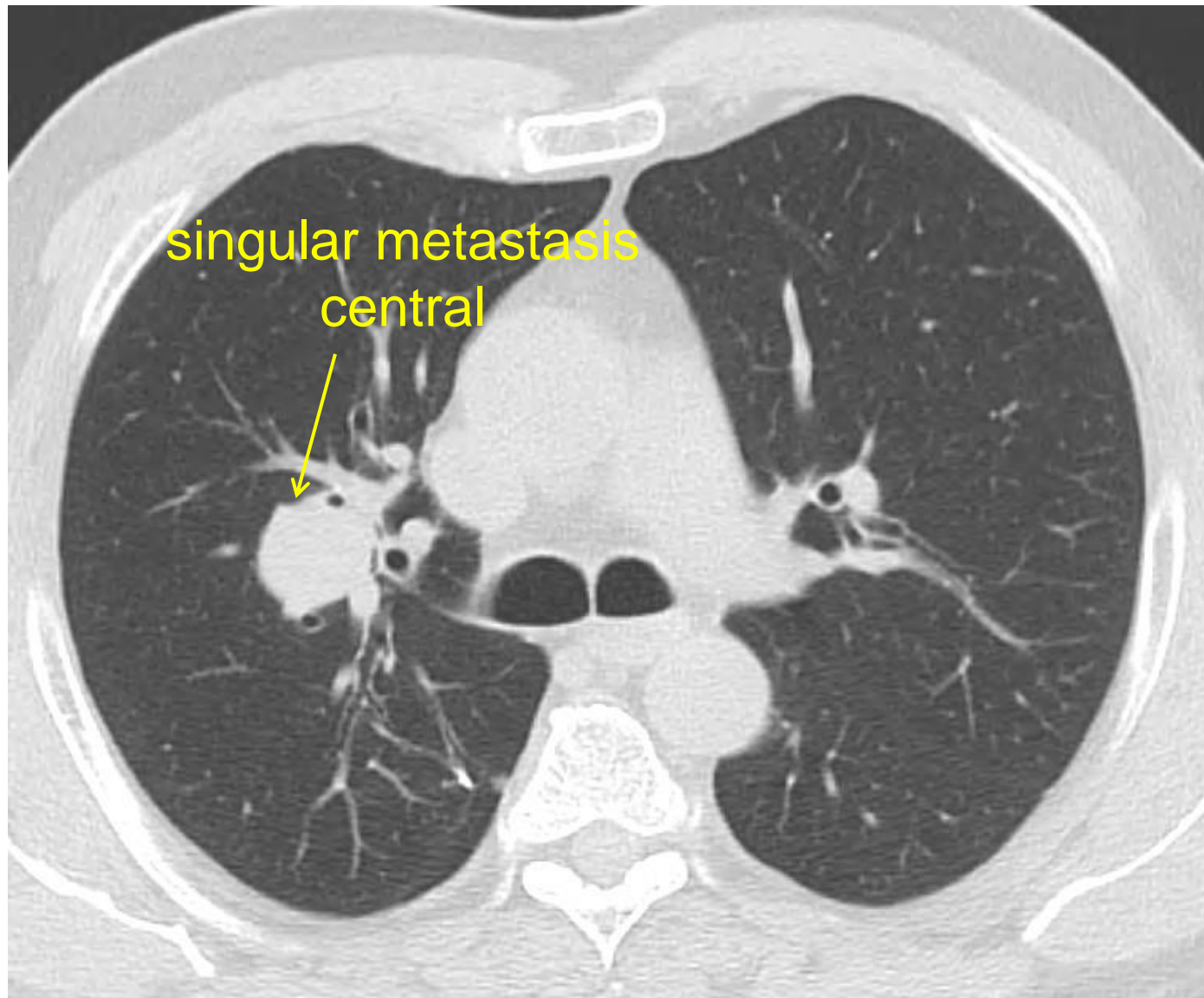
1 cm

# distal femur; extra-articular resection

## follow-up, Mar 4, 2009



# distal femur; extra-articular resection follow-up, Mar 4, 2009



# distal femur; extra-articular resection

**31.03.09:**

**Open resection upper lobe and partial  
resection lower lobe, right side, USZ**

**→ palliative chemotherapy (04.05.09-  
20.06.09)**

# **distal femur; extra-articular resection**

## **fup**

**Patient dies May 12, 2010**

SURGICAL TECHNIQUE

# **Extraarticular Knee Resection for Sarcomas with Preservation of the Extensor Mechanism**

## **Surgical Technique and Review of Cases**

**Pawel Zwolak MD, Stefanie P. Kühnel MD,  
Bruno Fuchs MD, PhD**

Received: 23 October 2009 / Accepted: 7 April 2010 / Published online: 24 April 2010

© The Association of Bone and Joint Surgeons® 2010