

proximal fibula; LCL allograft

f / 49yo

Hauptdiagnose

Unklarer Knochentumor proximale Fibula Knie rechts
DD Riesenzelltumor des Knochens
- St.n. Biopsie unter Durchleuchtung am 26.09.2017

Nebendiagnosen

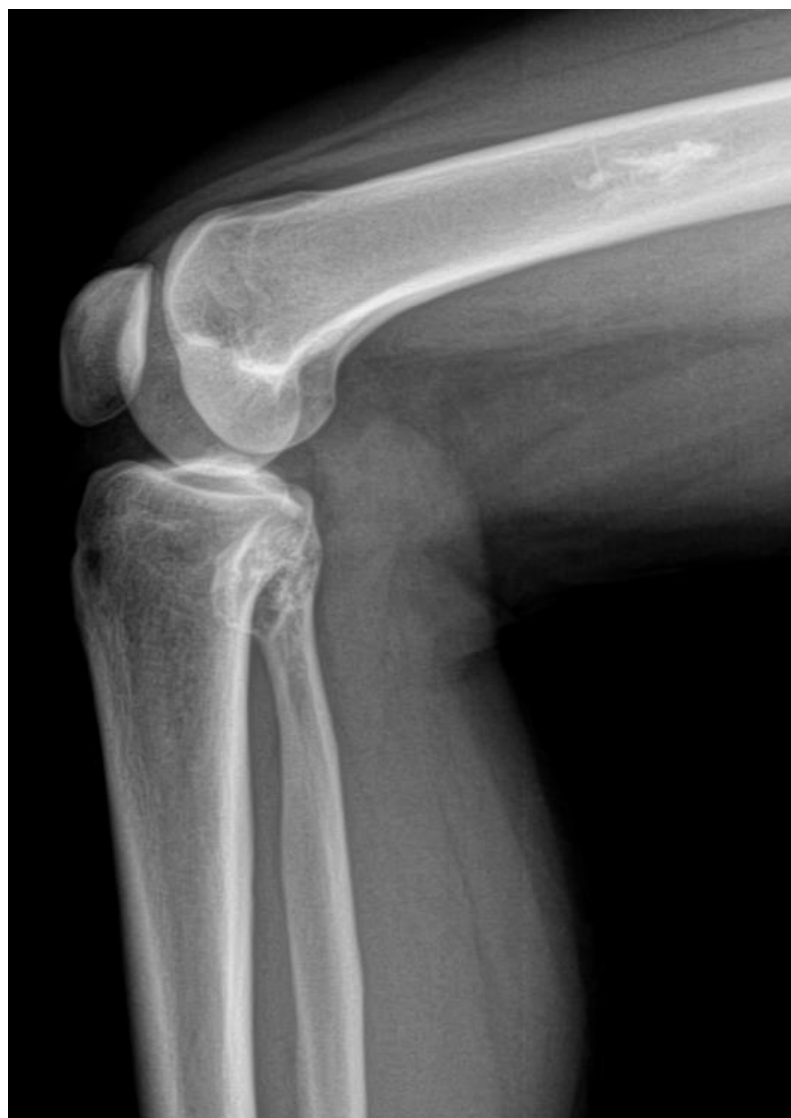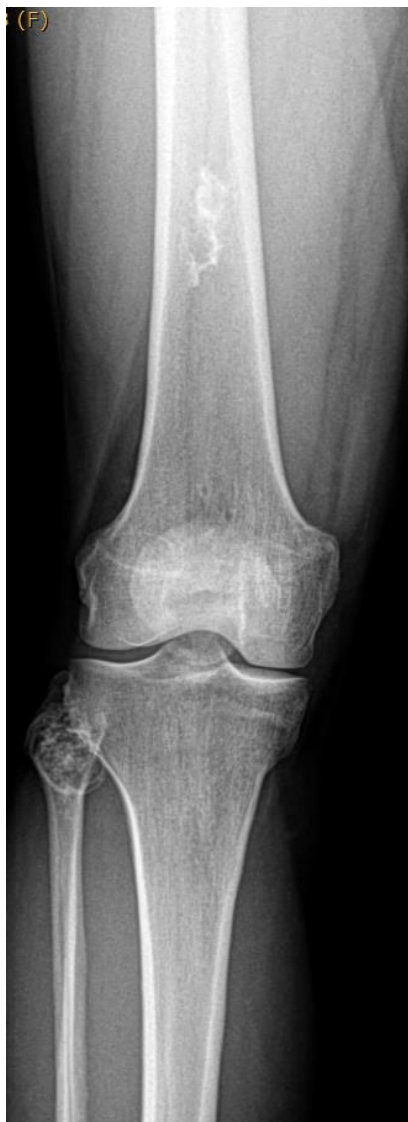Zerrung des medialen Kollateralbandes Grad I sowie des vorderen Kreuzbandes Grad I Knie rechts
am 03.08.2017

Anamnese

Im Rahmen der bildgebenden Abklärung betreffend der Seitenbandzerrung wurde eine Läsion in der proximalen Fibula ebenfalls am Knie rechts festgestellt mit Verdacht auf Riesenzelltumor.

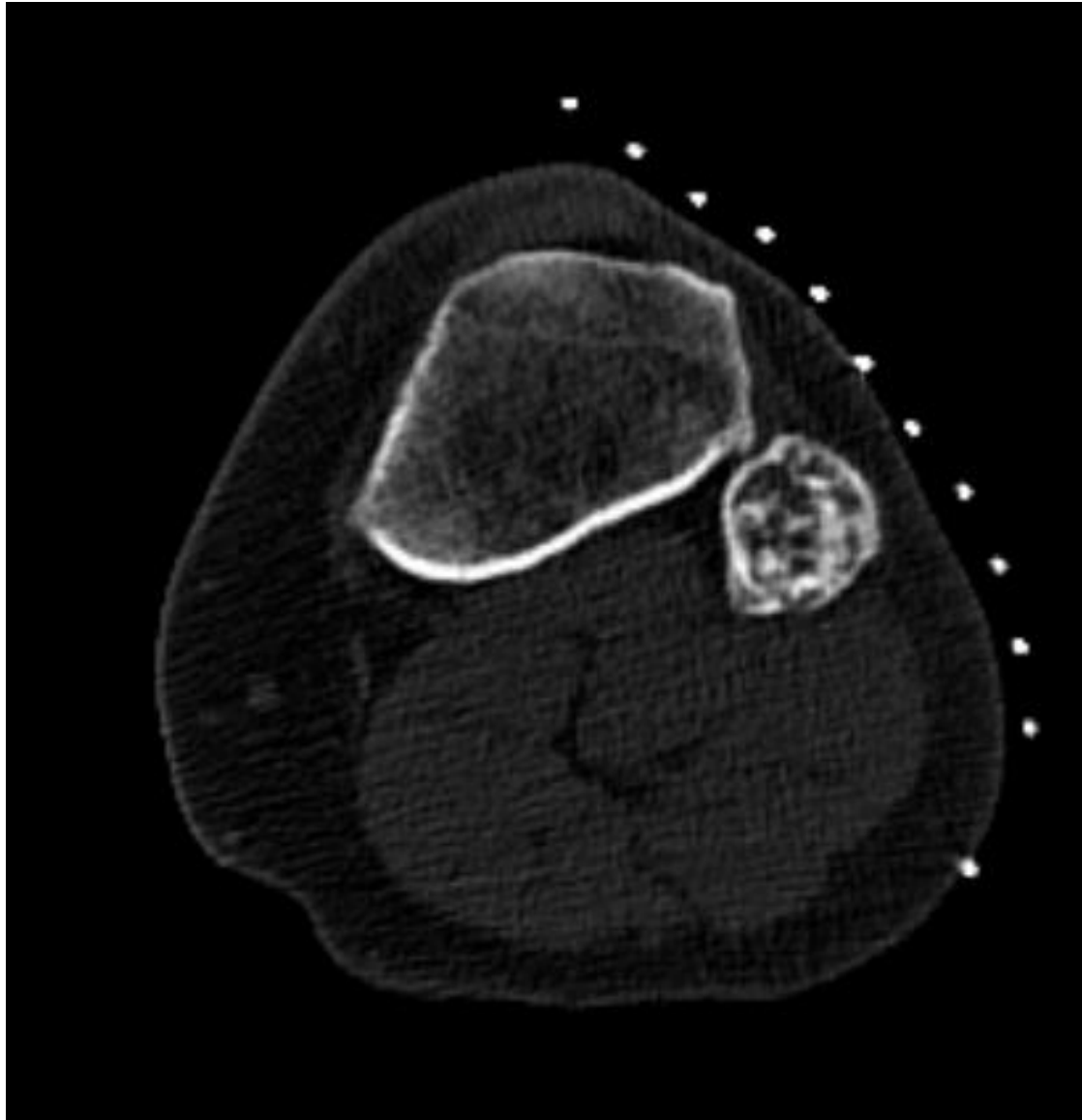
ECOG Performance Status: 0

proximal fibula; LCL allograft



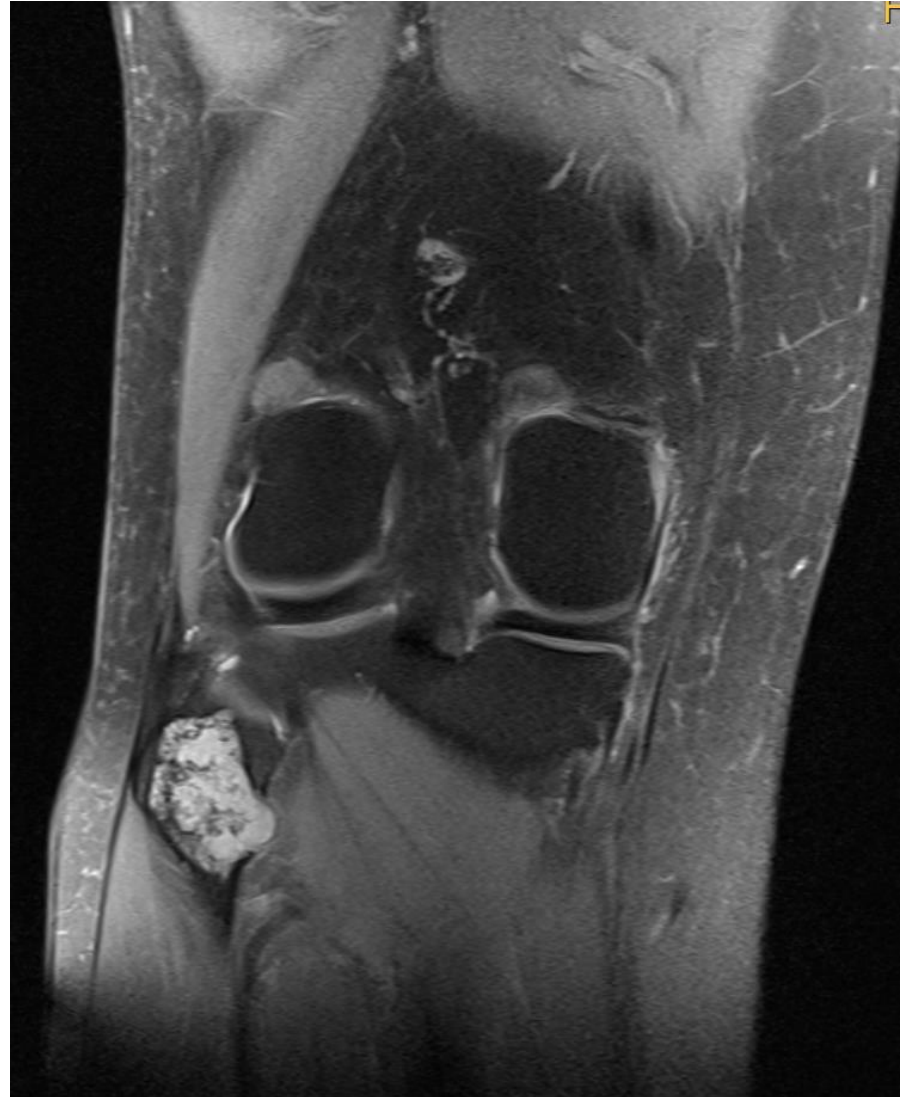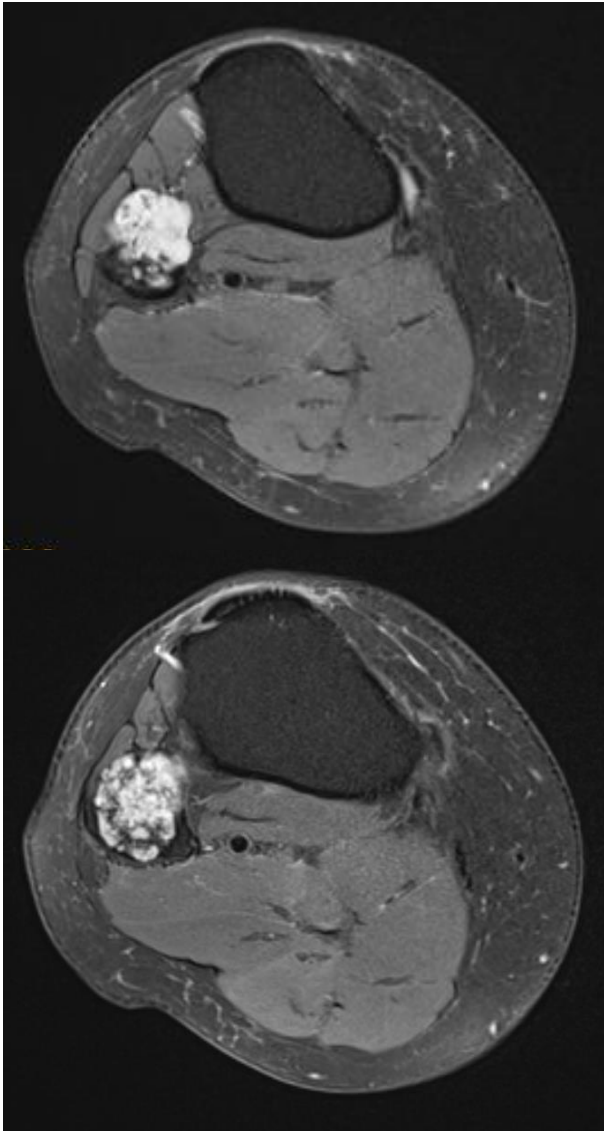
August 29, 2017

proximal fibula; LCL allograft



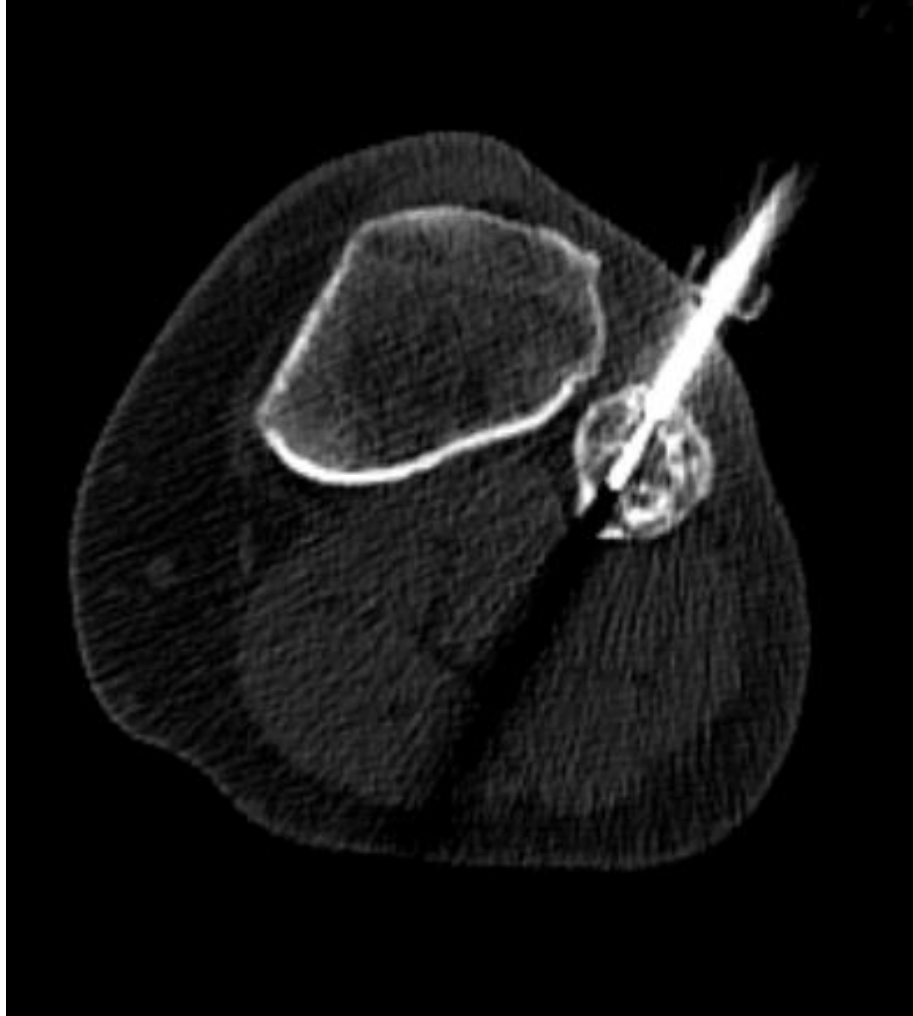
September 26, 2017

proximal fibula; LCL allograft



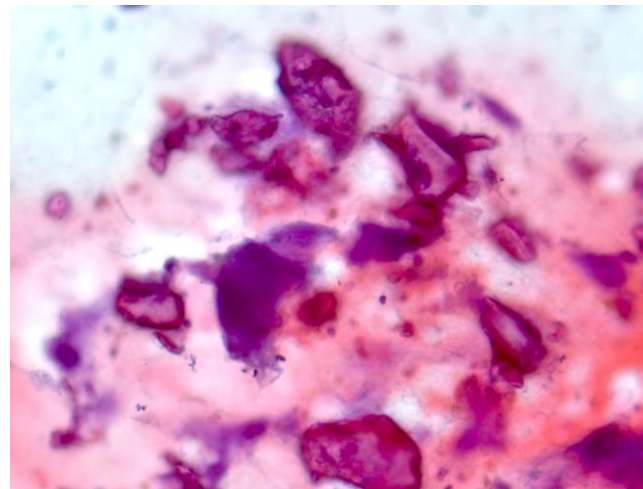
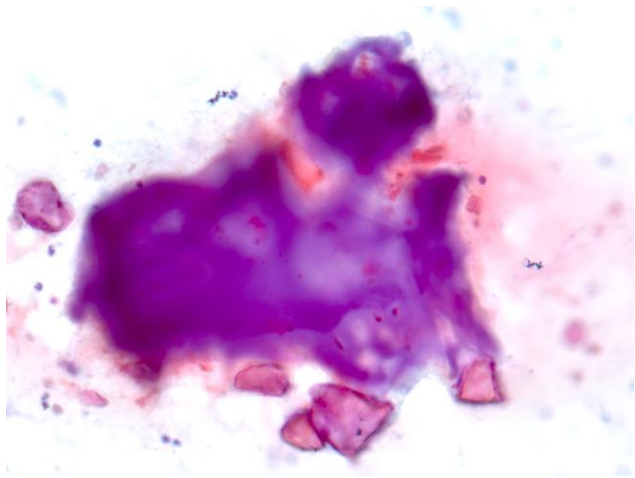
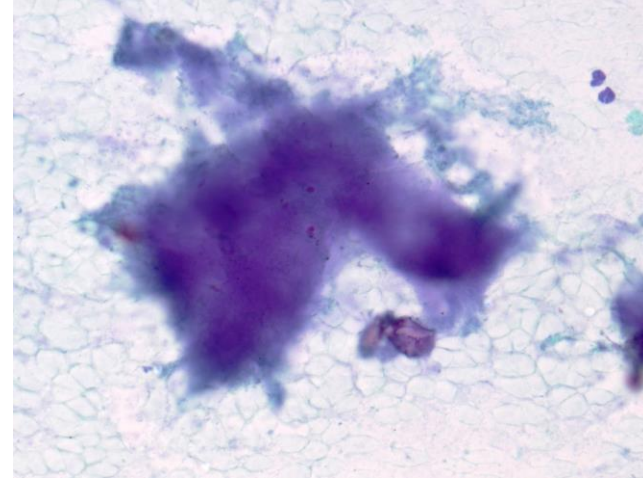
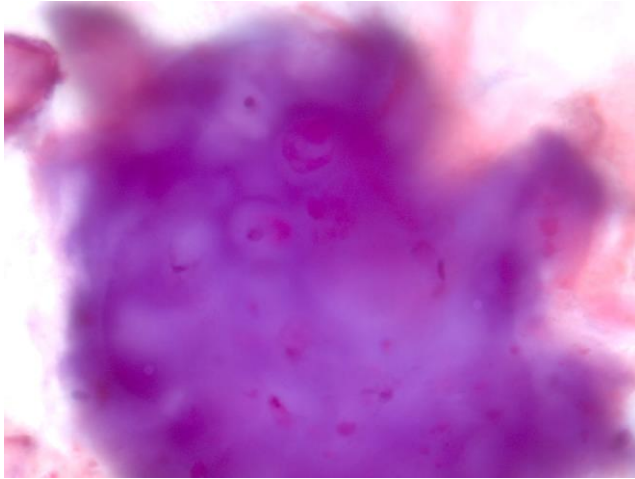
September 26, 2017

proximal fibula; LCL allograft

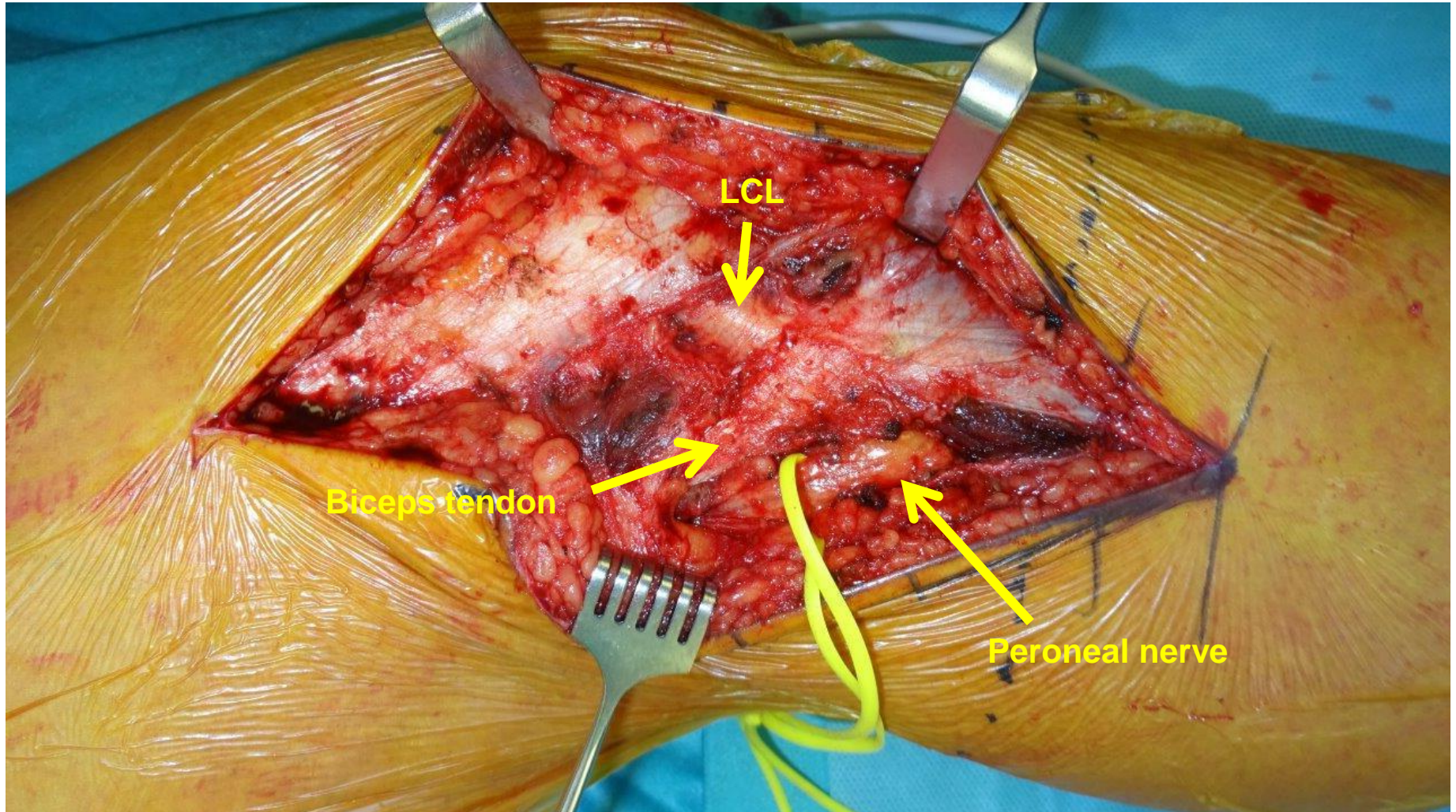


September 26, 2017

proximal fibula; LCL allograft

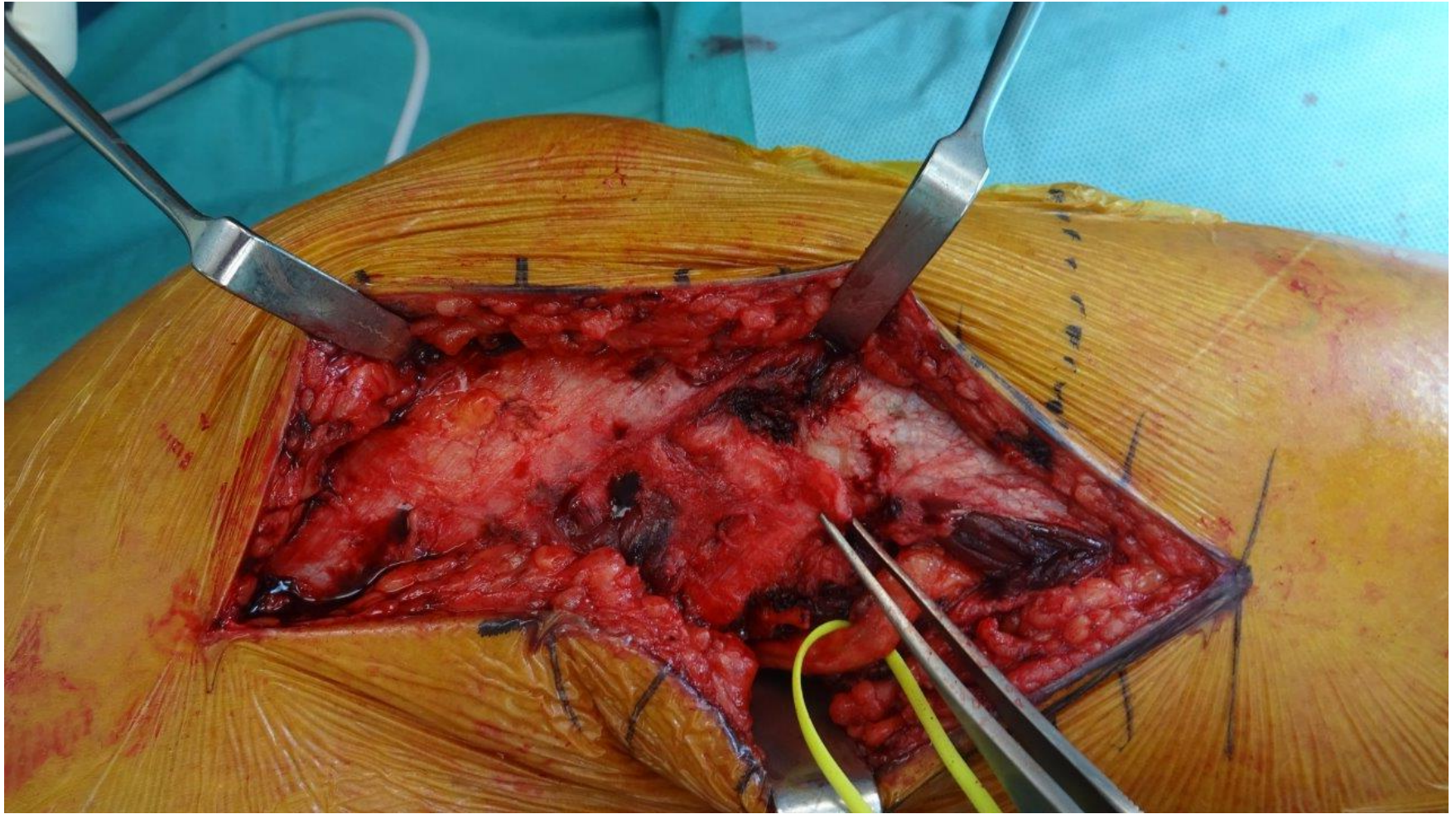


proximal fibula; LCL allograft



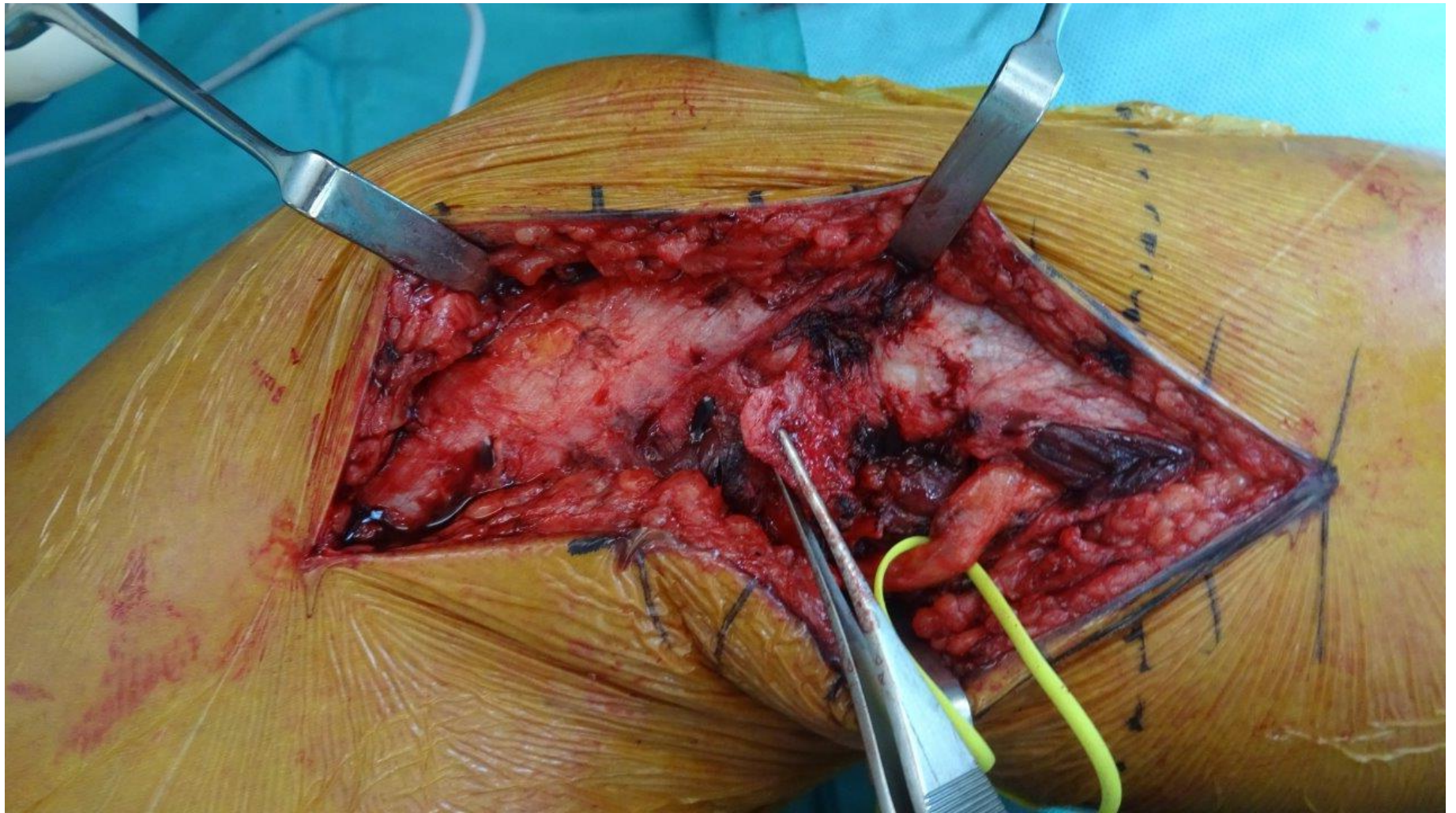
OP November 17, 2017

proximal fibula; LCL allograft



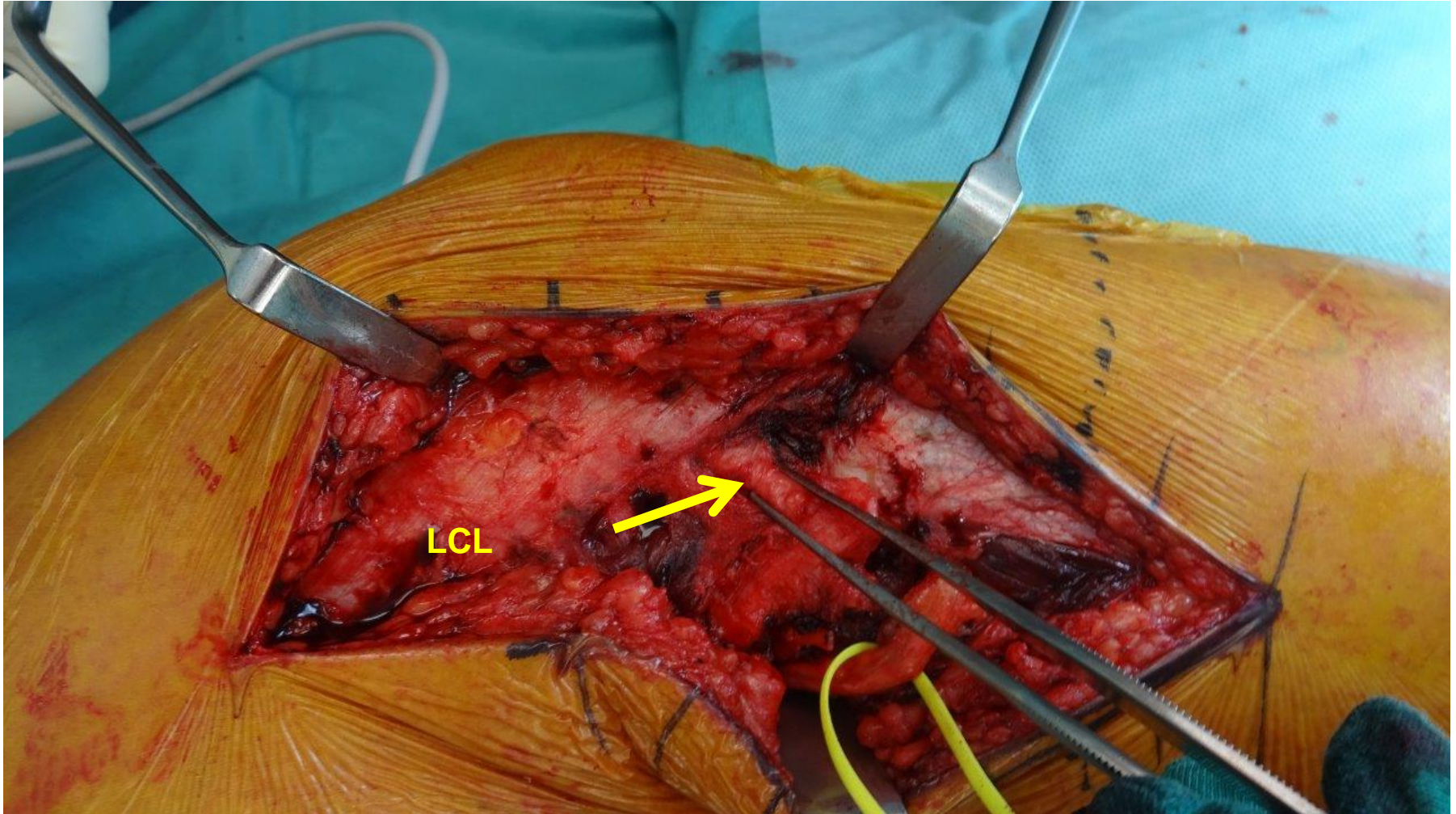
OP November 17, 2017

proximal fibula; LCL allograft



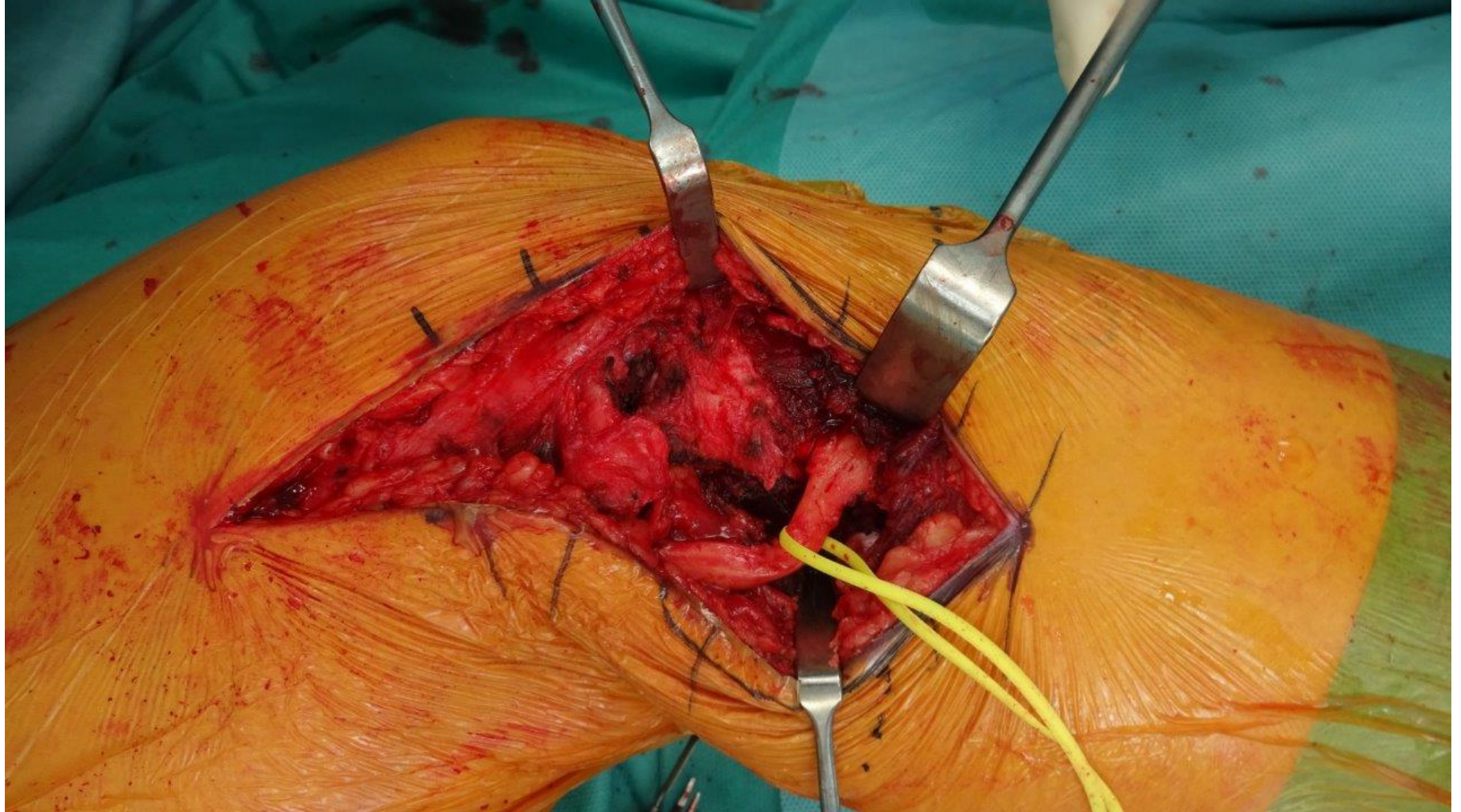
OP November 17, 2017

proximal fibula; LCL allograft



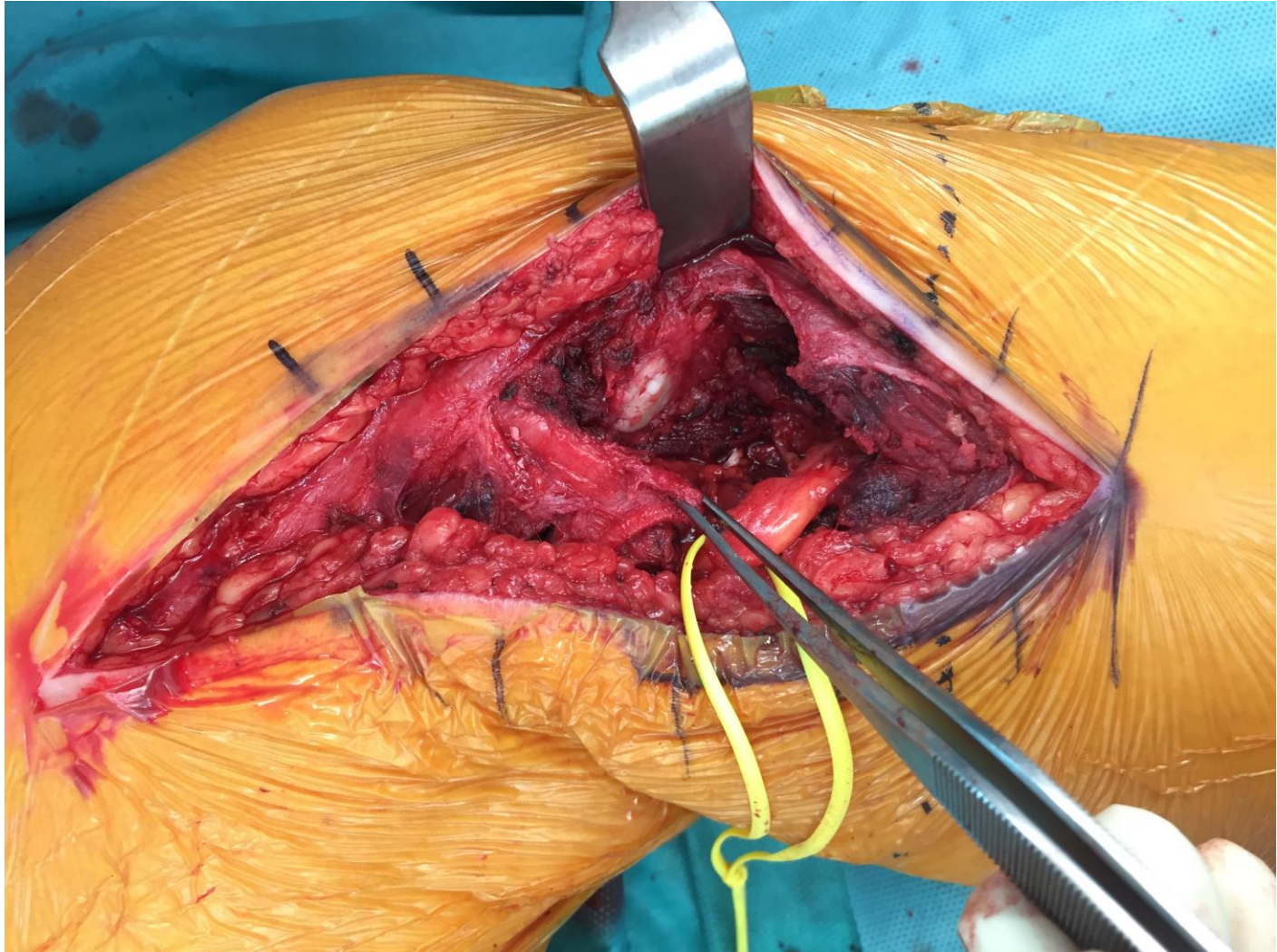
OP November 17, 2017

proximal fibula; LCL allograft



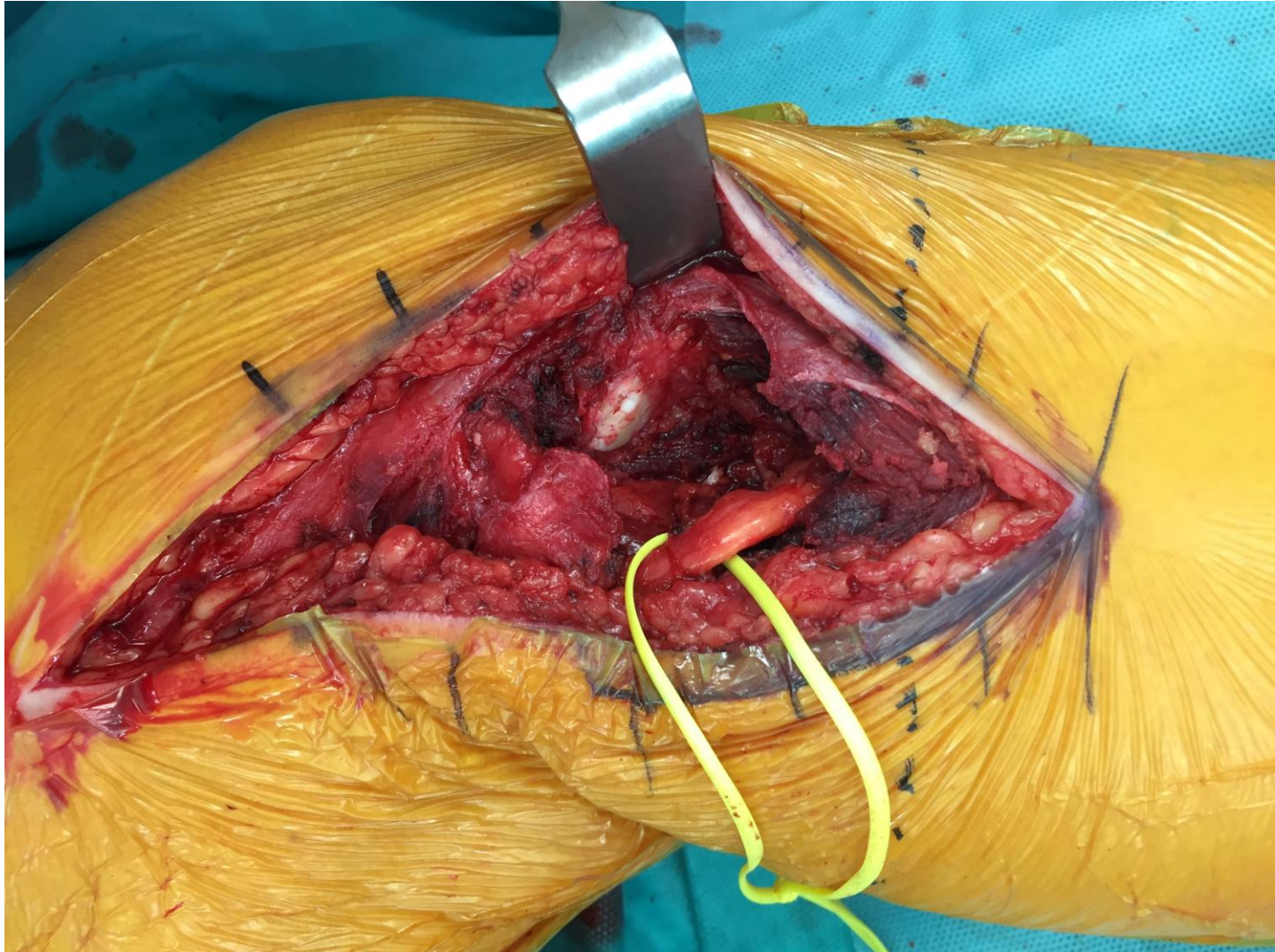
OP November 17, 2017

proximal fibula; LCL allograft



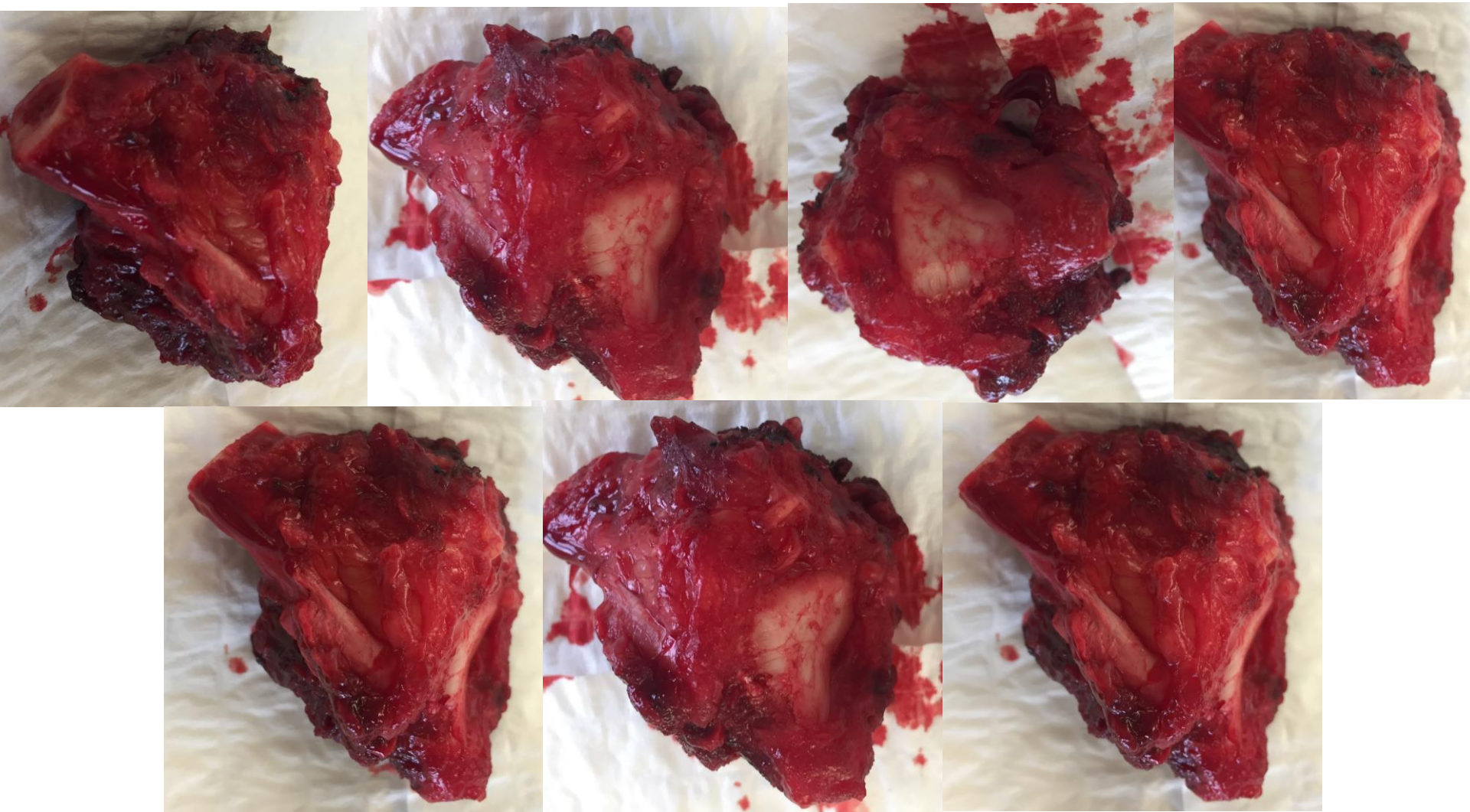
OP November 17, 2017

proximal fibula; LCL allograft



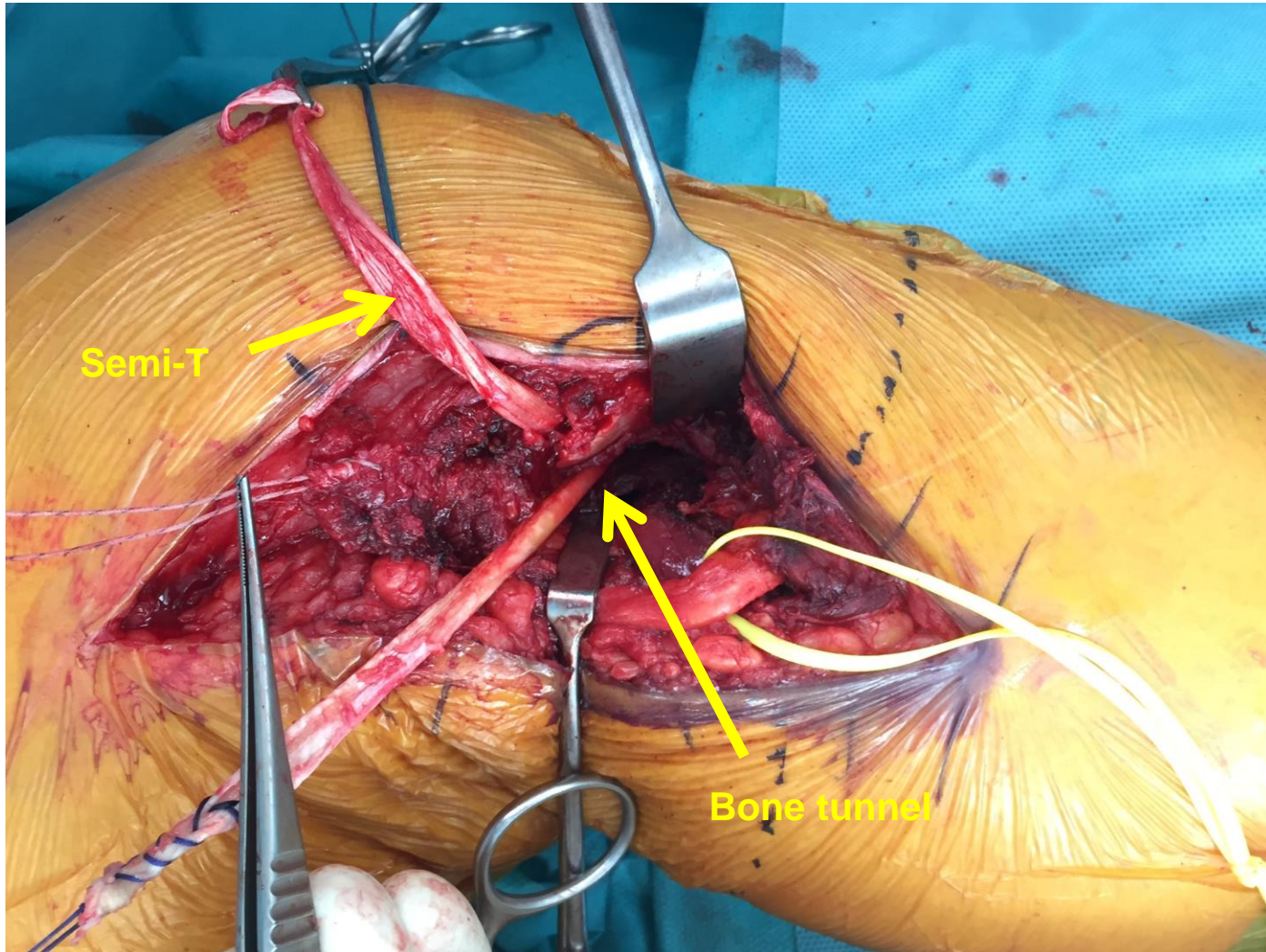
OP November 17, 2017

proximal fibula; LCL allograft



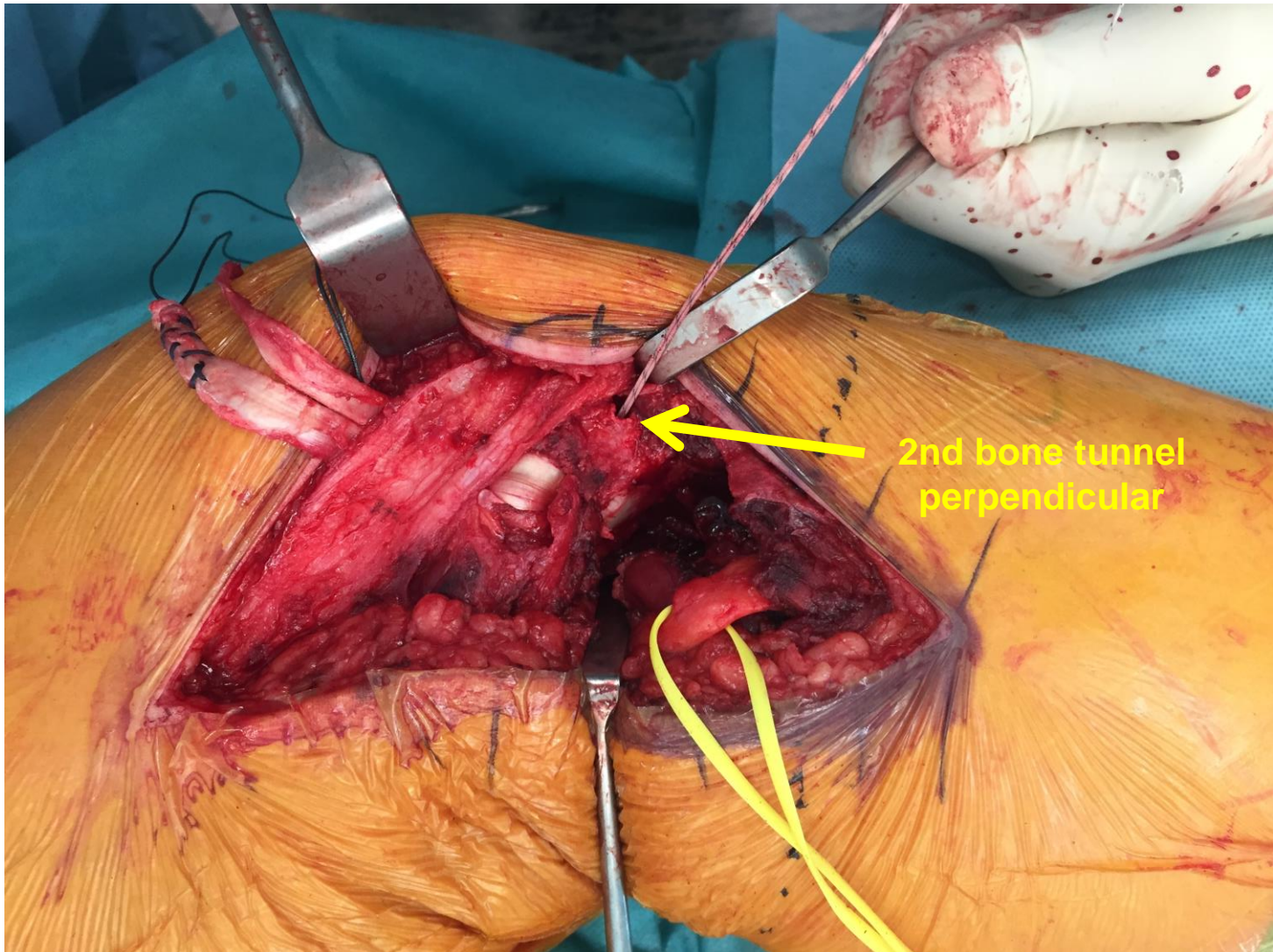
OP November 17, 2017

proximal fibula; LCL allograft



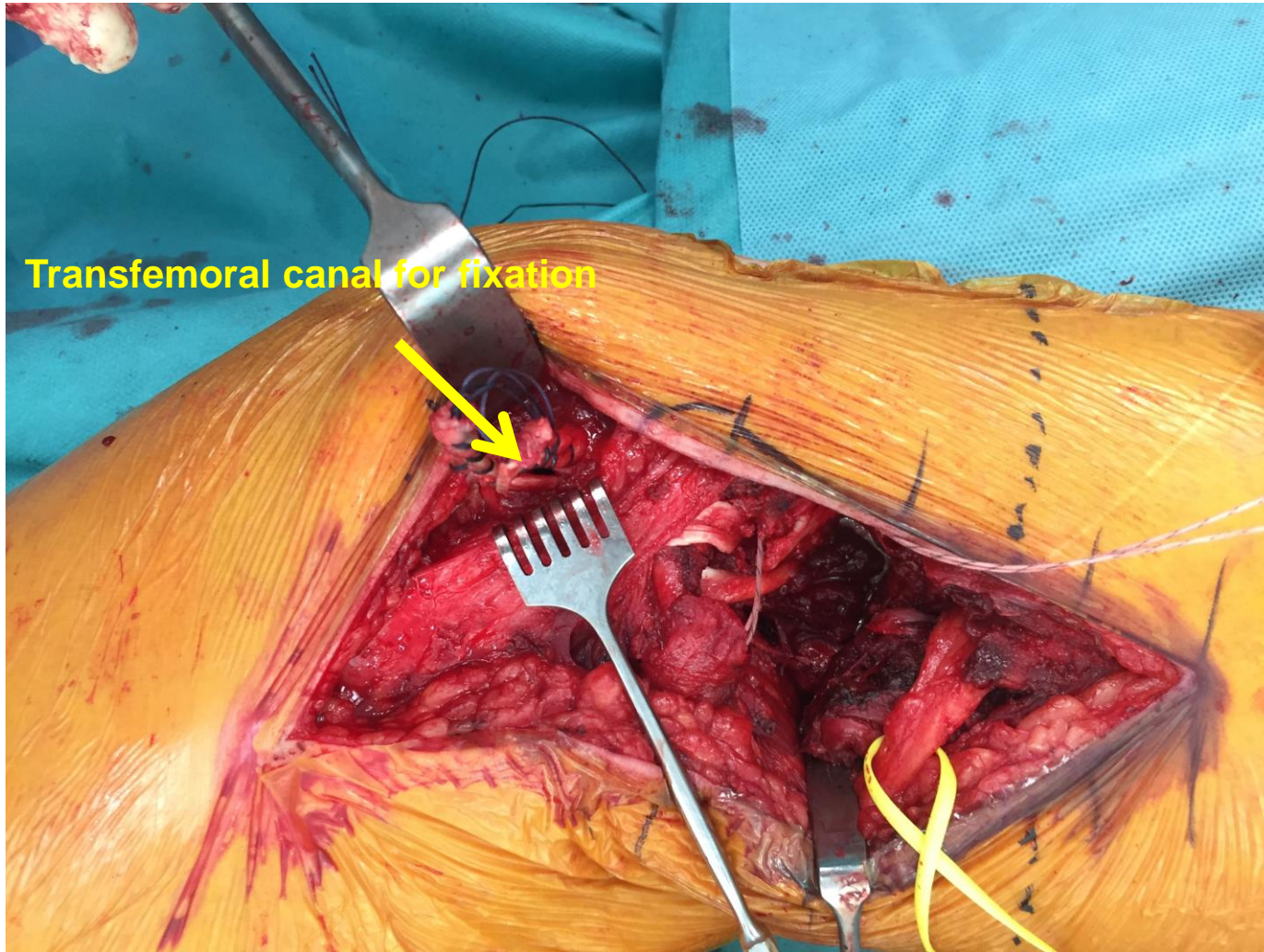
OP November 17, 2017

proximal fibula; LCL allograft



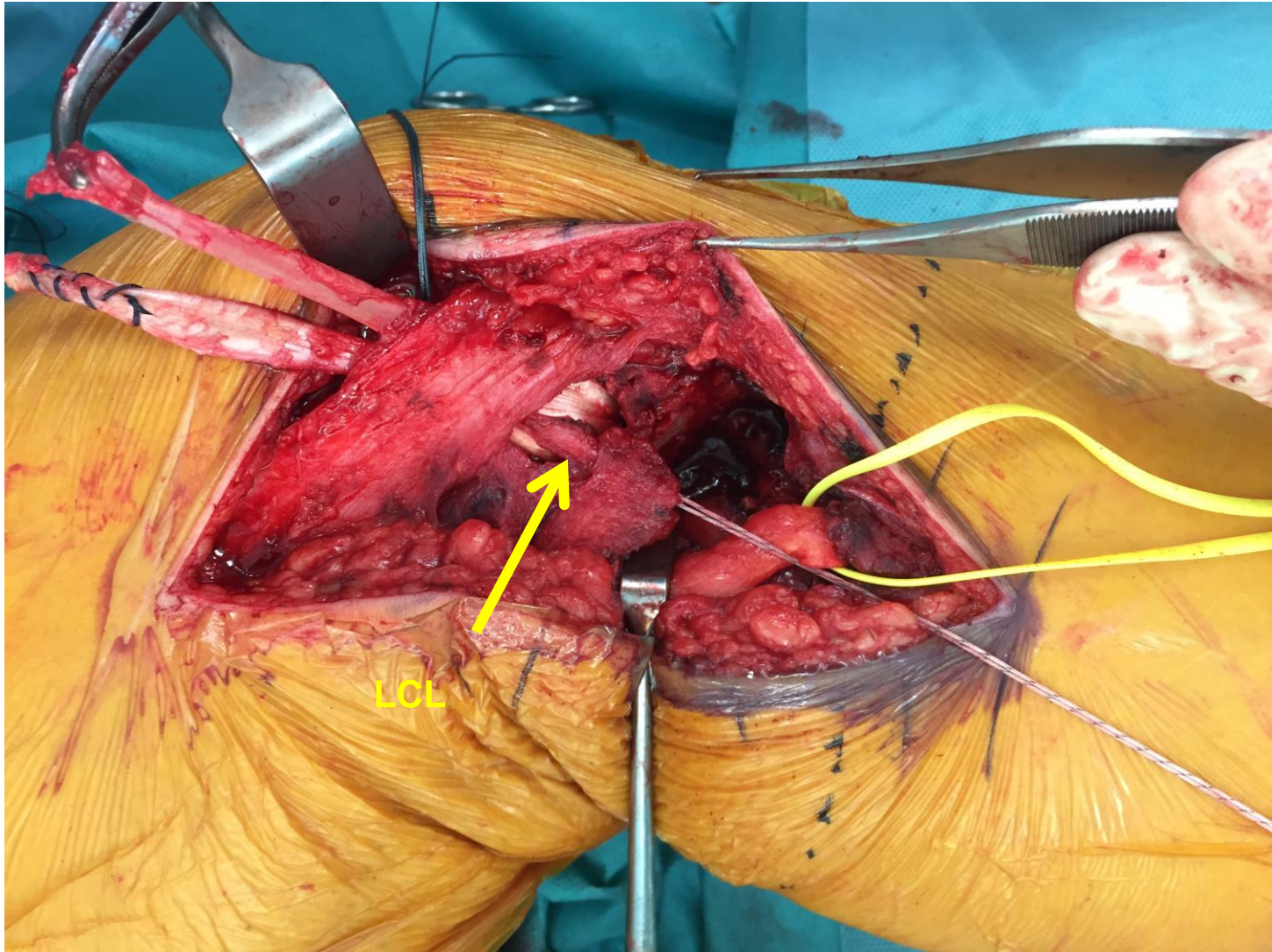
OP November 17, 2017

proximal fibula; LCL allograft



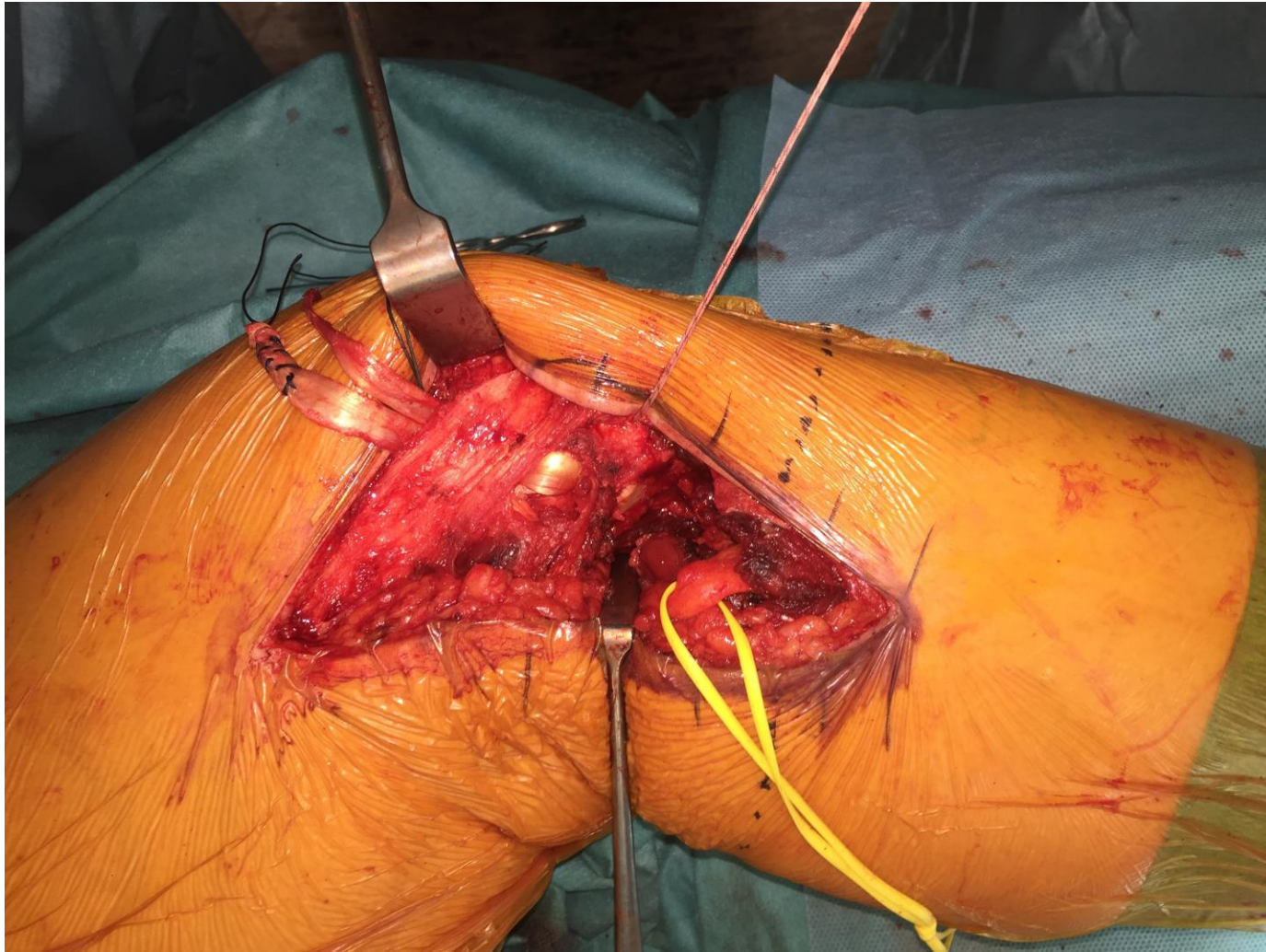
OP November 17, 2017

proximal fibula; LCL allograft



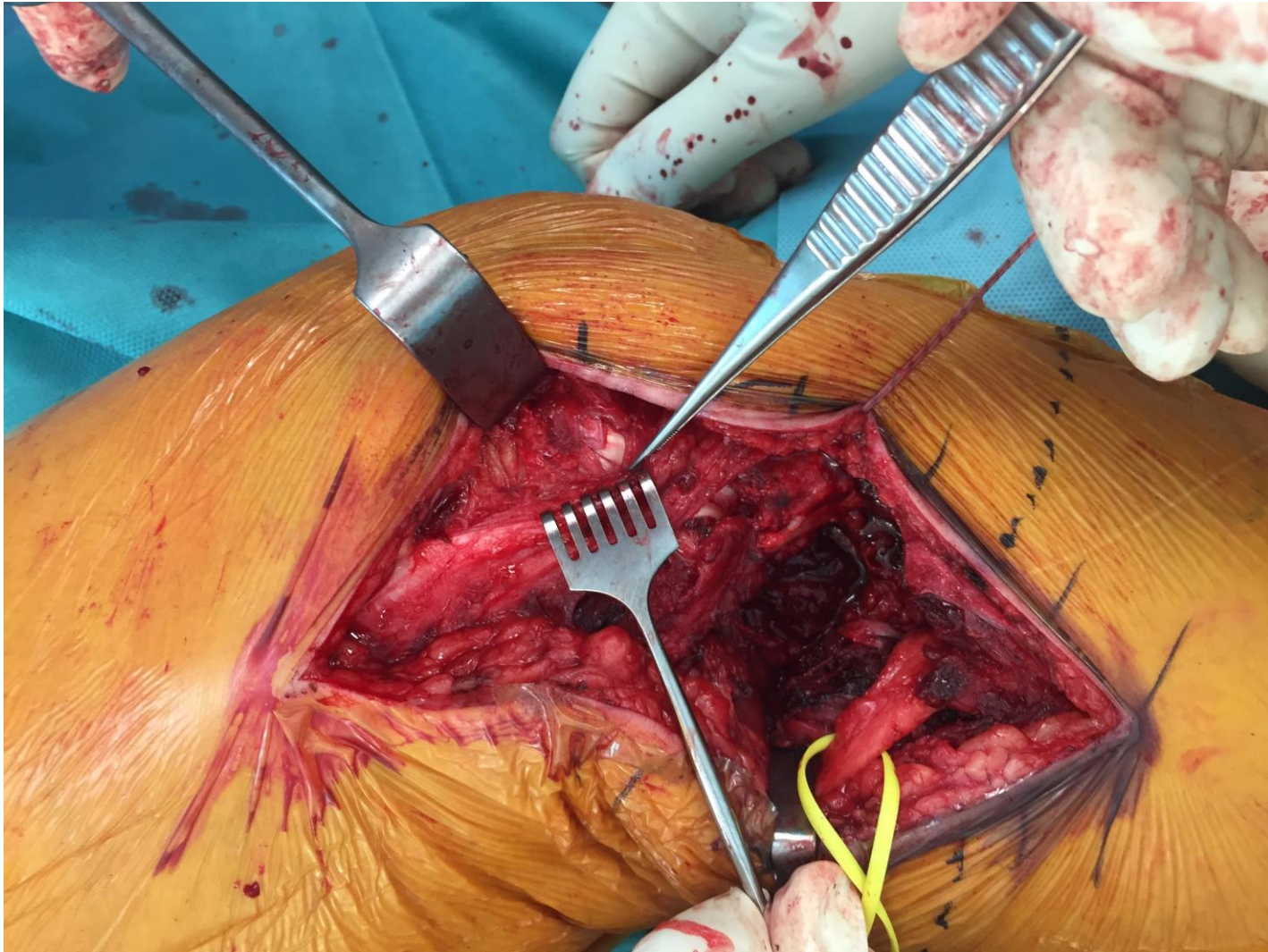
OP November 17, 2017

proximal fibula; LCL allograft



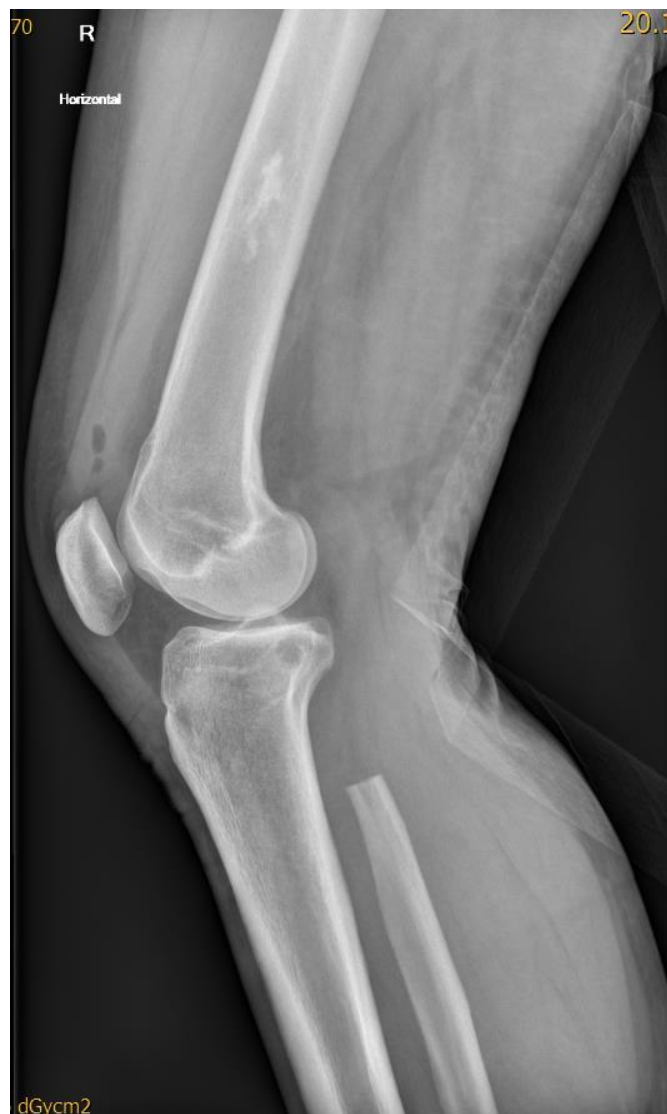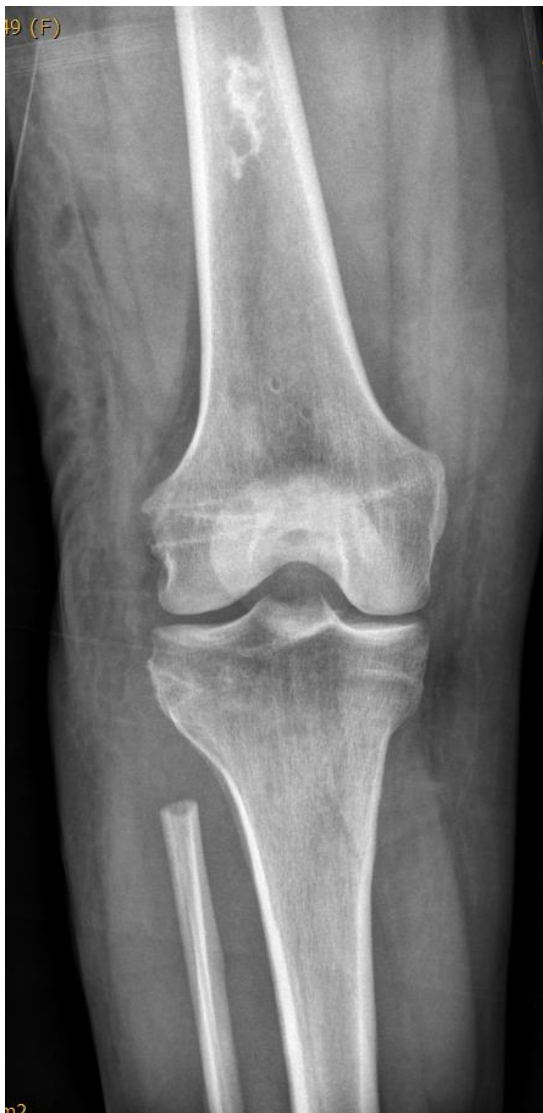OP November 17, 2017

proximal fibula; LCL allograft



OP November 17, 2017

proximal fibula; LCL allograft



November 20, 2017