

Scapula; 3D precision partial resection

♀ 56 yo

1st referral : 15.11.2006

HPI : longlasting pain in left shoulder (over-head use, sports, lying on left side), slowly growing infraclavicular tumor, new diminution of rotational strength

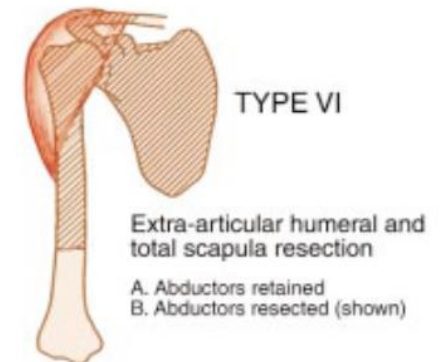
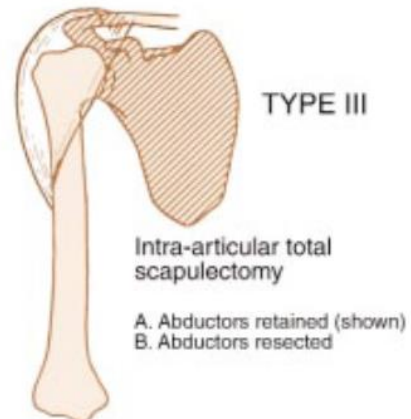
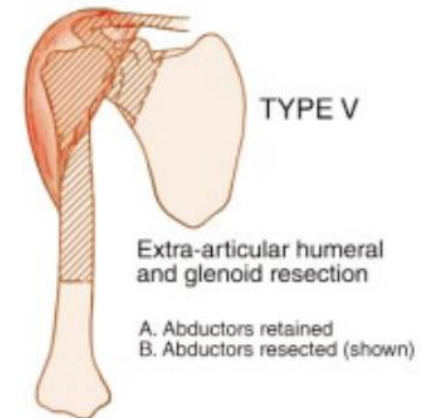
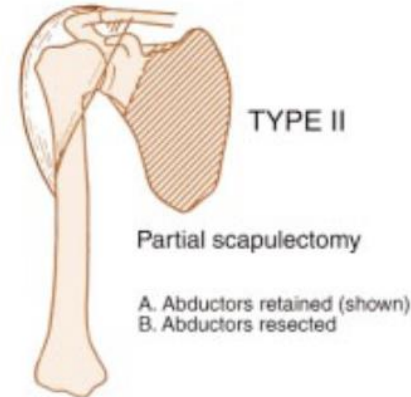
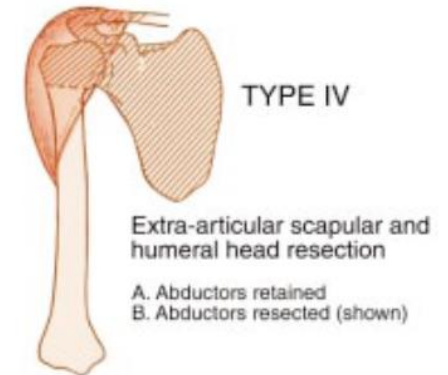
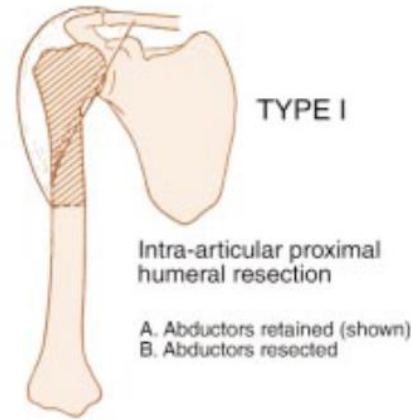
Referral after external x-ray follow-up

PMH : non contributory

axillary nerve?

intra- / transarticular?

level of OT & abductor?



Scapula; 3D precision partial resection

Nov 15, 2006

Clinical examination :

Big palpable non-tender infraclavicular tumor

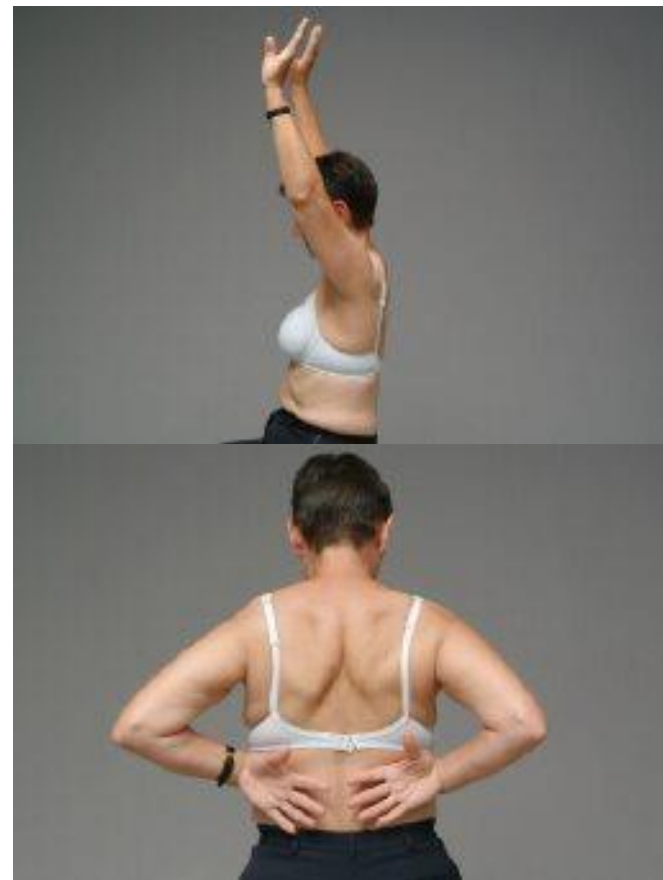
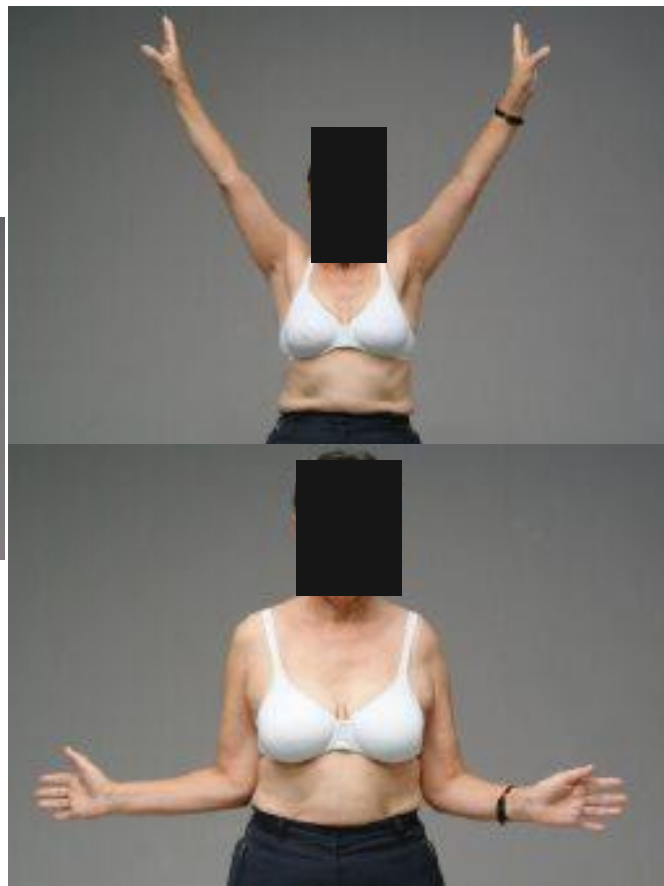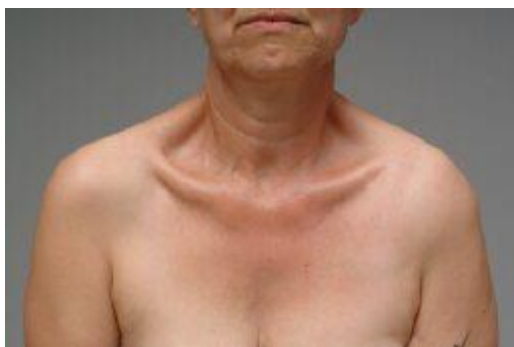Reduced active external rotation

Reduced strength for external and internal rotation (M4)

Normal peripheral neurological status

Scapula; 3D precision partial resection

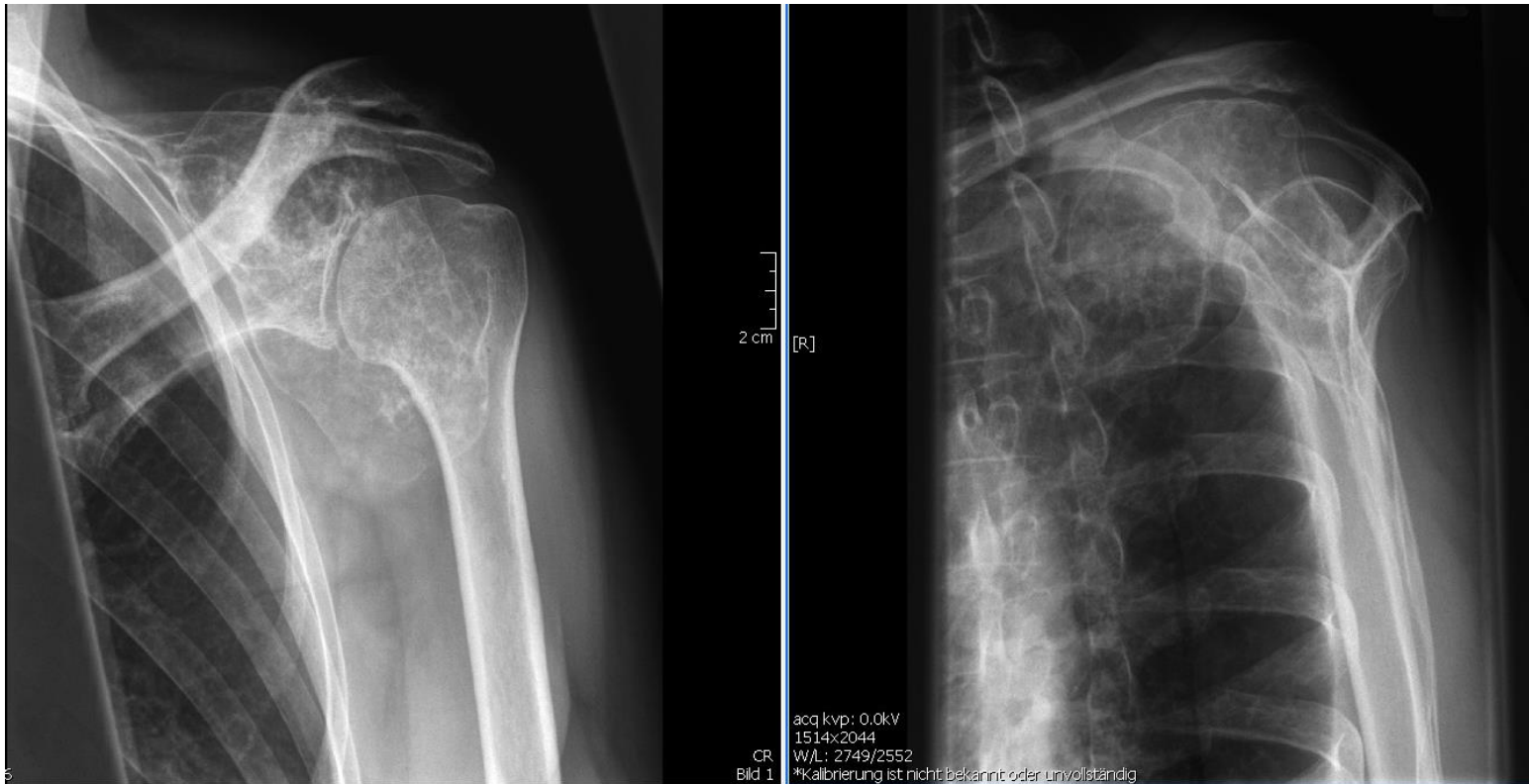
Nov 15, 2006



Scapula; 3D precision partial resection

Nov 15, 2006

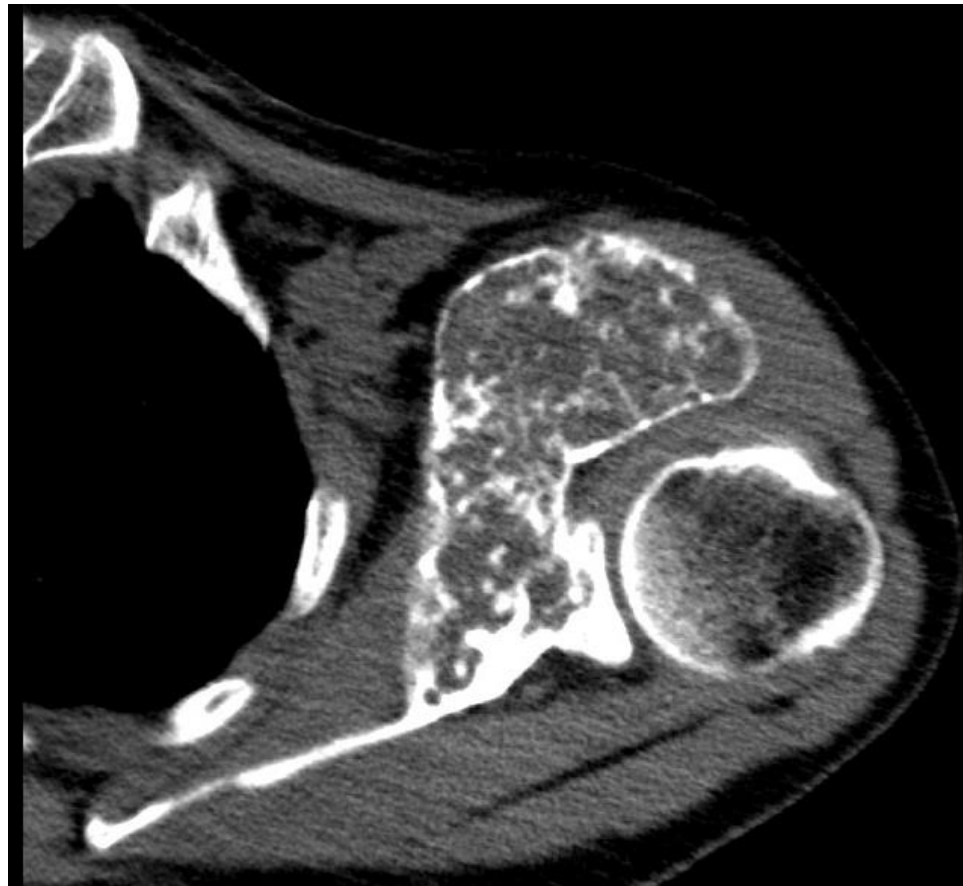X-ray : partially lytic, partially sclerotic, sharply delimited tumor (11.5x5.6cm) ventral scapula



Scapula; 3D precision partial resection

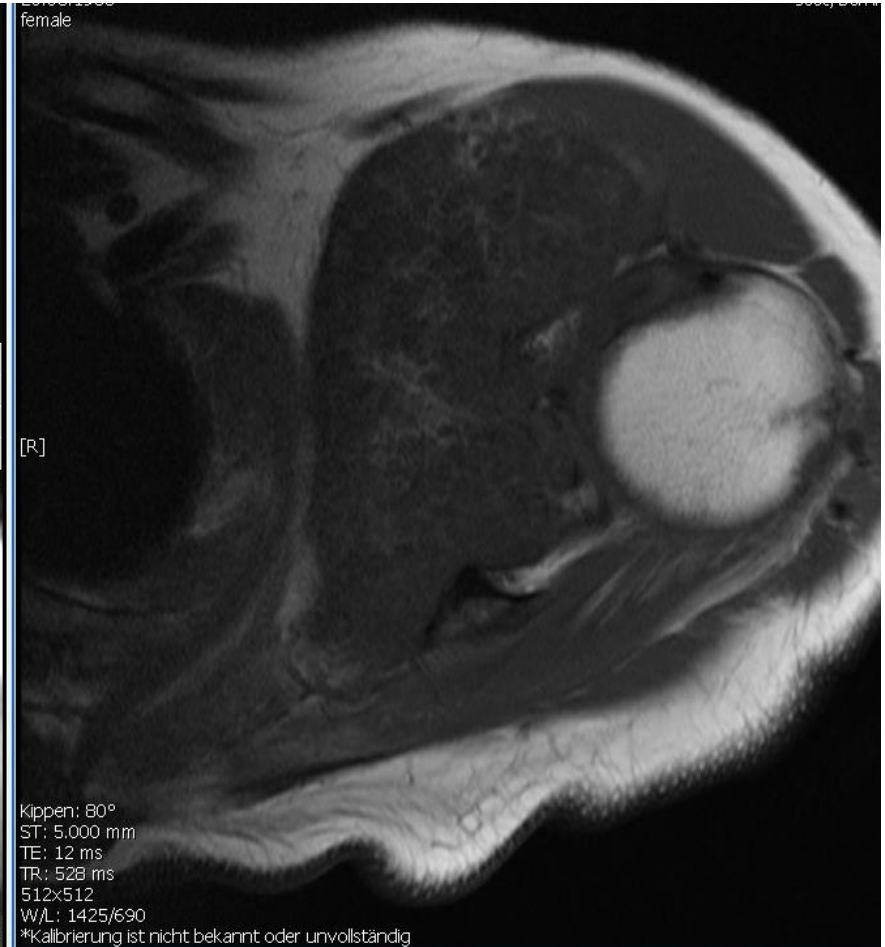
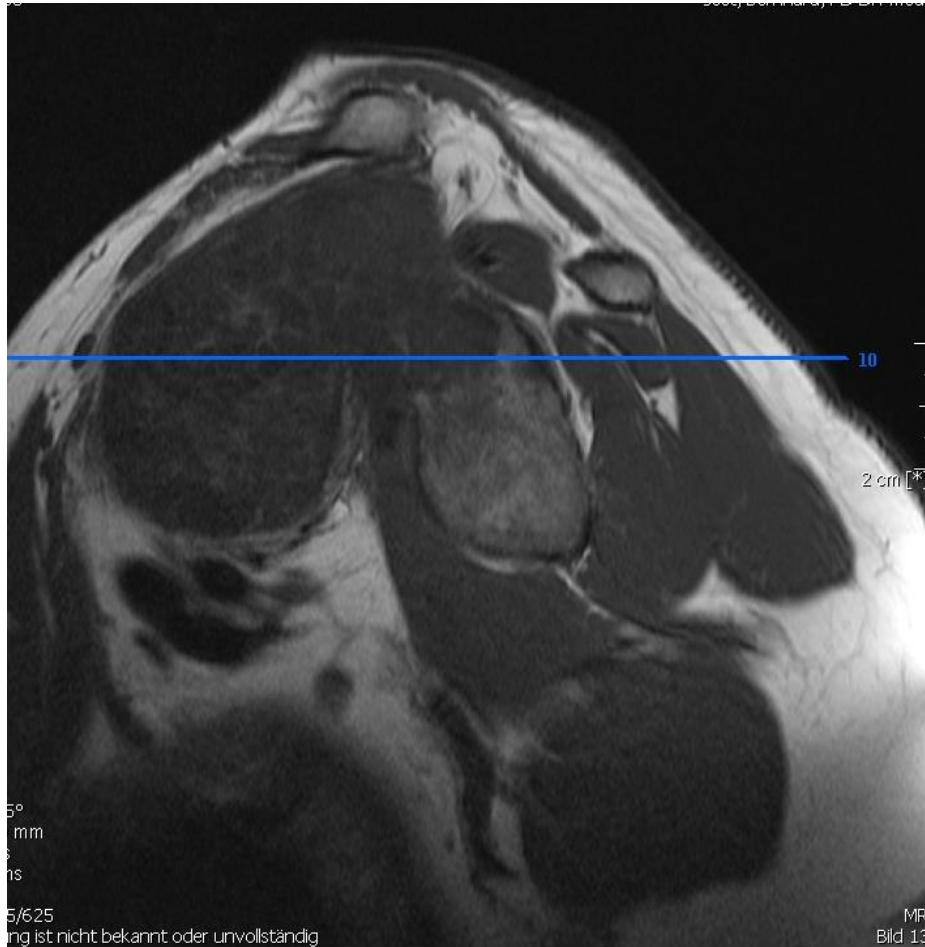
Oct 13, 2006

CT : partially lytic, partially sclerotic tumor based on ventral glenoid (coracoid)



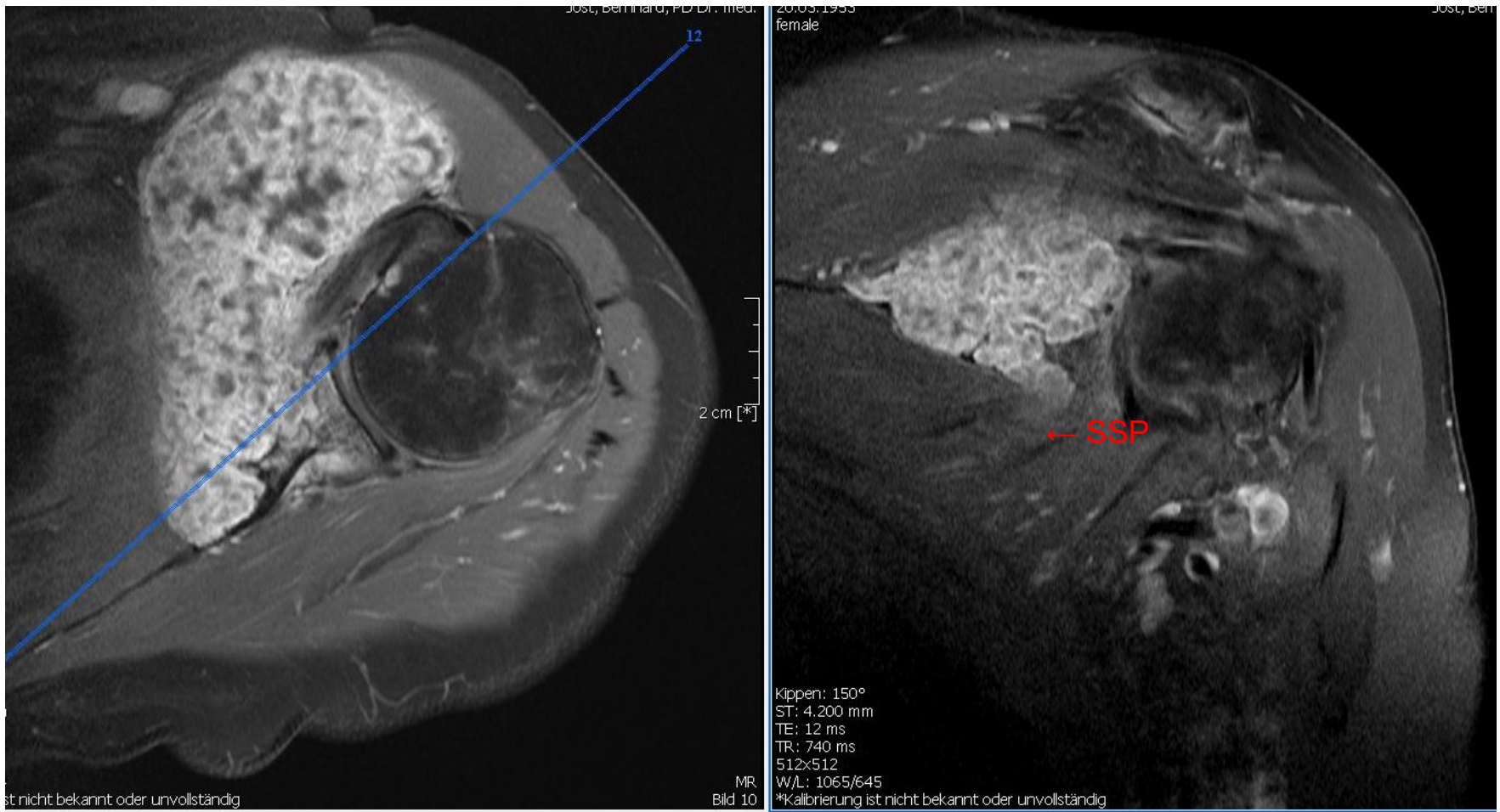
Scapula; 3D precision partial resection

Apr 25, 2007



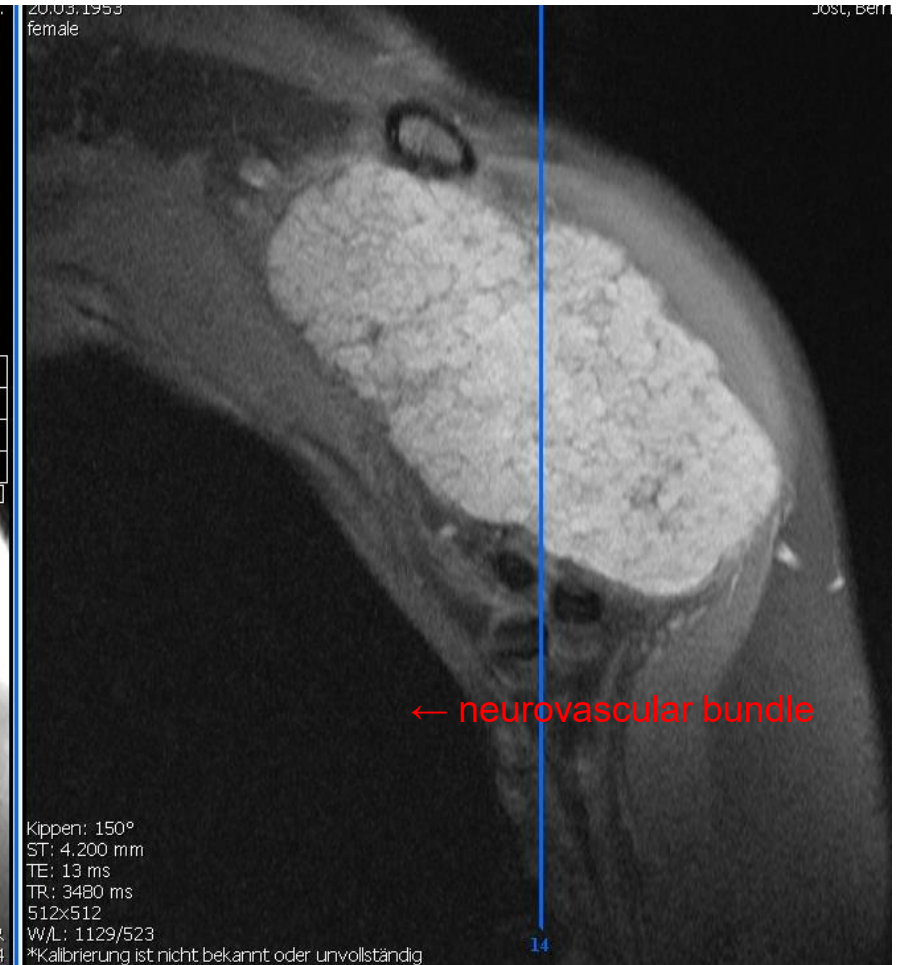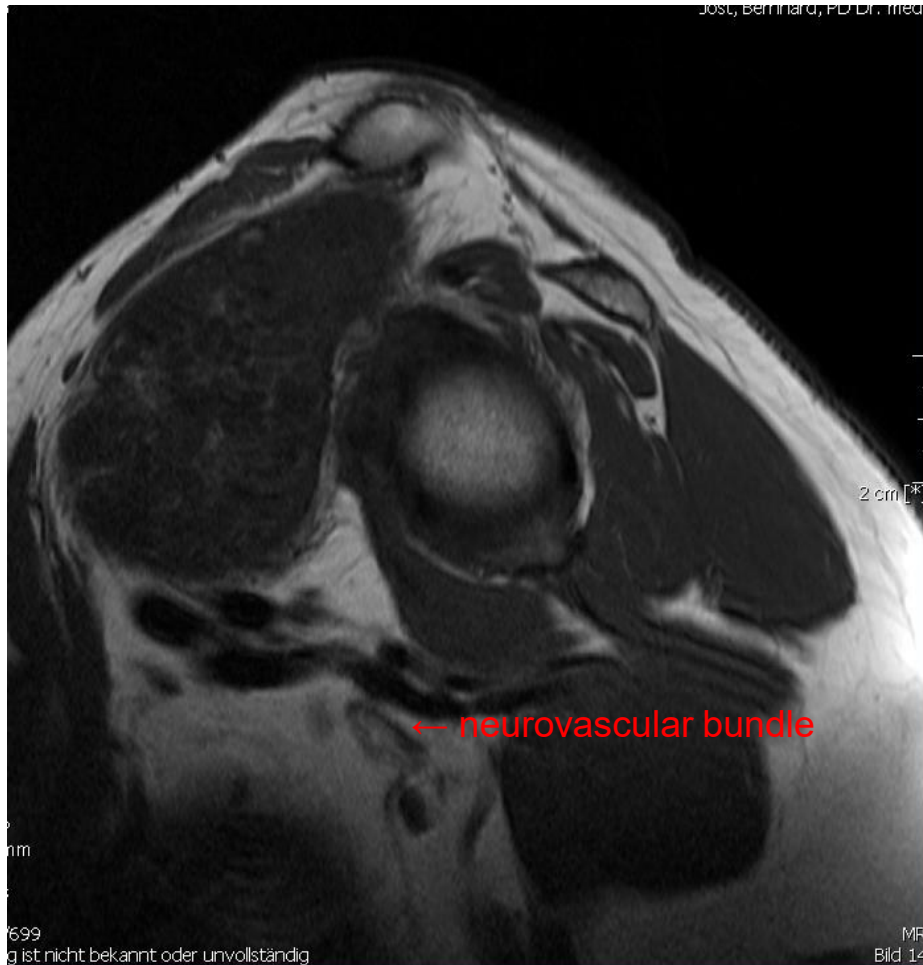
Scapula; 3D precision partial resection

Apr 25, 2007



Scapula; 3D precision partial resection

Apr 25, 2007



Scapula; 3D precision partial resection

Apr 26, 2007

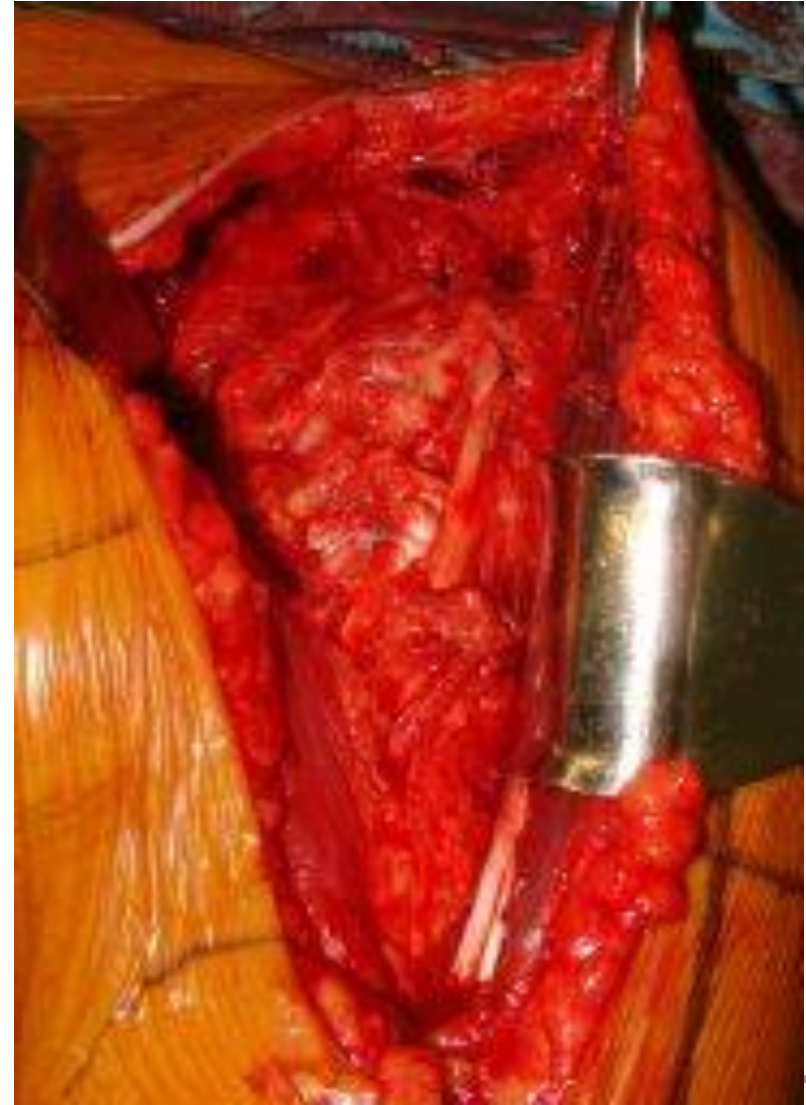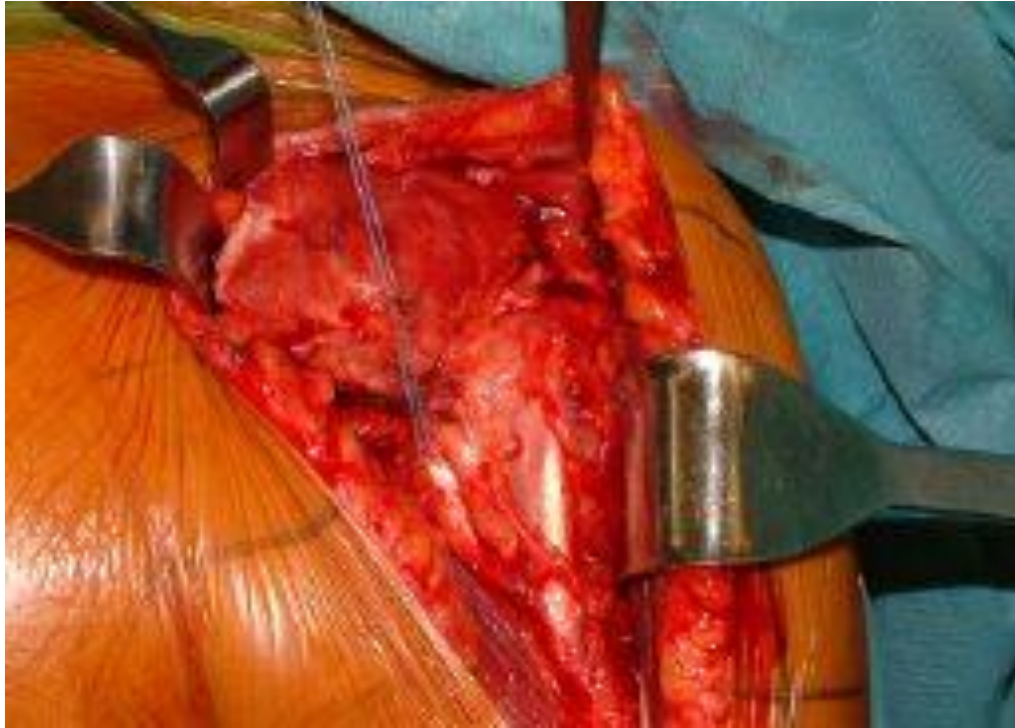Huge osteochondroma with mechanical symptoms



**Decision for operative resection
(osteochondroma resection, tenodesis of long biceps in sulcus, tenodesis coracobiceps on anterior humeral metaphysis)**

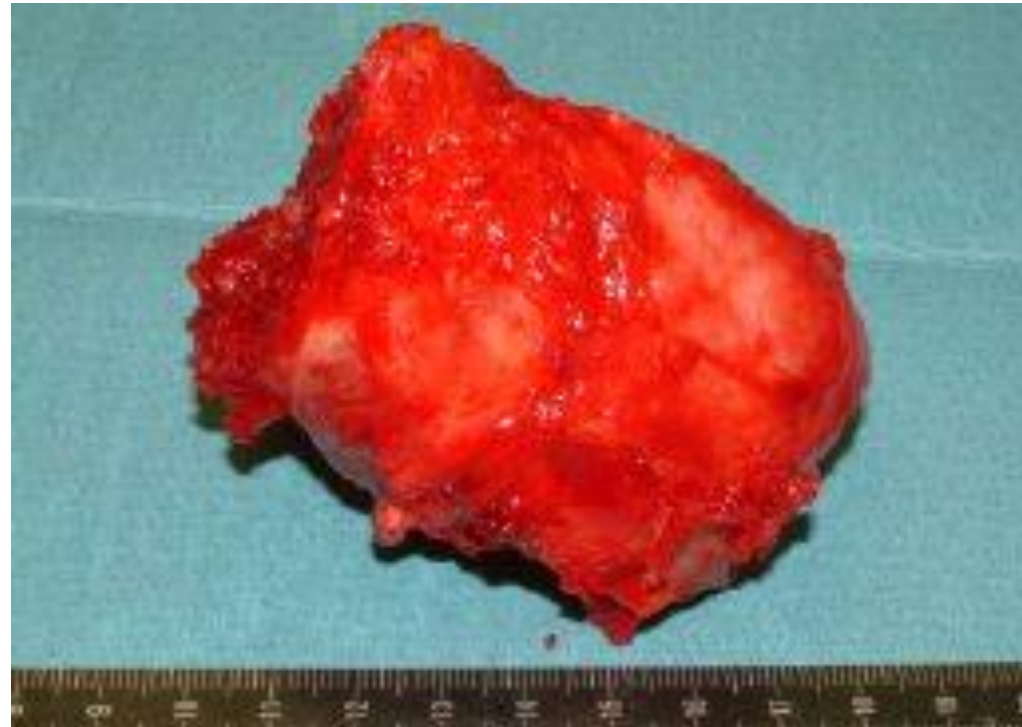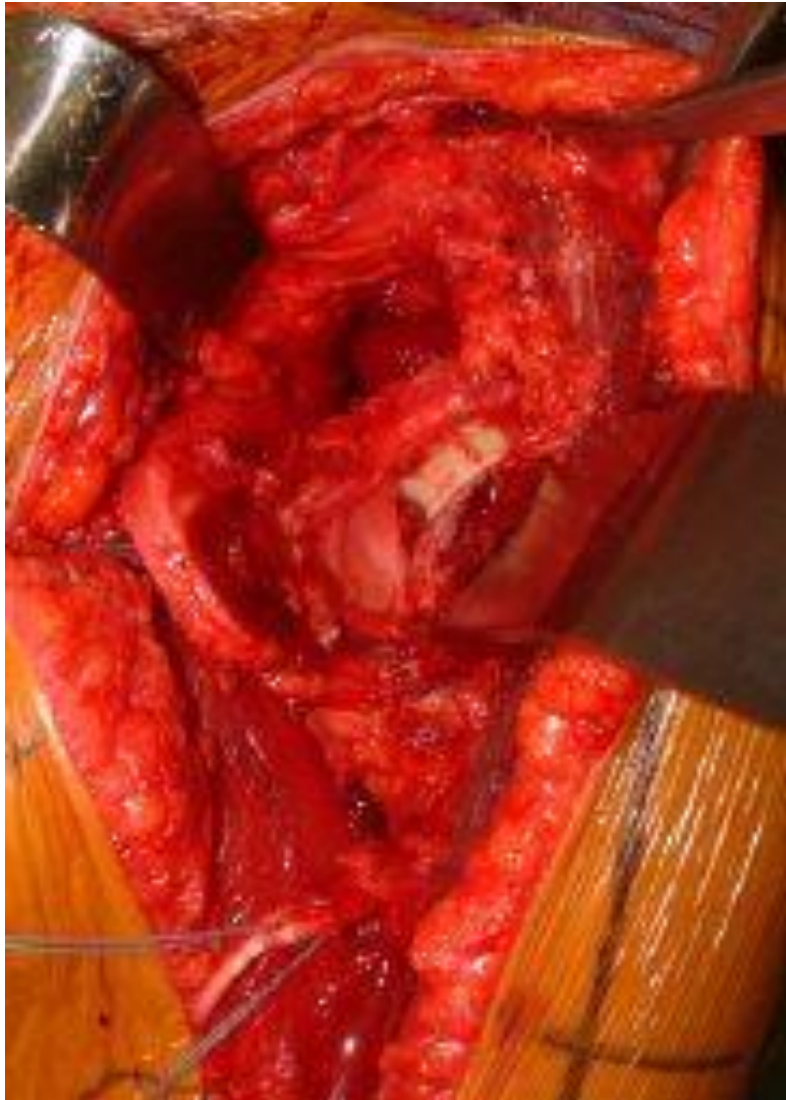Scapula; 3D precision partial resection

Apr 26, 2007



Scapula; 3D precision partial resection

Apr 26, 2007



Scapula; 3D precision partial resection

Histology : USZ B2007:

Osteochondroma with parts of low-grade chondrosarcoma

Scapula; 3D precision partial resection

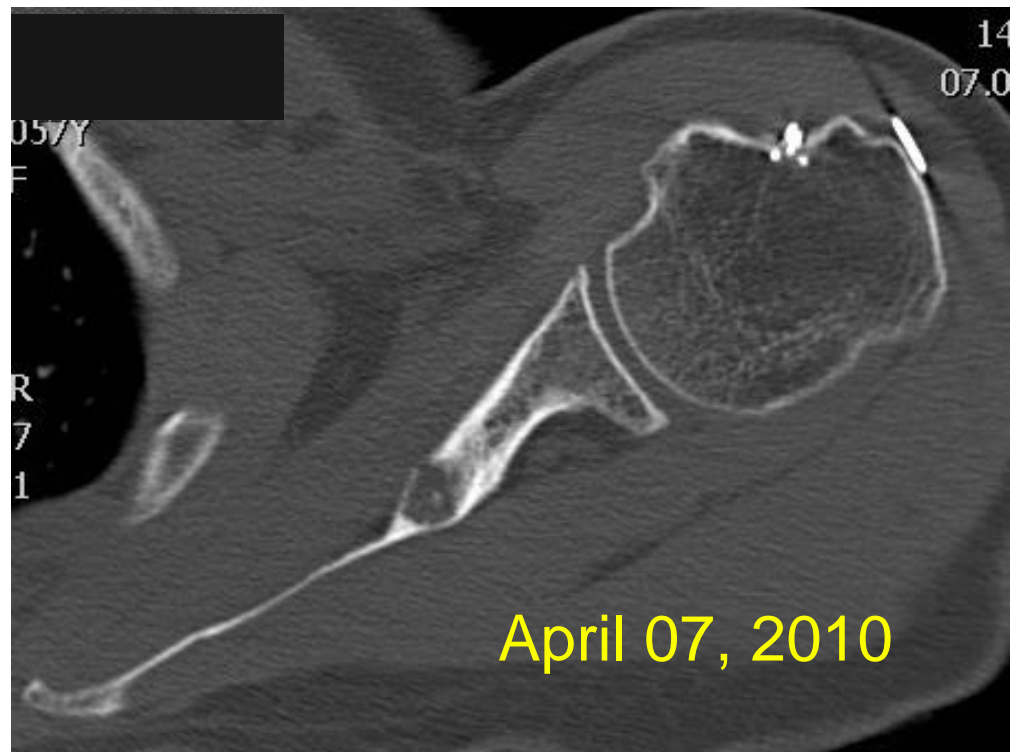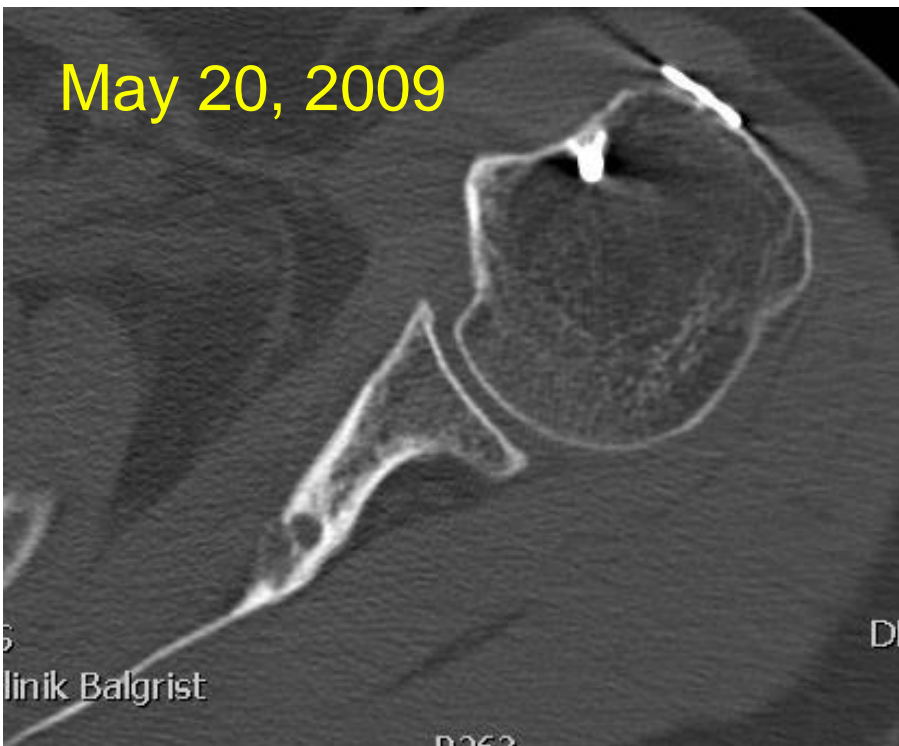
Current situation 2009:

After 2 y FU : good functional result, no pain

No local relapse, no metastasis (CT shoulder and CT thorax every 6 months)

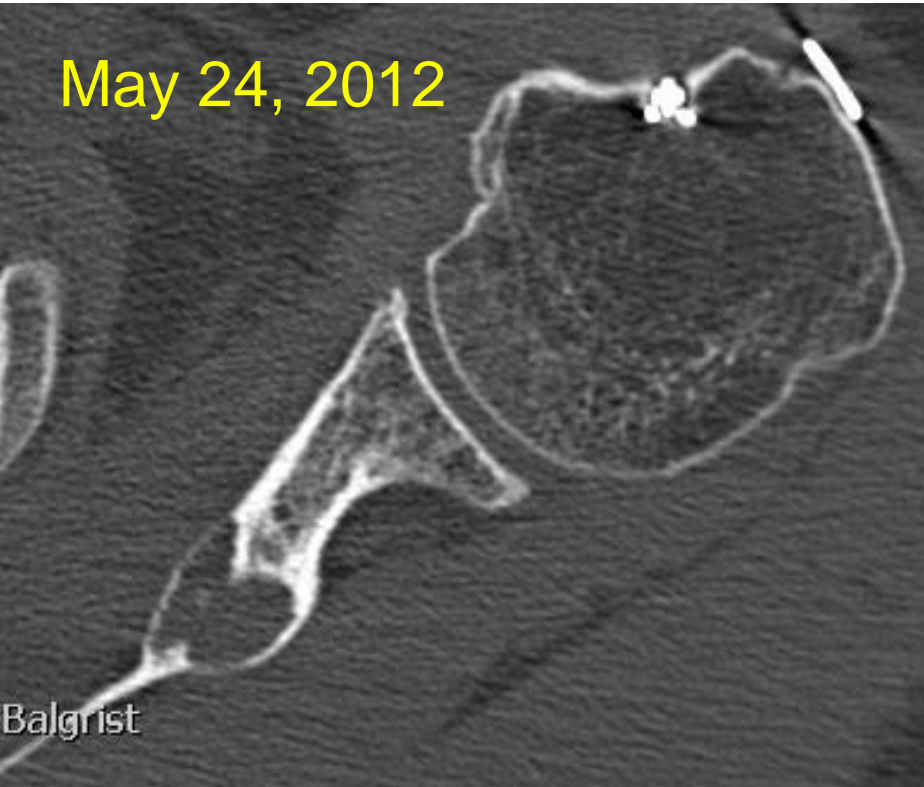Scapula; 3D precision partial resection

May 20, 2009

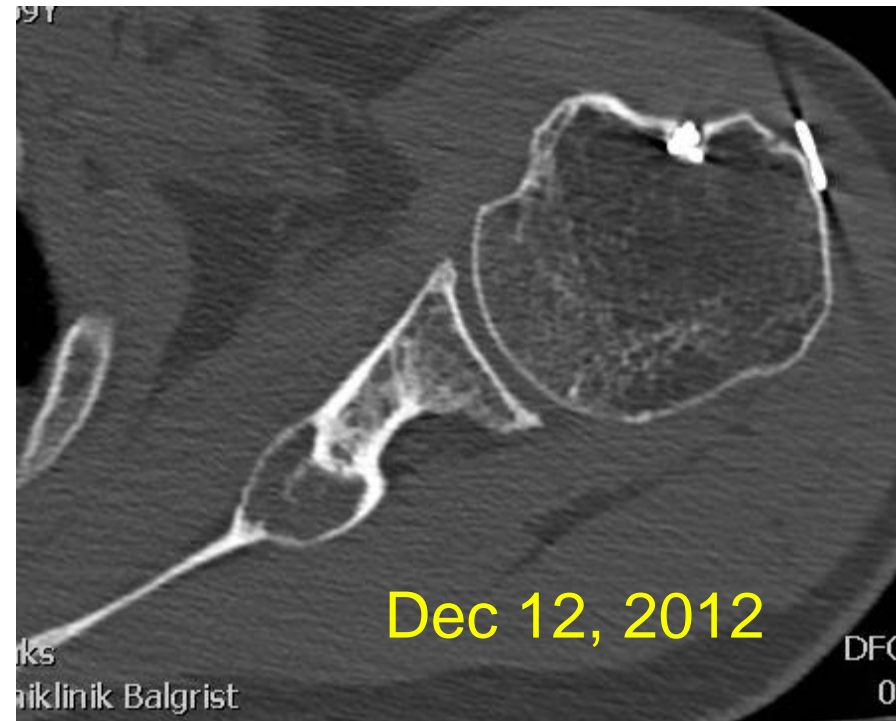

Scapula; 3D precision partial resection

May 24, 2012

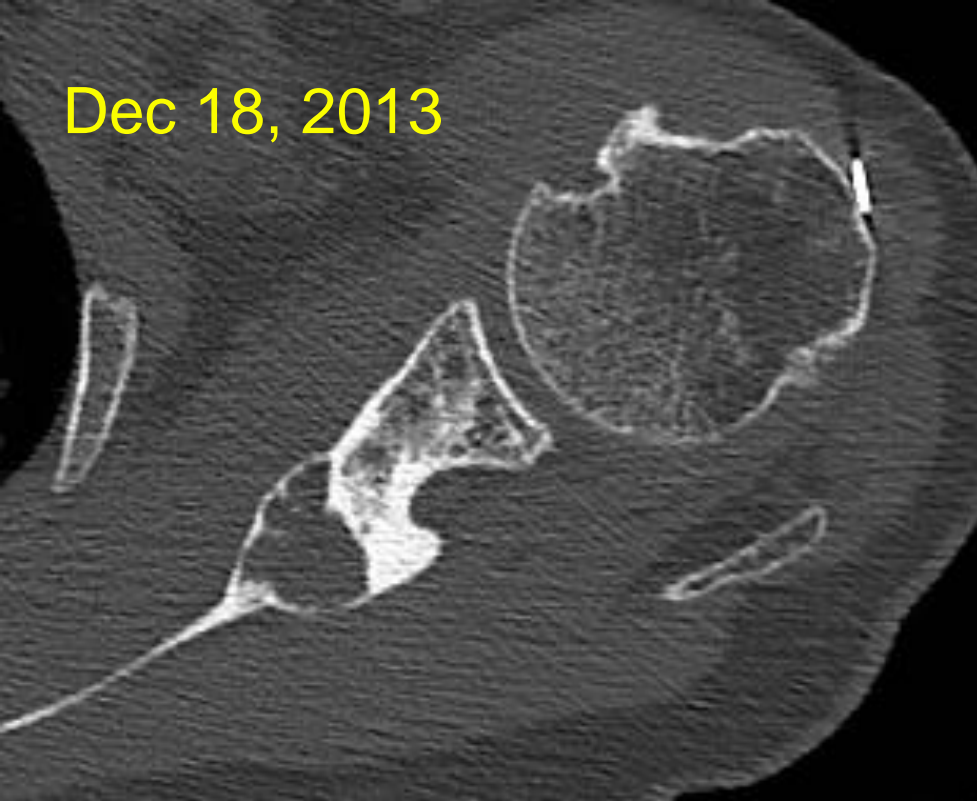


Dec 12, 2012

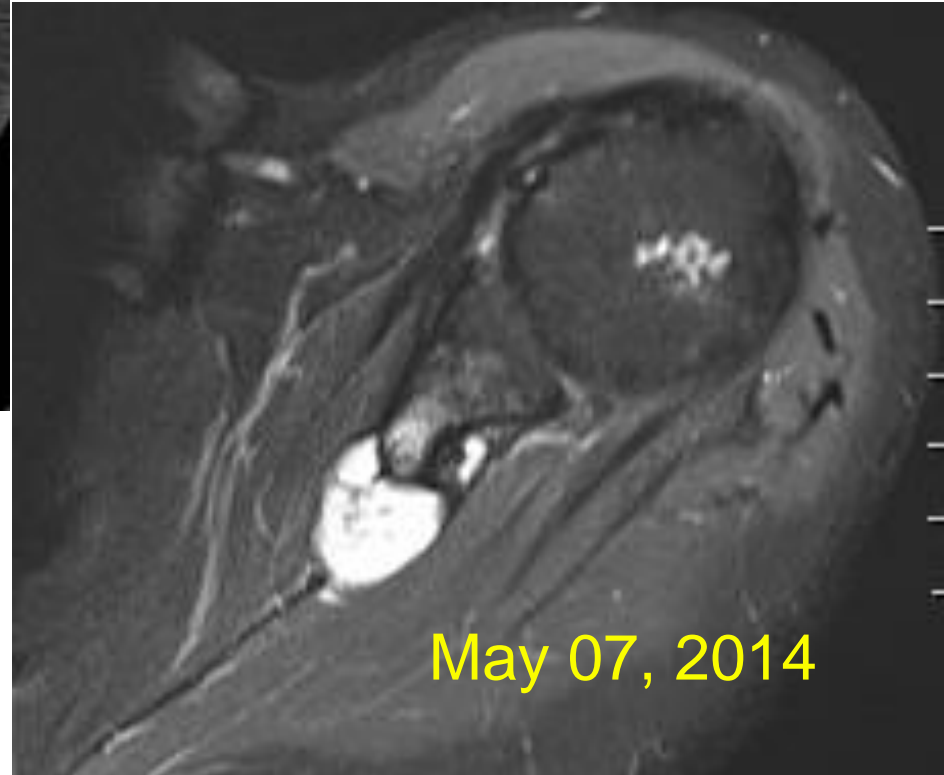


Scapula; 3D precision partial resection

Dec 18, 2013

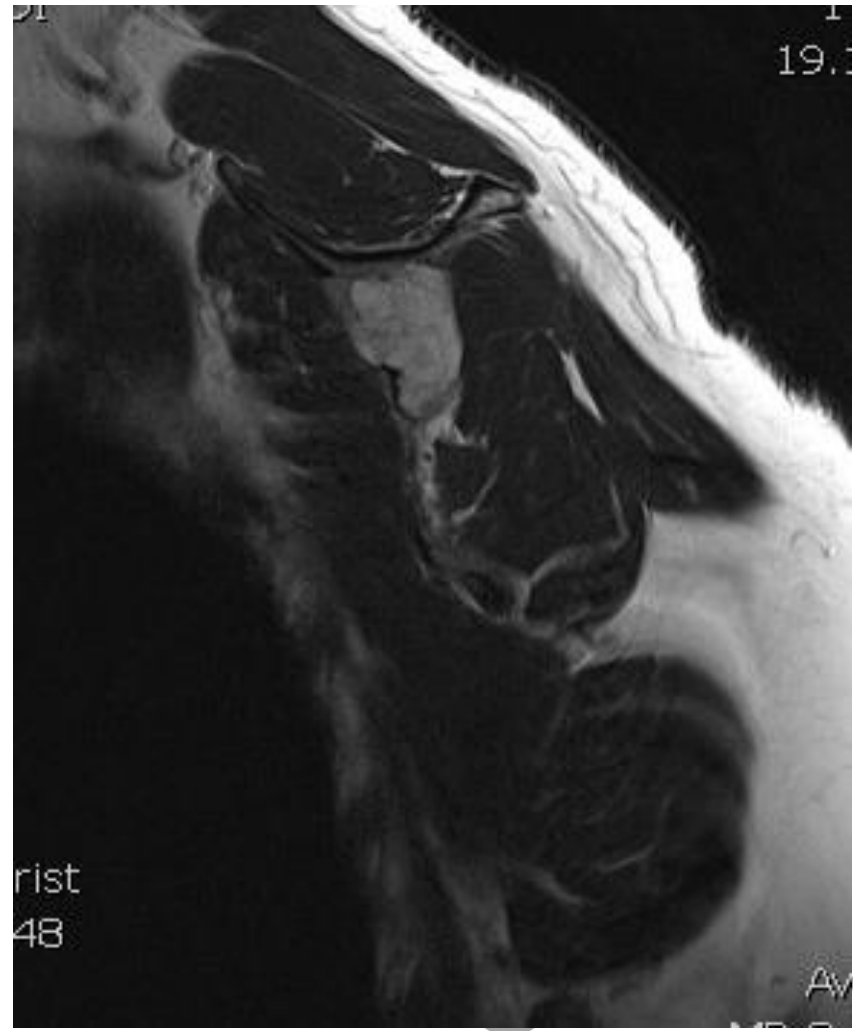
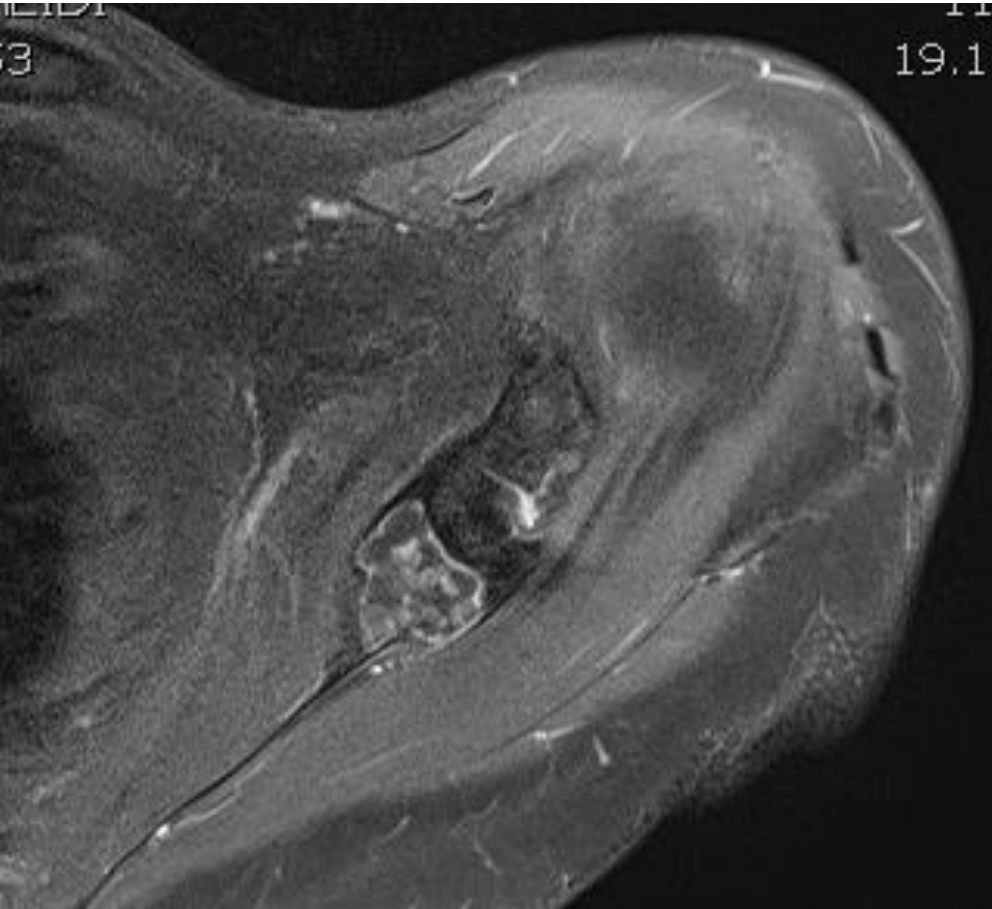


May 07, 2014



Scapula; 3D precision partial resection

Nov 19, 2014



Scapula; 3D precision partial resection

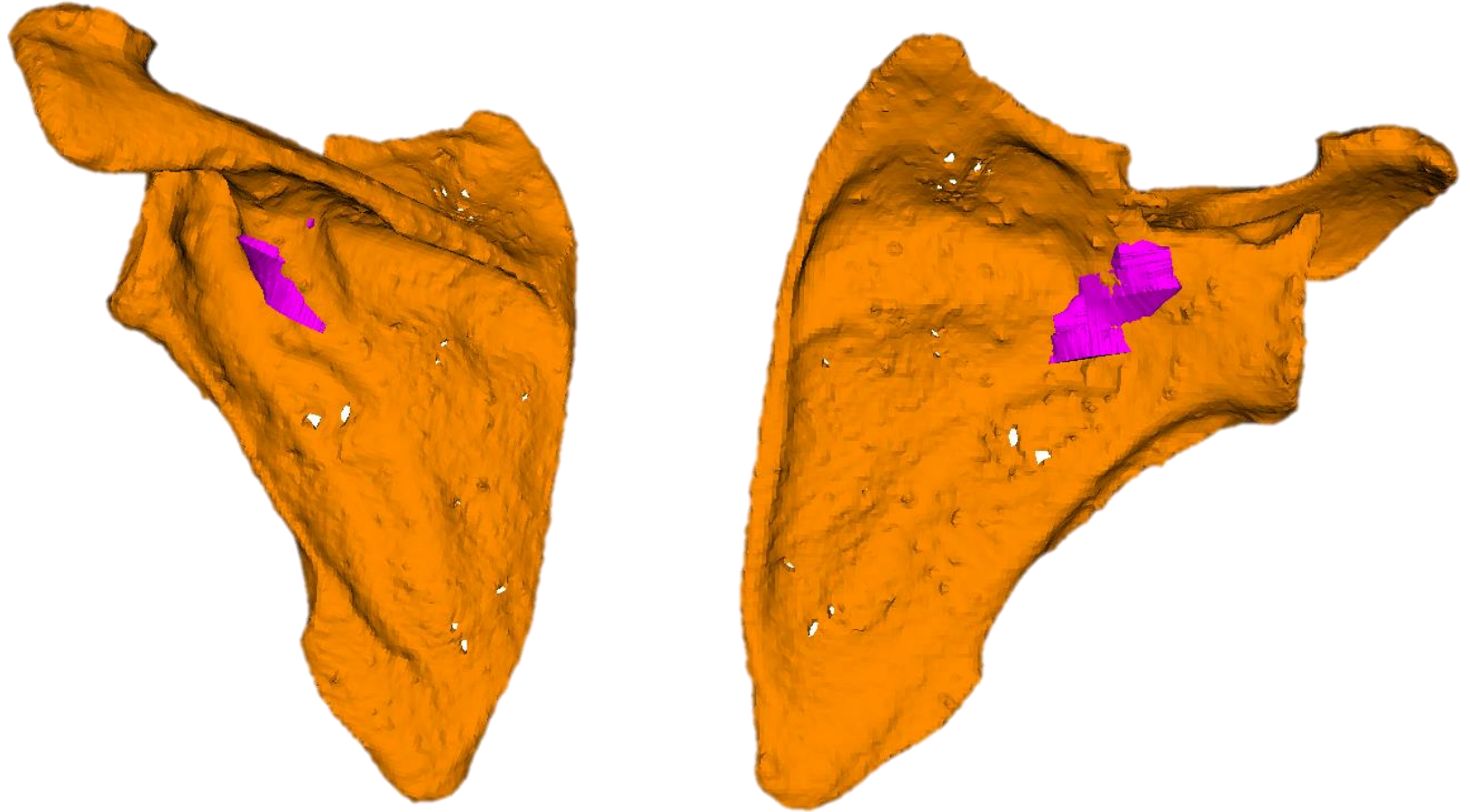
Nov 29, 2014

**Chondrogenic low grade tumor,
progressive:**

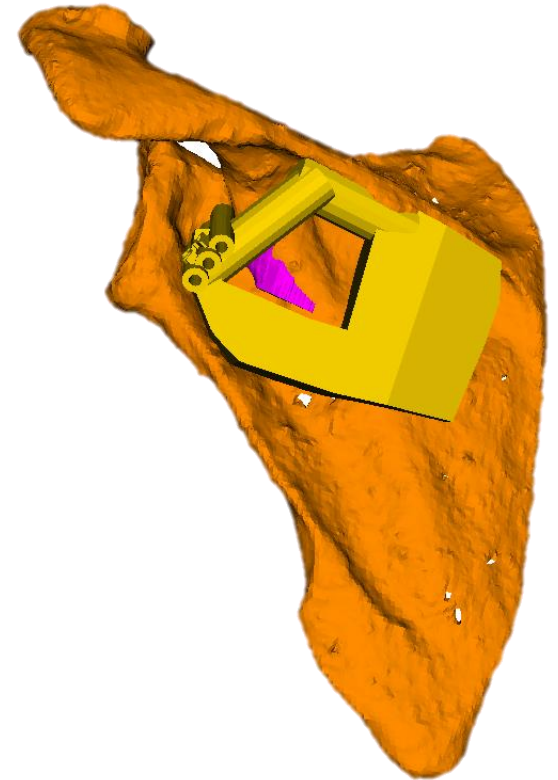
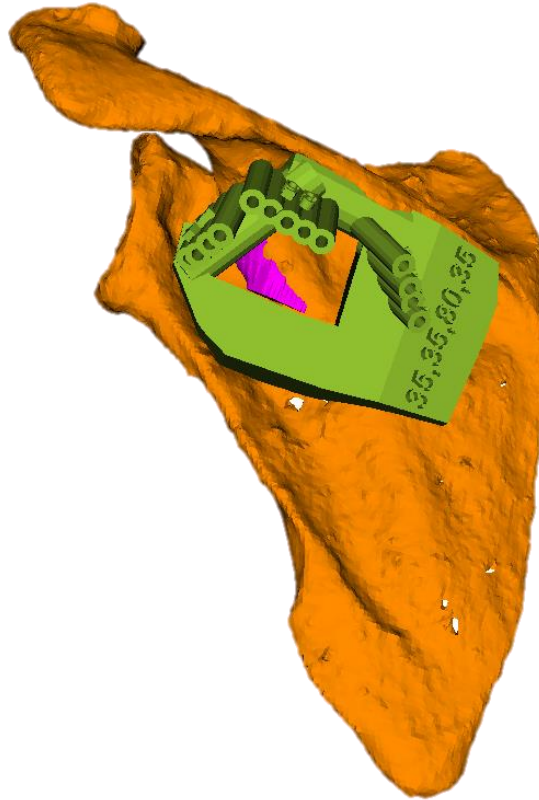
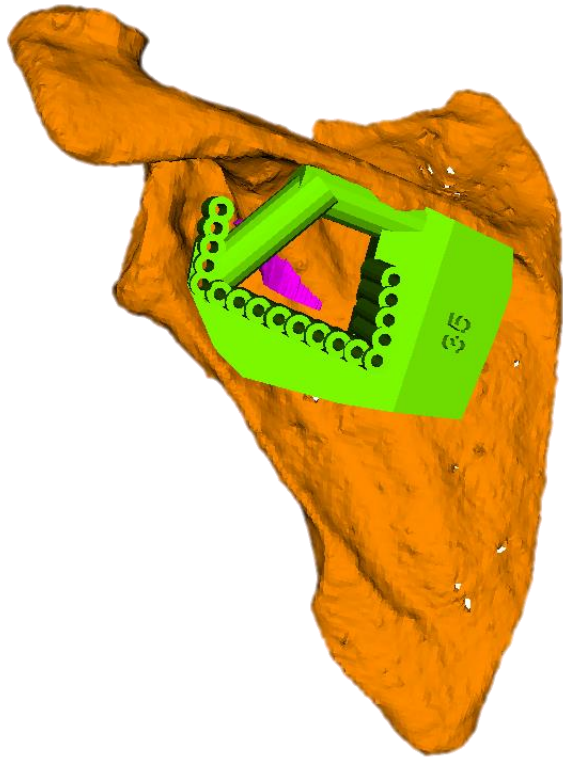
Curretage?

Glenoid resection?

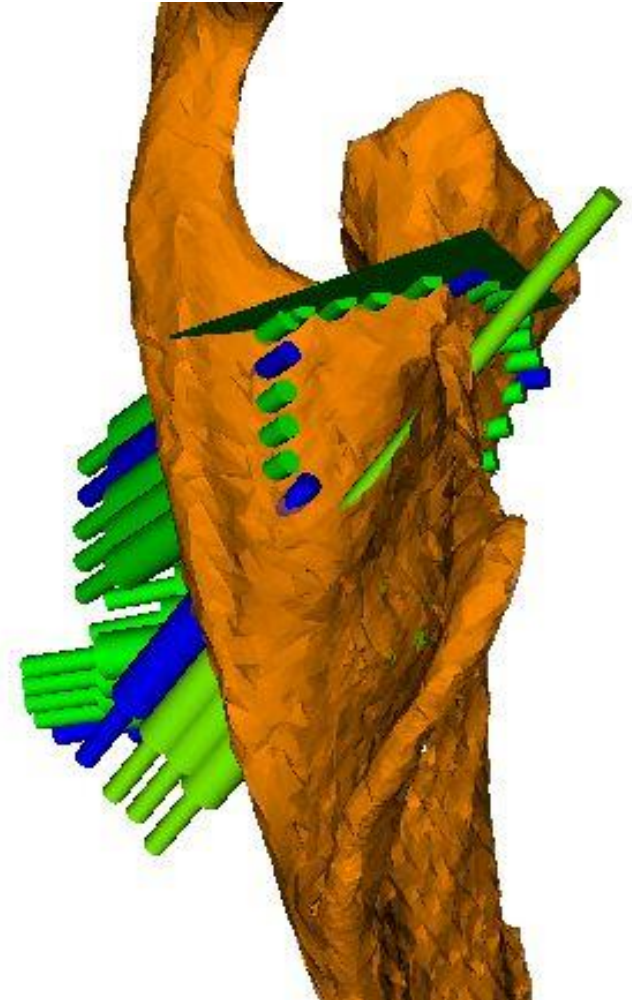
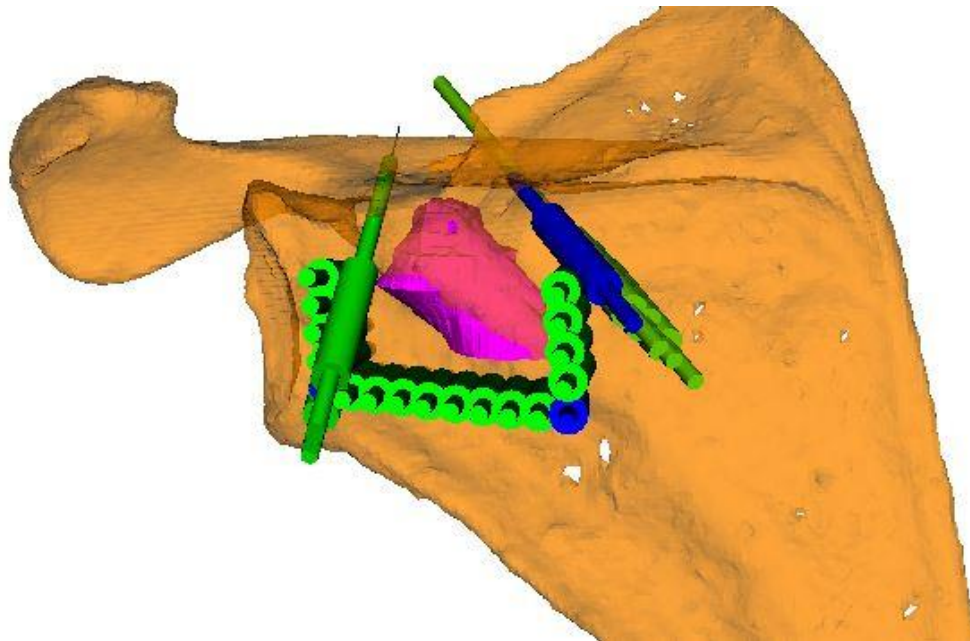
Scapula; 3D precision partial resection CARD planning surgery April 07, 2015



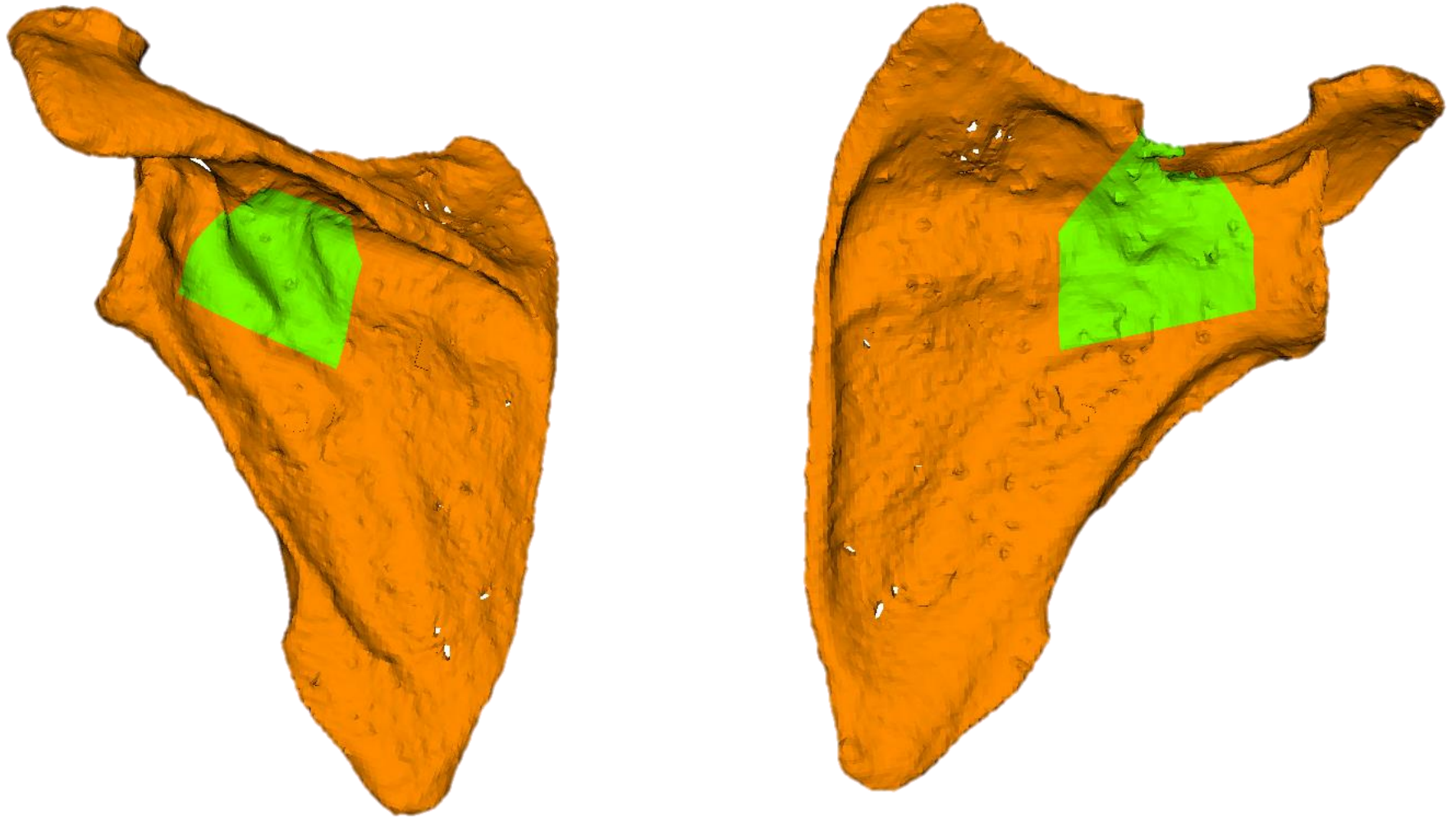
Scapula; 3D precision partial resection CARD planning surgery April 07, 2015



Scapula; 3D precision partial resection CARD planning surgery April 07, 2015



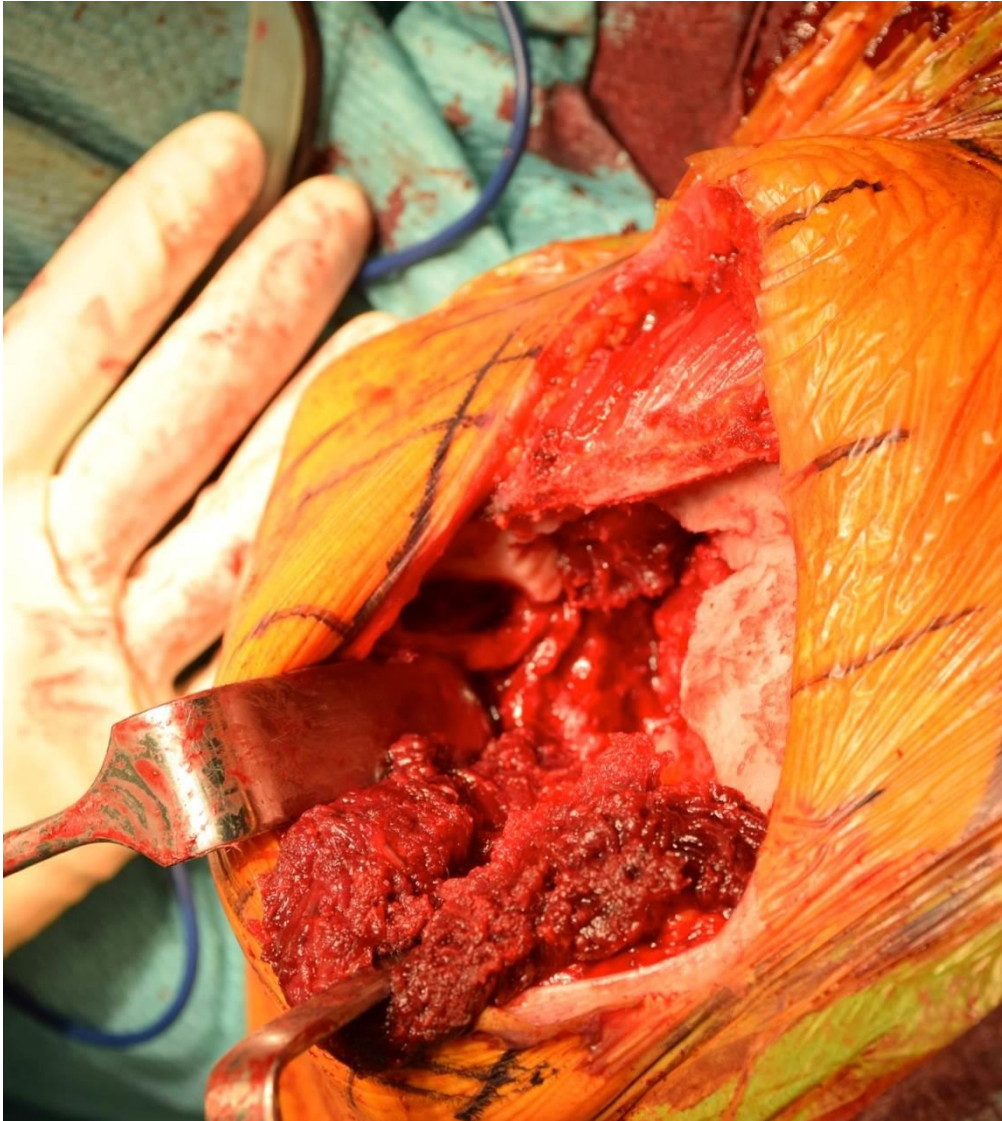Scapula; 3D precision partial resection CARD planning surgery April 07, 2015



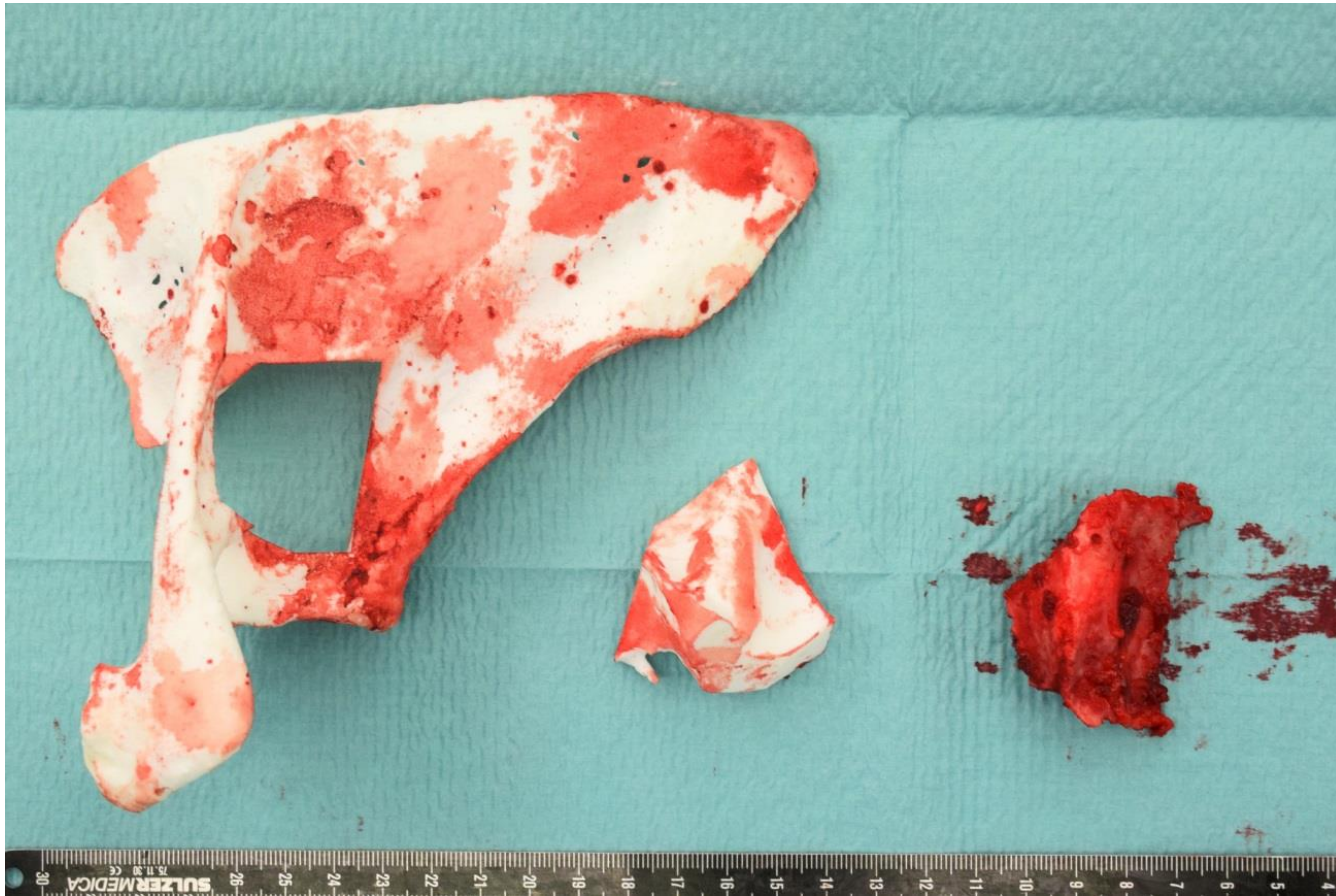
Scapula; 3D precision partial resection CARD planning surgery April 07, 2015

3D print out itself

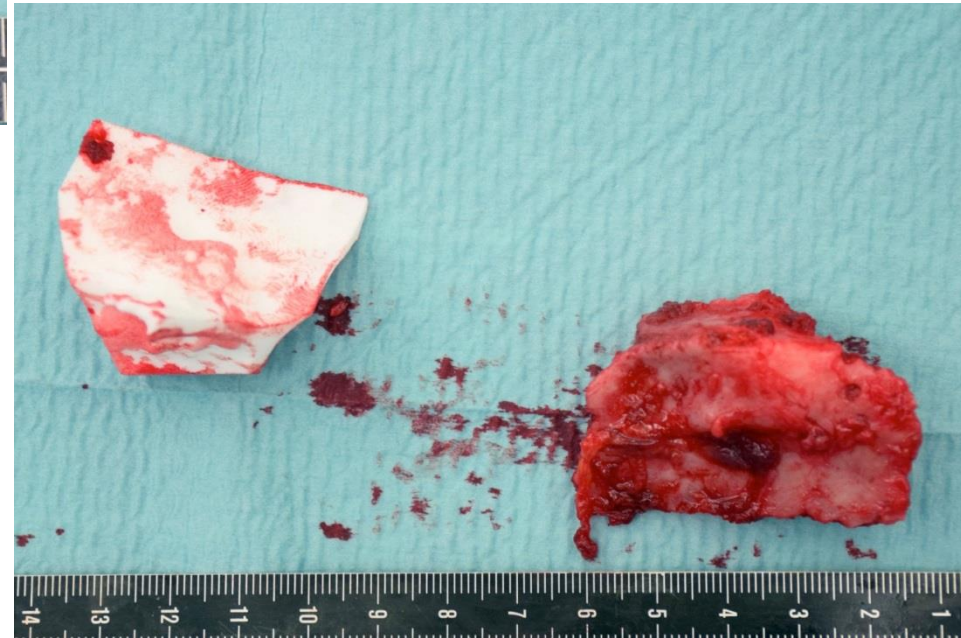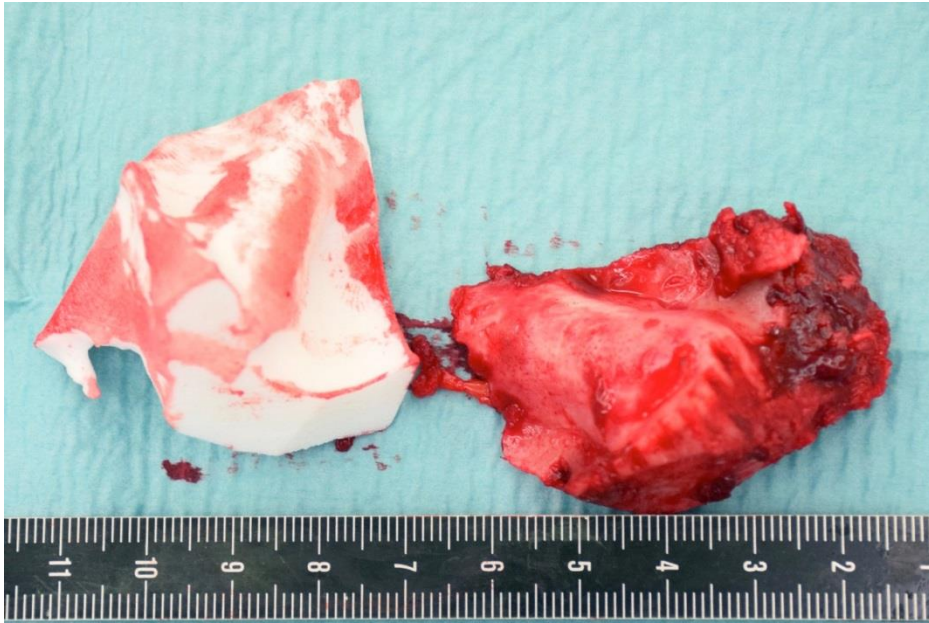
Scapula; 3D precision partial resection CARD planning surgery April 07, 2015



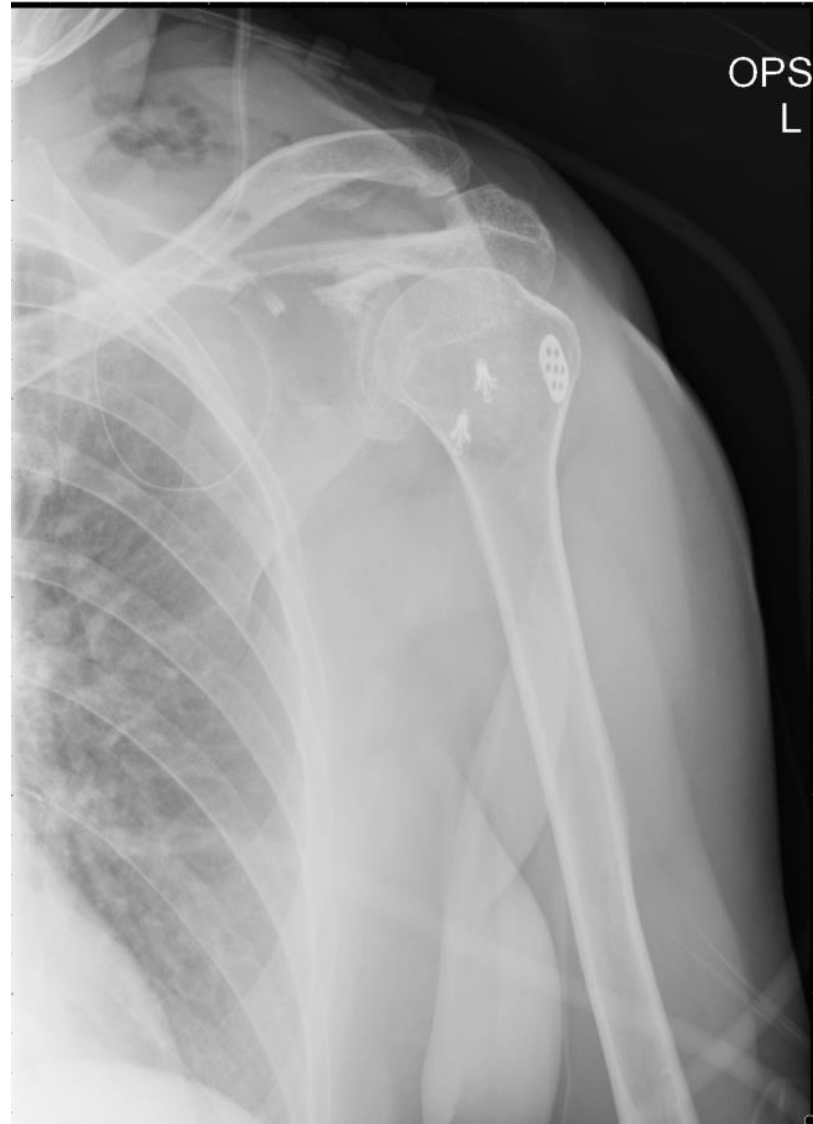Scapula; 3D precision partial resection Intraoperative control



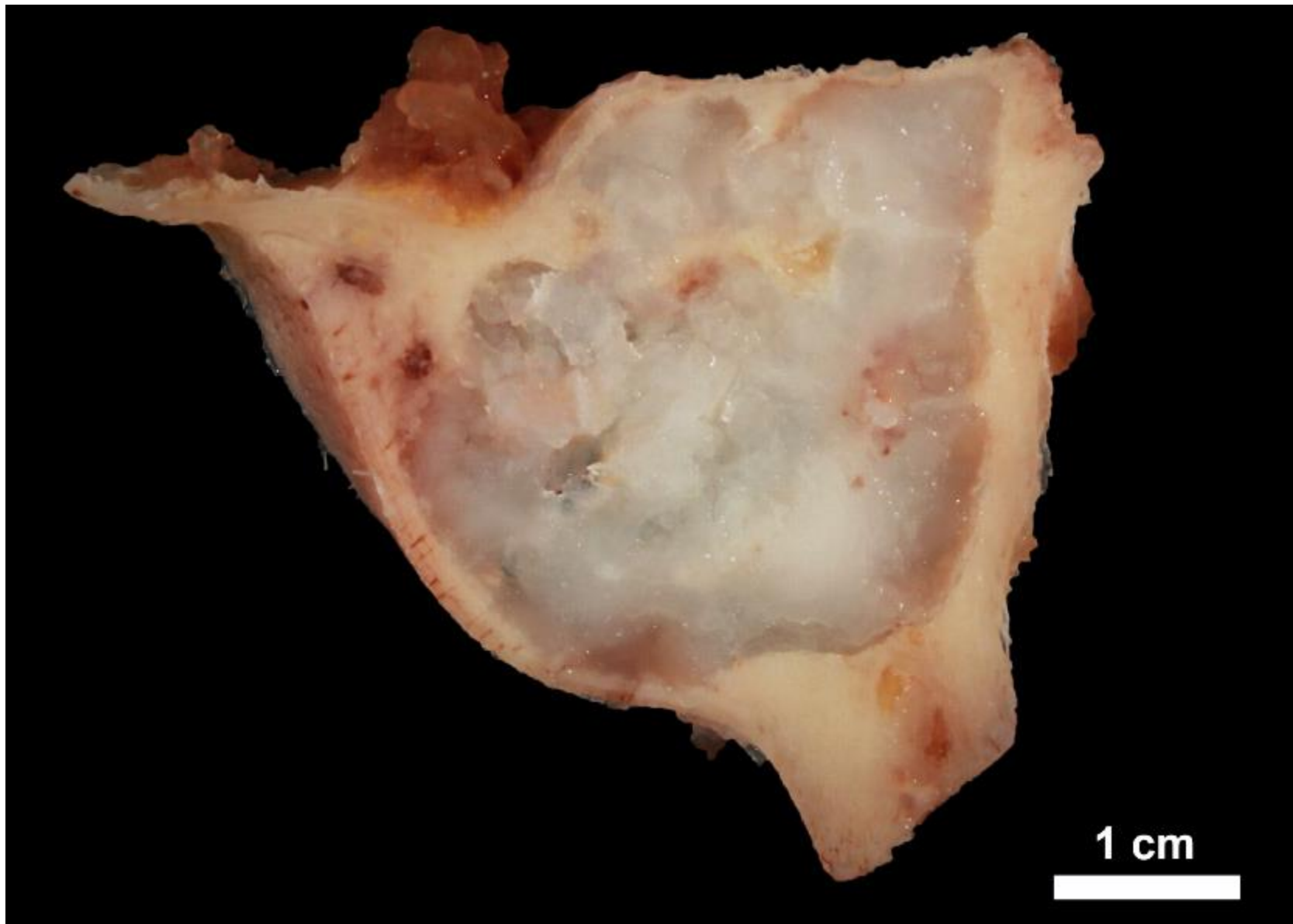
Scapula; 3D precision partial resection CARD planning surgery April 07, 2015



Scapula; 3D precision partial resection postOP Xray April 07, 2015



Scapula; 3D precision partial resection Pathology, April 7th 2015



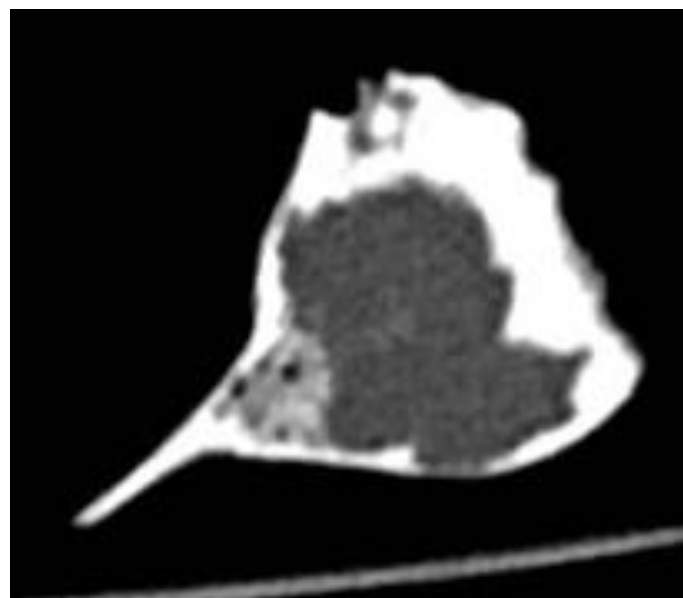
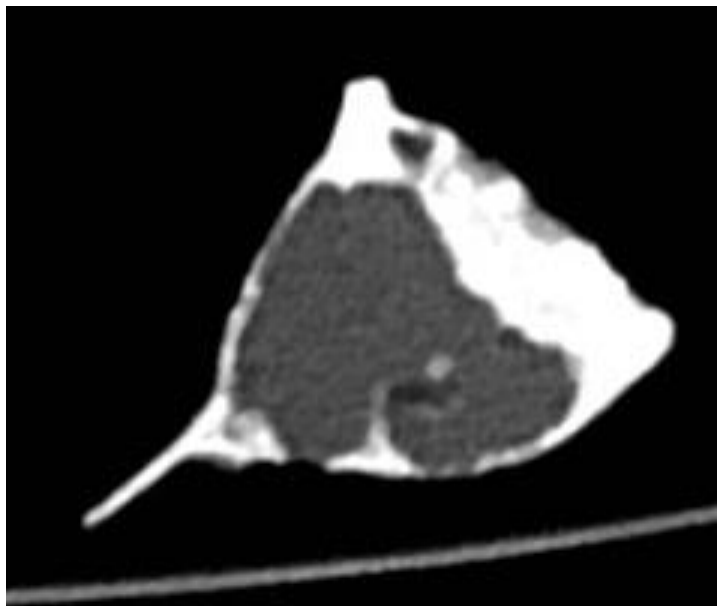
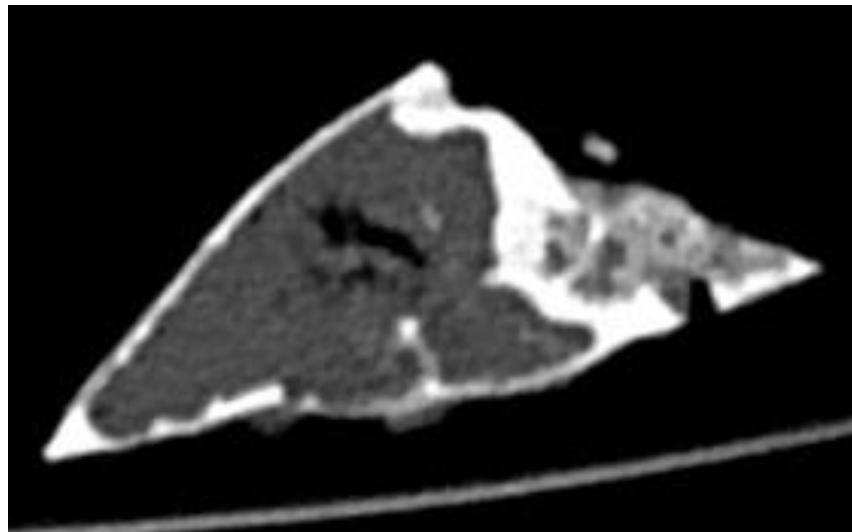
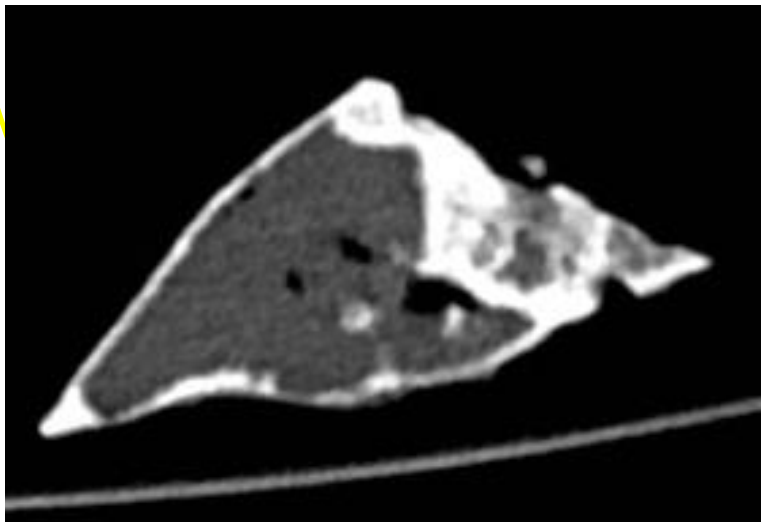
Scapula; 3D precision partial resection Pathology, April 7th 2015

Diagnose

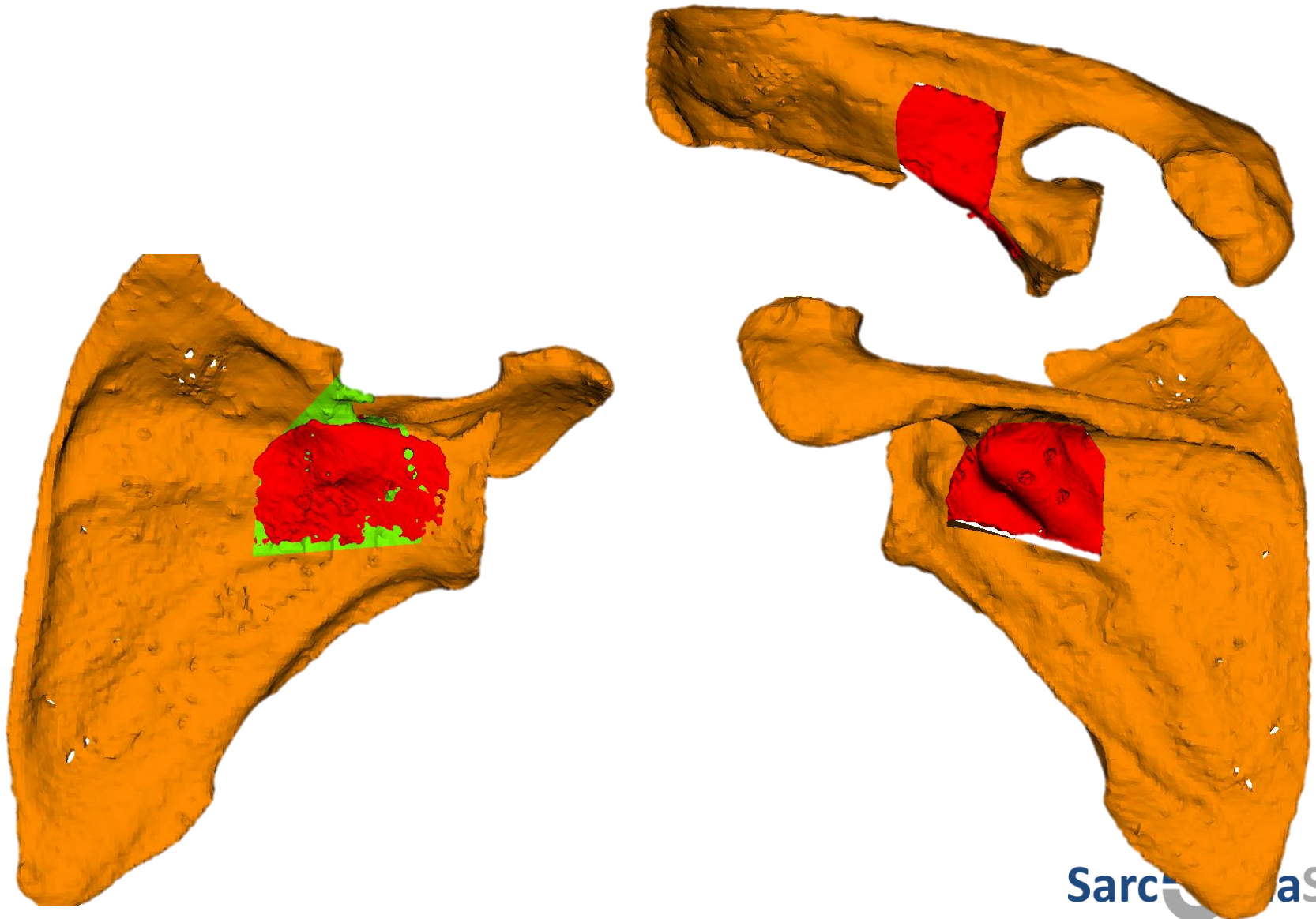
Knochenteilresektat (Skapula links, Glenoidhals) mit ausschliesslich intraossär gelegem Rezidiv des vordiagnostizierten (vgl. B 2007.16220) konventionellen Chondrosarkom (Malignitätsgrad G1), mit einer maximalen Tumorausdehnung von 4.2 cm. Keine Infiltration/ kein Durchbruch der Kortikalis.

Resektion im Gesunden.

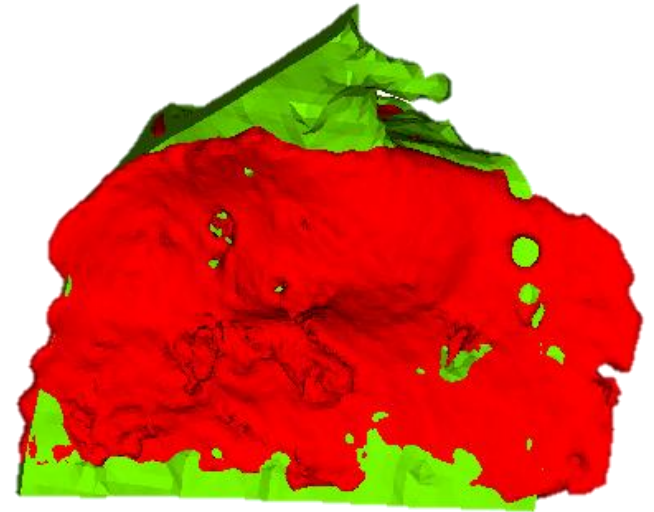
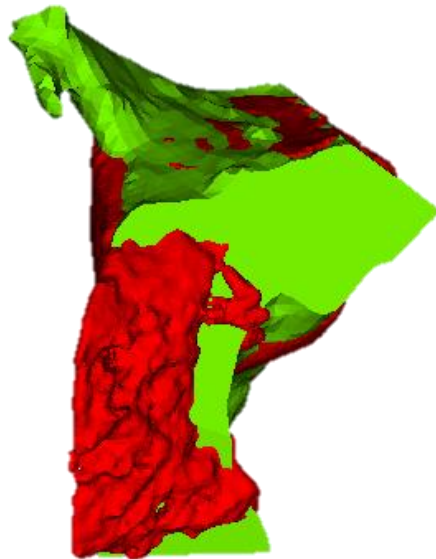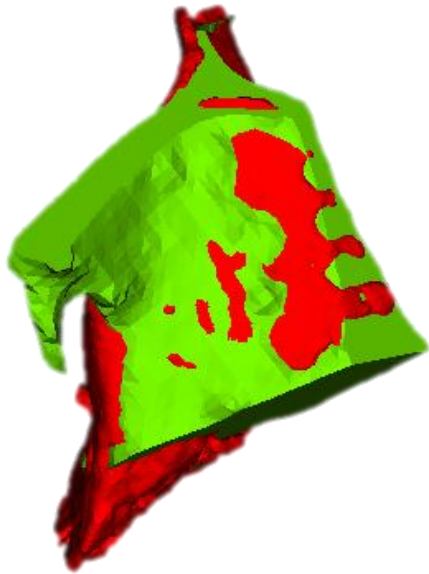
Scapula; 3D precision partial resection surgery April 07, 2015



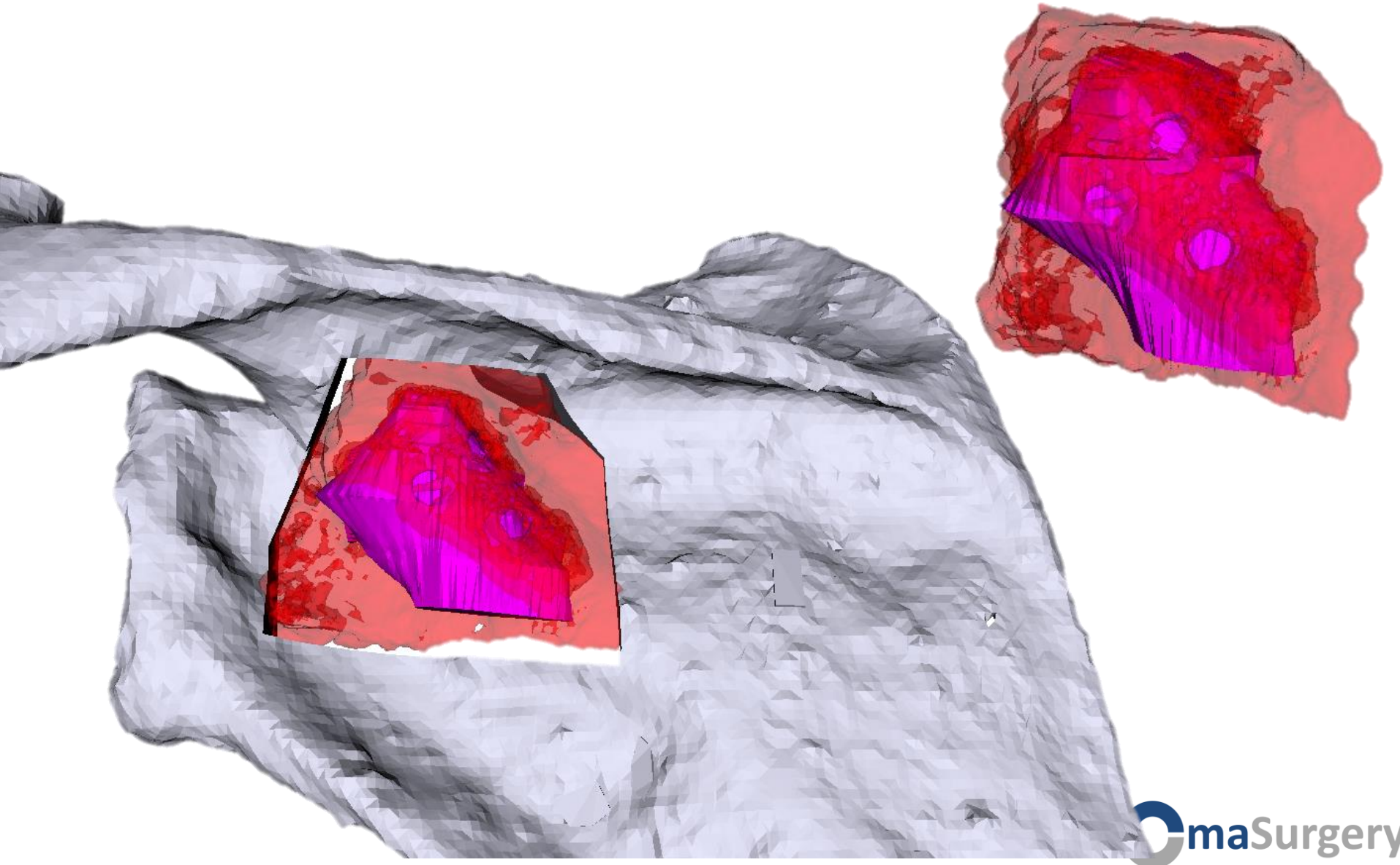
Scapula; 3D precision partial resection CARD comparison April 07, 2015



Scapula; 3D precision partial resection CARD comparison April 07, 2015



Scapula; 3D precision partial resection CARD planning surgery April 07, 2015



Scapula; 3D precision partial resection

Fragestellung:

Postoperative Nachbehandlung indiziert?

Therapeutische Entscheidungen:

Systemische Therapie:

Nein

Radiotherapie:

Nein

Hyprosar: Nein

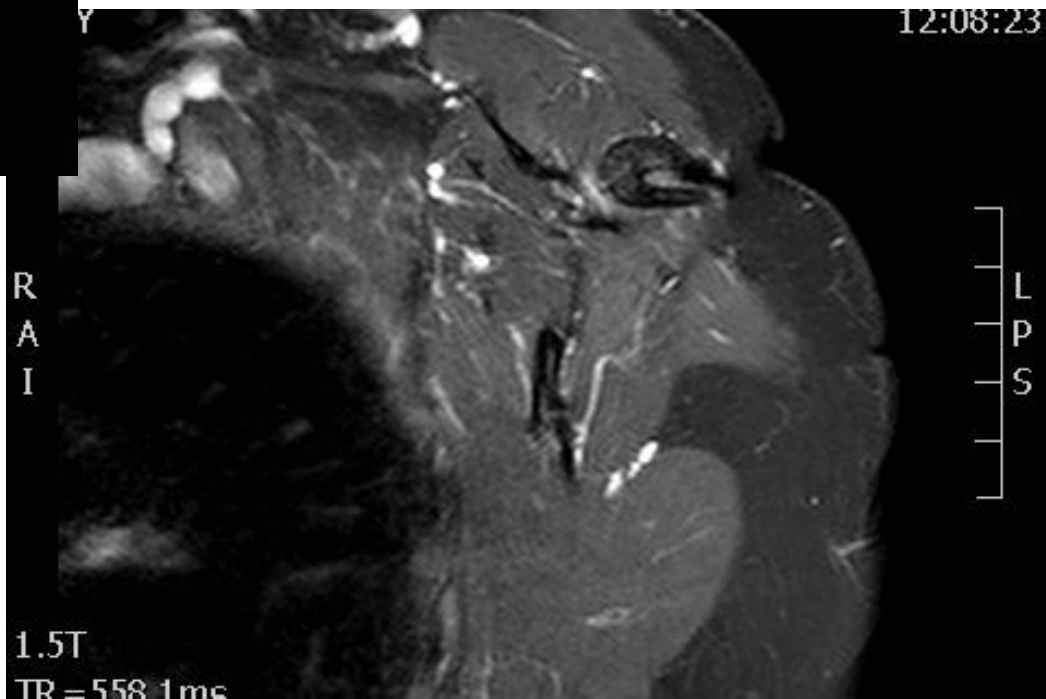
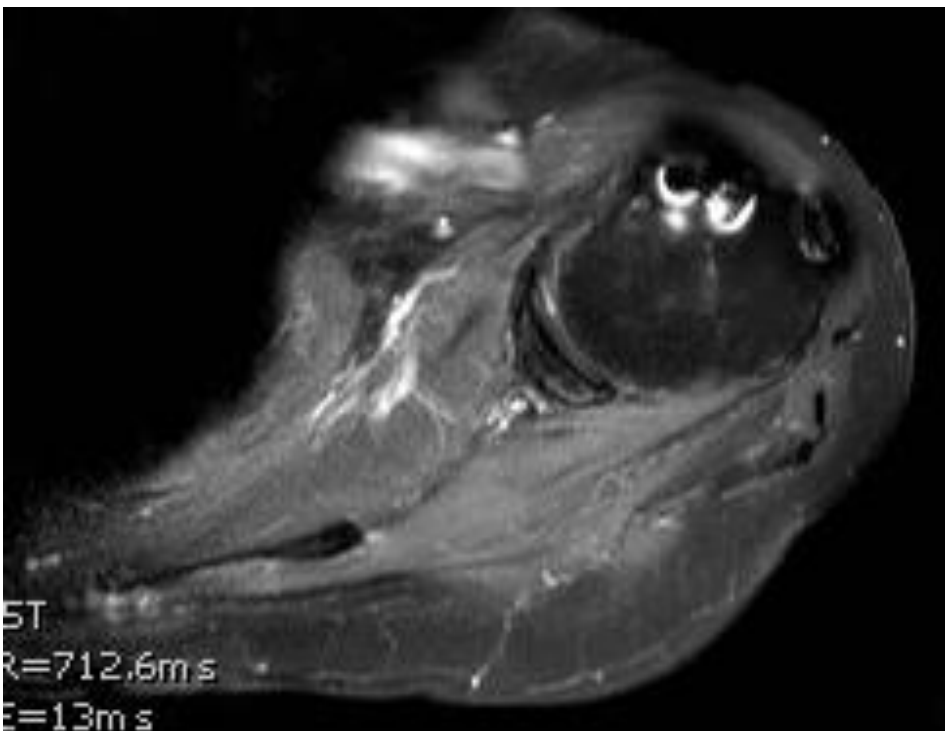
Chirurgie:

Bereits erfolgt

Organisatorisches:

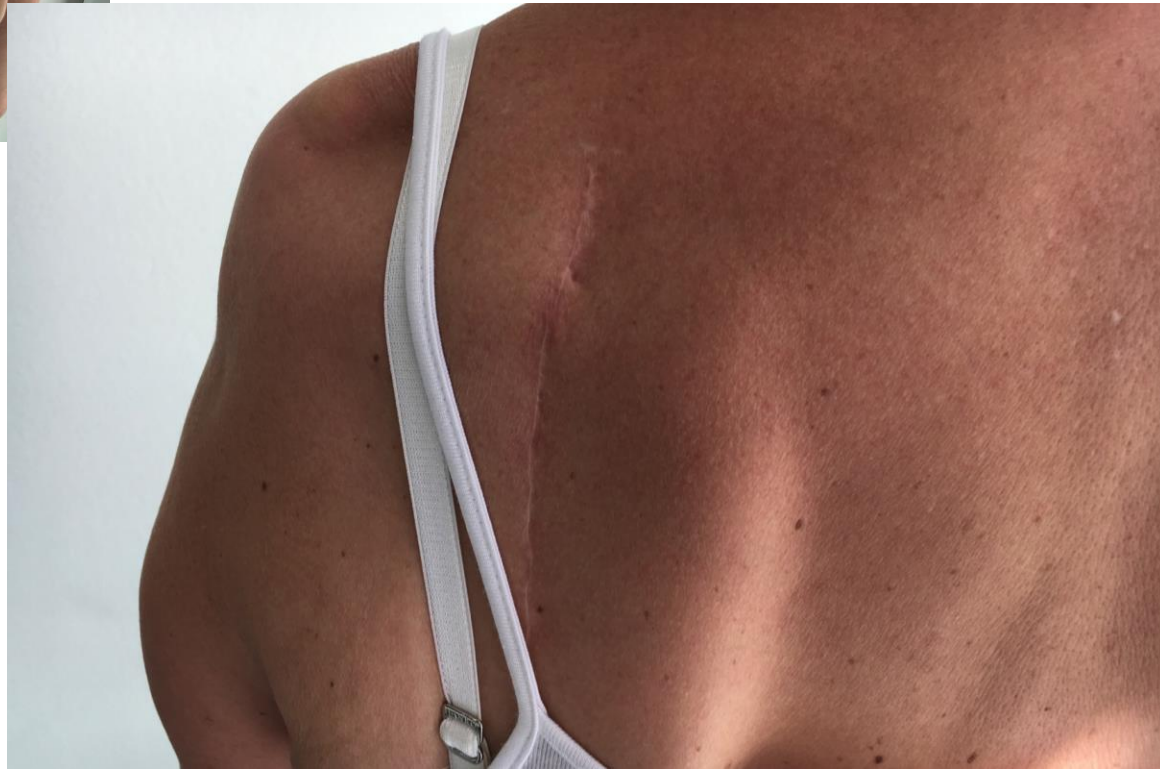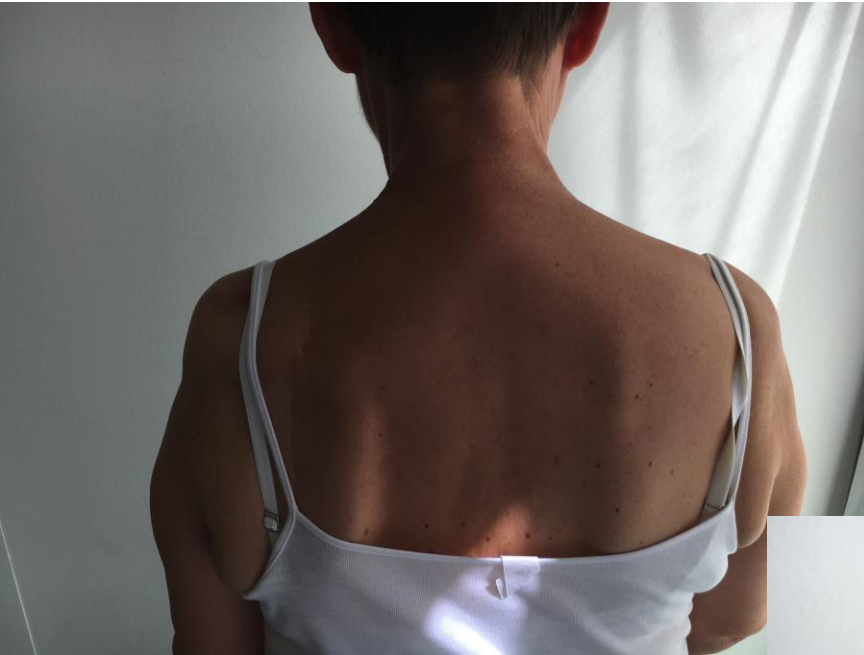Die Patientin wird für die Nachkontrollen in die Universitätsklinik Balgrist aufgeboten.

Scapula; 3D precision partial resection



Scapula; 3D precision partial resection

May 16, 2017



Scapula; 3D p

ction

May 16, 2017

