

Scapula; complete transarticular

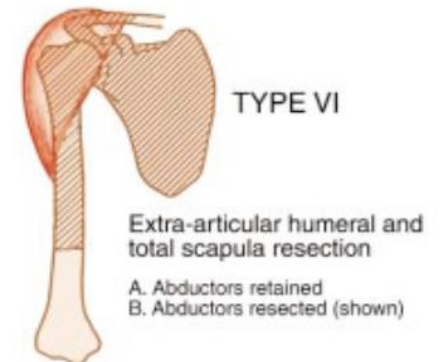
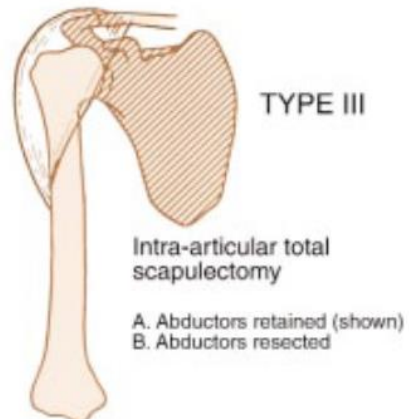
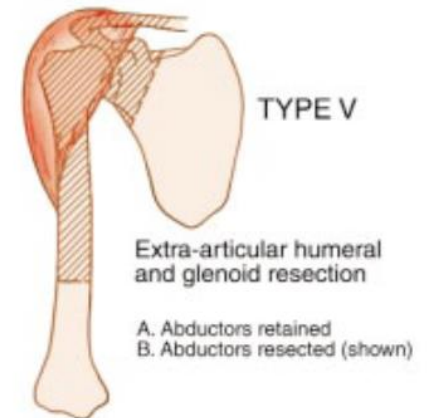
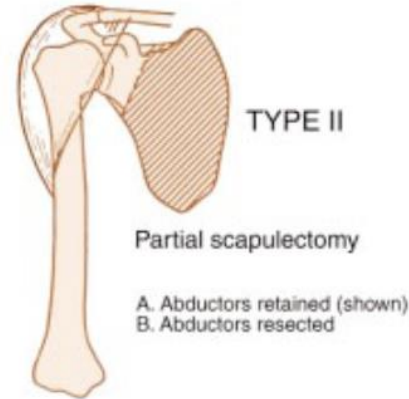
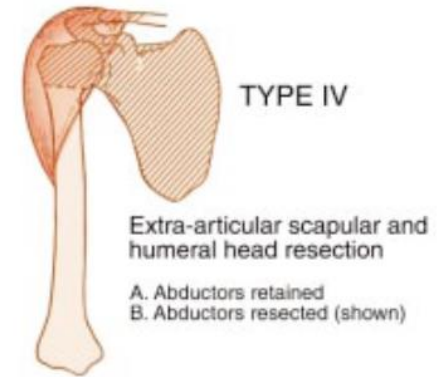
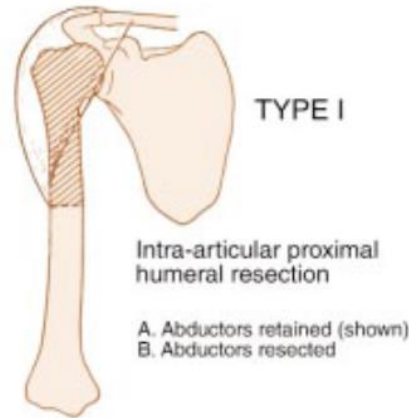
♀ 35y, Lawyer (Barcelona) 1st referral: 18.08.2006

HPI:

- Since 2000 increasing R shoulder pain, atraumatic
- Aug 2002: Pain progression -> x-ray “normal”
- Sept 2005: Scintigraphy & MRI -> enhancing mass in the supraspinatus fossa
- Aug 2006: 1st referral Balgrist with constant pain R dorsal shoulder (right-dominant), night pain

PMH: non contributory

Annex 1: Malawer classification of shoulder girdle resection



axillary nerve?

intra- / transarticular?

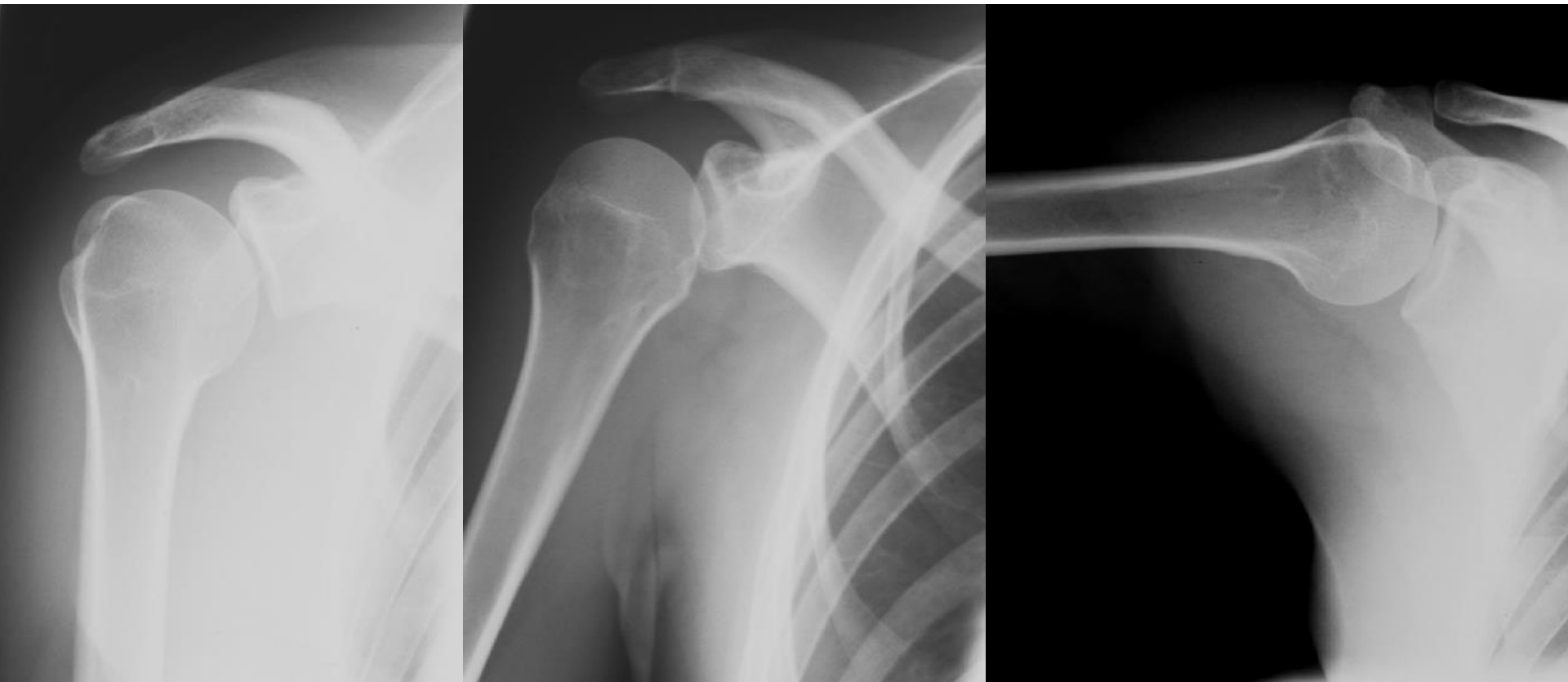level of OT & abductor?

Scapula; complete transarticular consultation, Aug 18, 2006

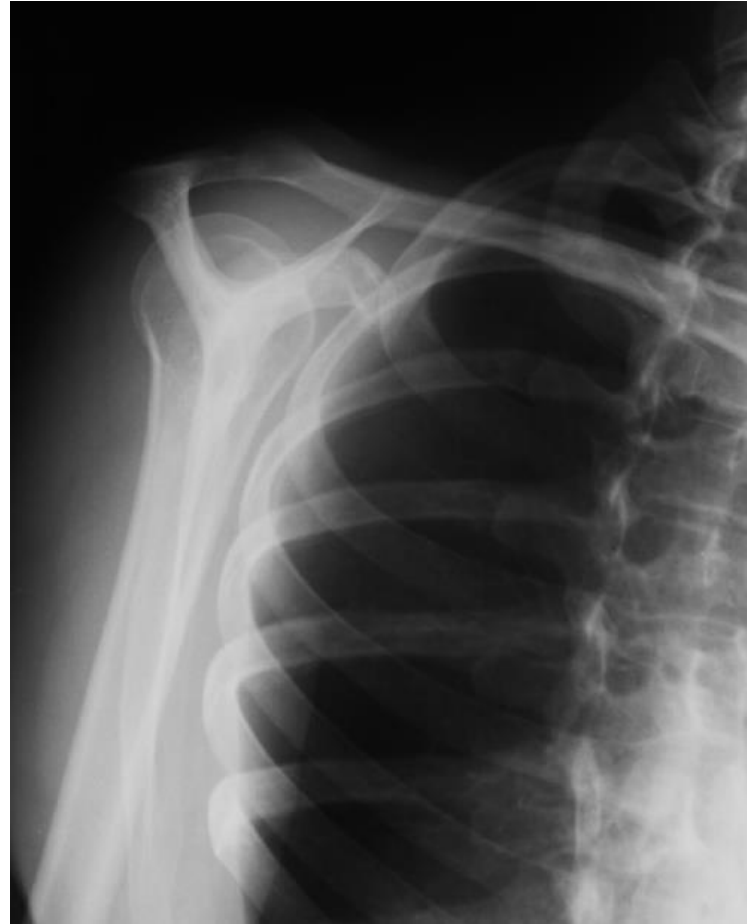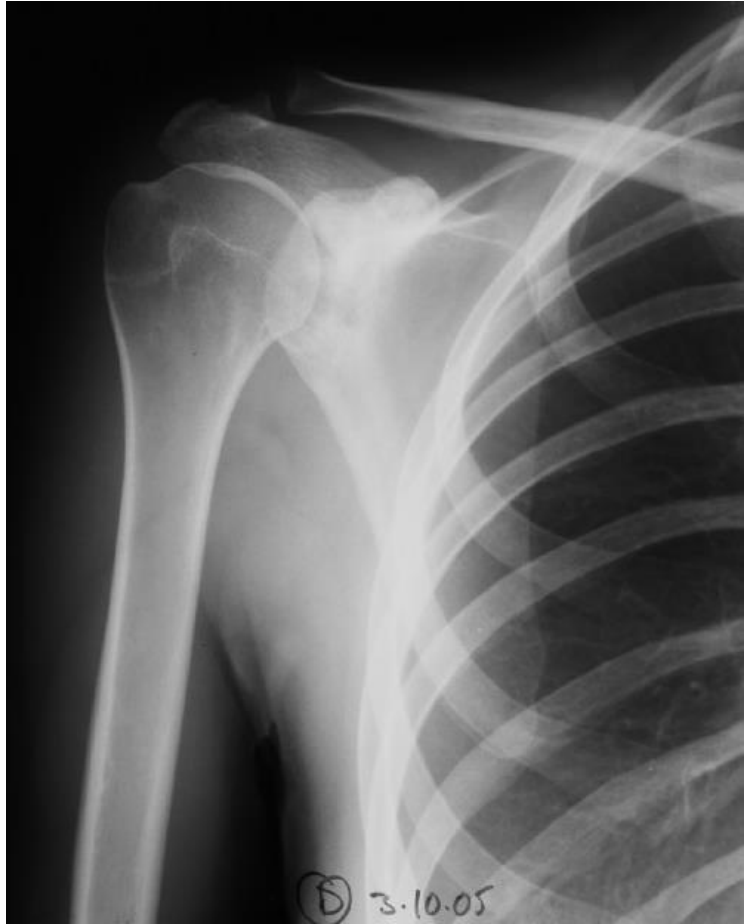clinical findings:

- **Hard, pressure-sensitive swelling fossa supraspinatus and anterior next to coracoid.**
- **No atrophy of the infraspinatus. No Pressure pain over the AC joint.**
- **Active flexion 100 ° , passive 120 ° .**
- **Active abduction 90 ° , passive 130 ° .**
- **AR 10 ° (opposite side 25 °), IR L3/L4.**
- **Significantly decreased strength for abduction, IR and AR not due to pain.**

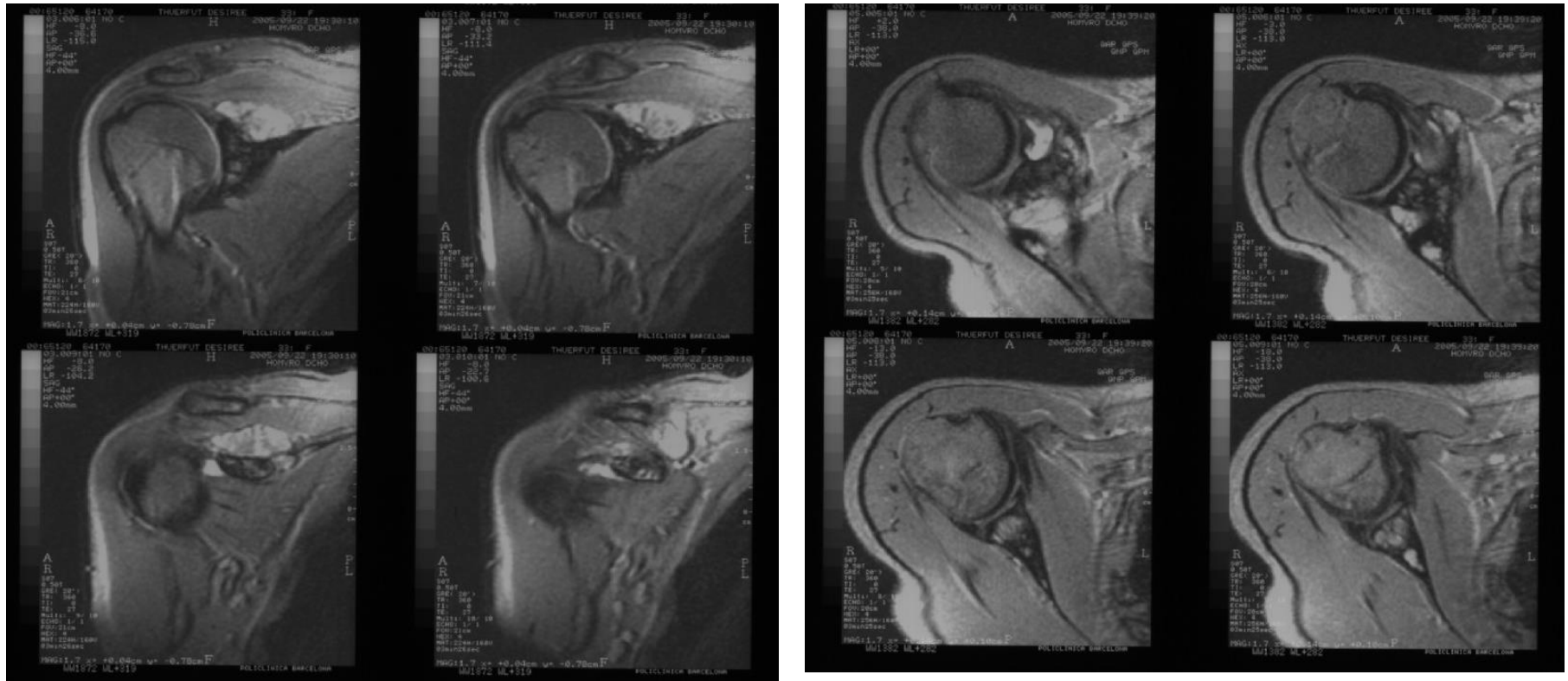
Scapula; complete transarticular x-ray R shoulder, Aug 27, 2002



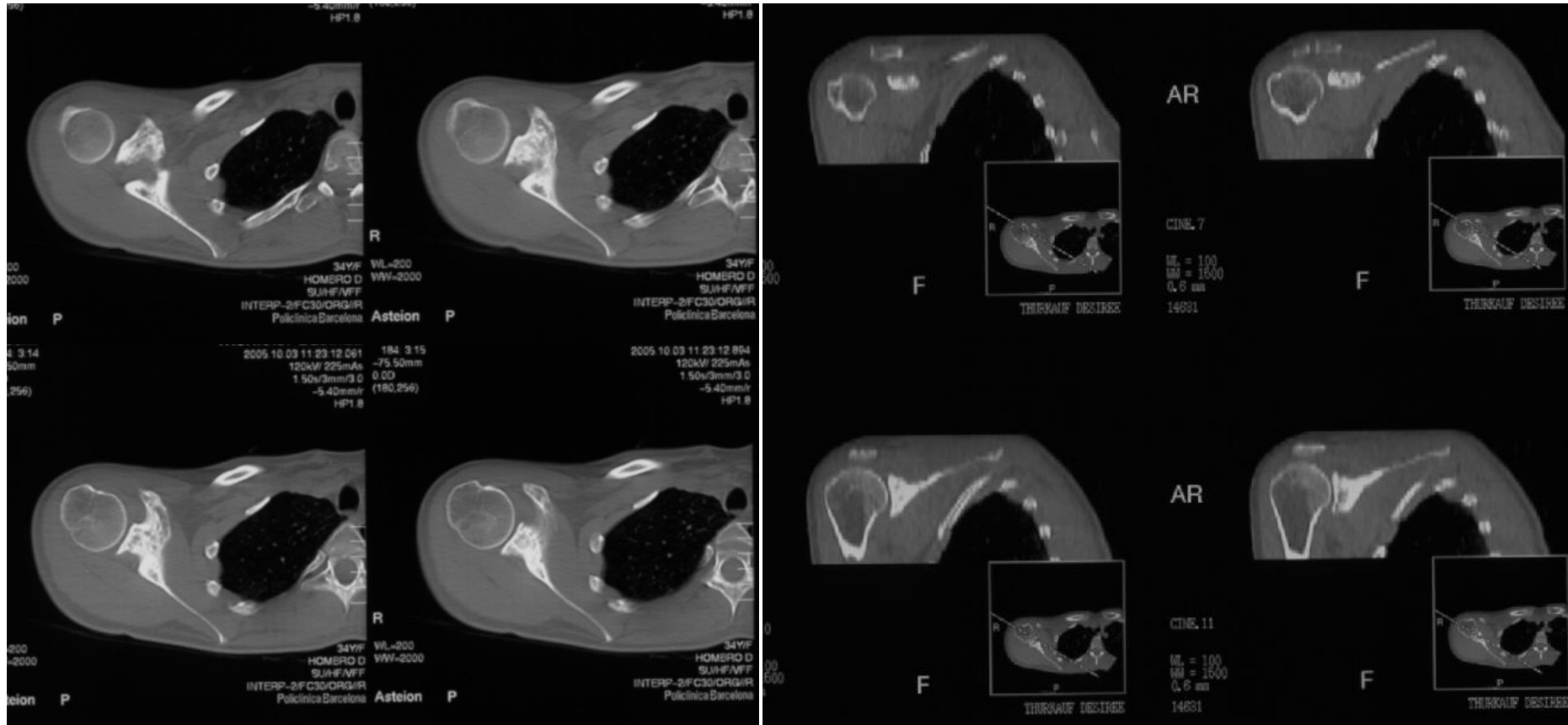
Scapula; complete transarticular x-ray R shoulder, Oct 03, 2005



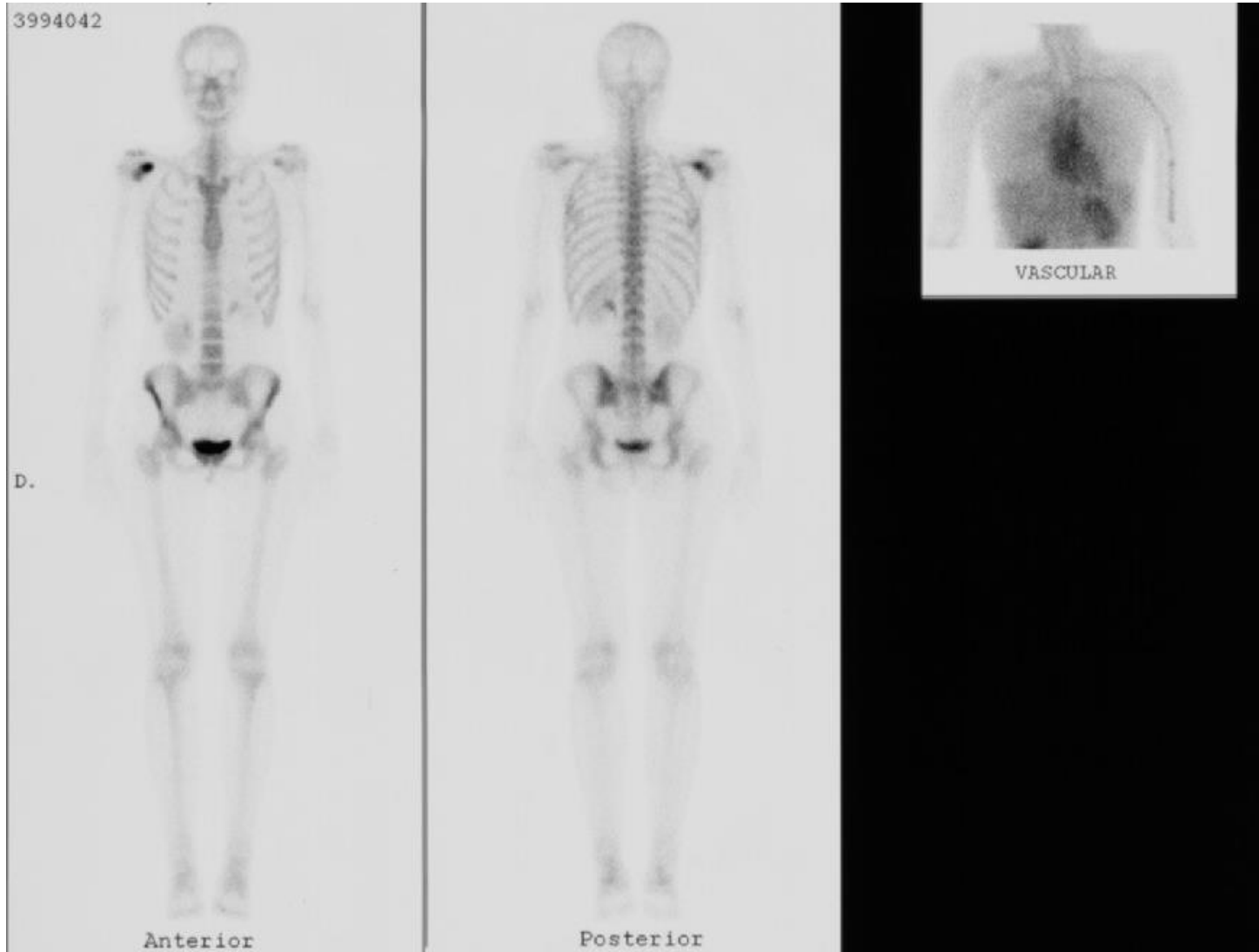
Scapula; complete transarticular MRI R shoulder, Sep 22, 2005



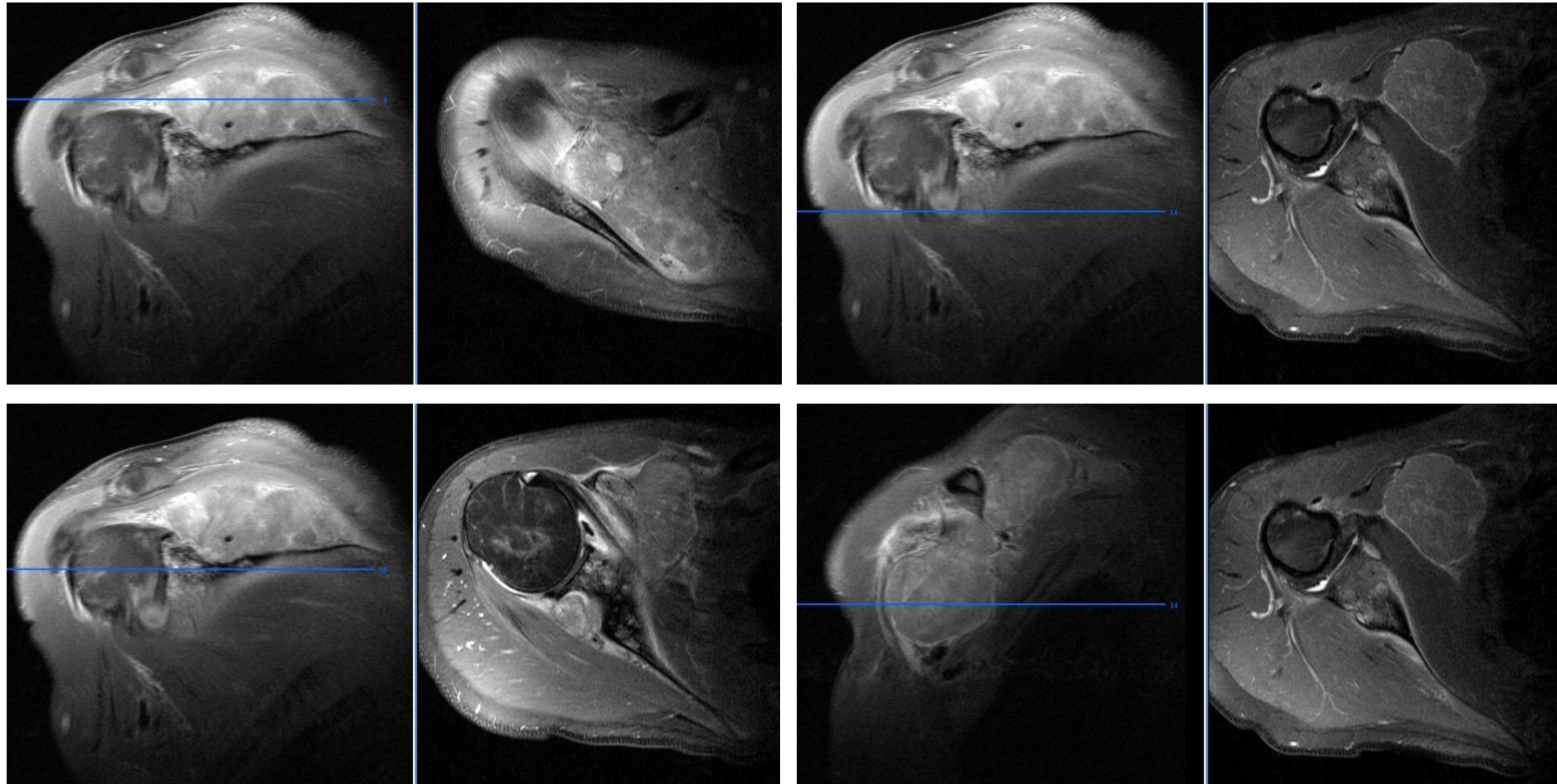
Scapula; complete transarticular CT R shoulder, Oct 03, 2005



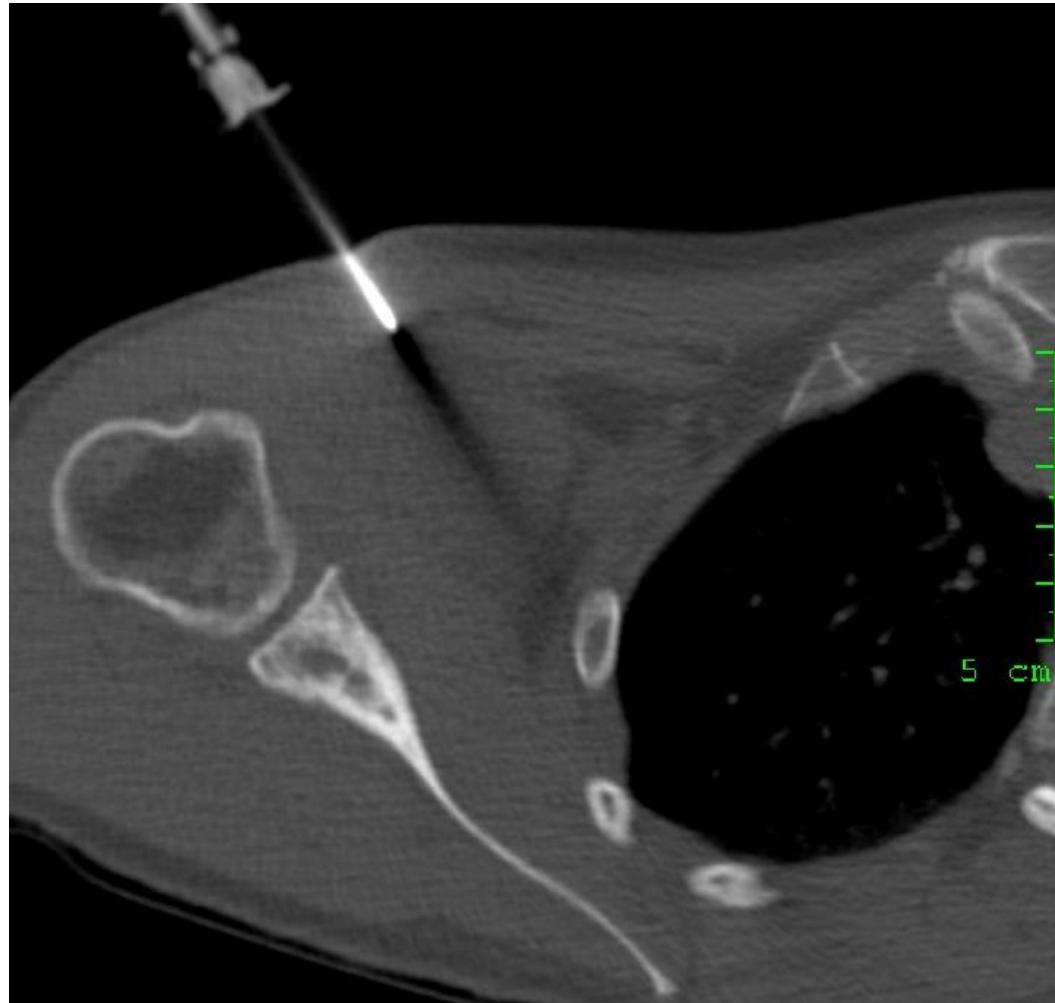
Scapula; complete transarticular Scintigraphy, Dec 19, 2005



Scapula; complete transarticular MRI R shoulder, Aug 18, 2006



Scapula; complete transarticular CT Biopsy, Aug 18, 2006

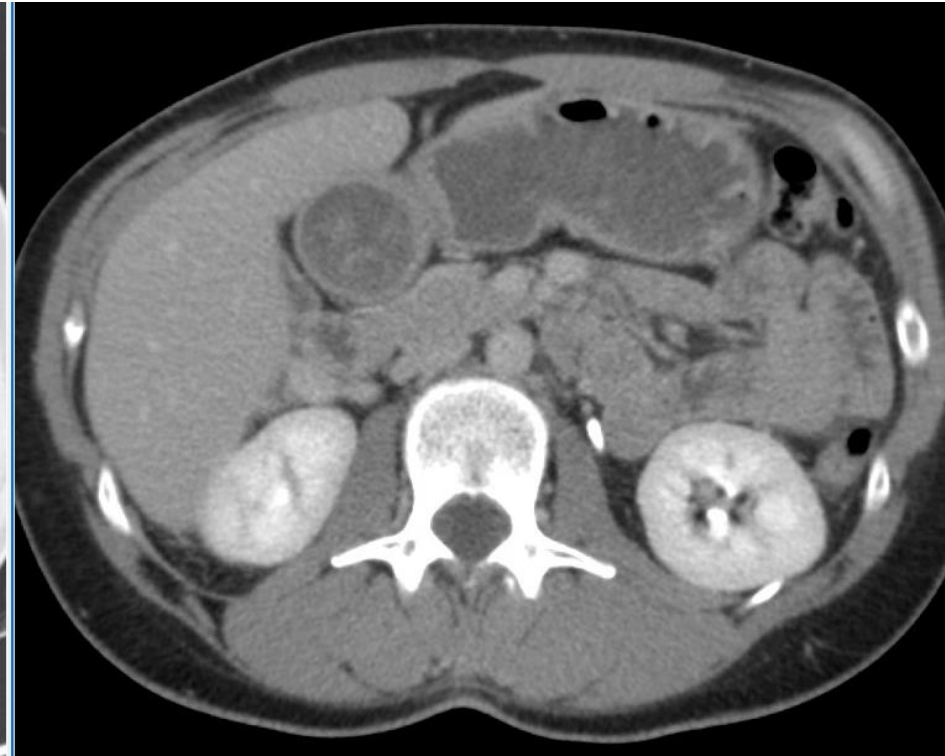
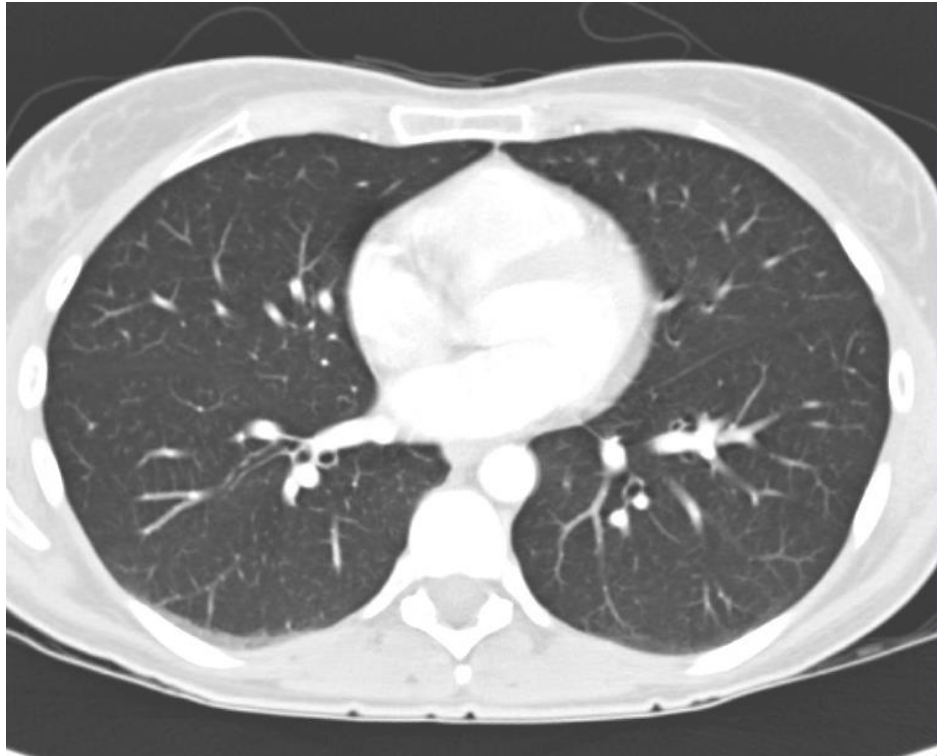
**Scapula; complete transarticular
pathology USZ, Aug 18, 2006, USZ B 2006.29018**

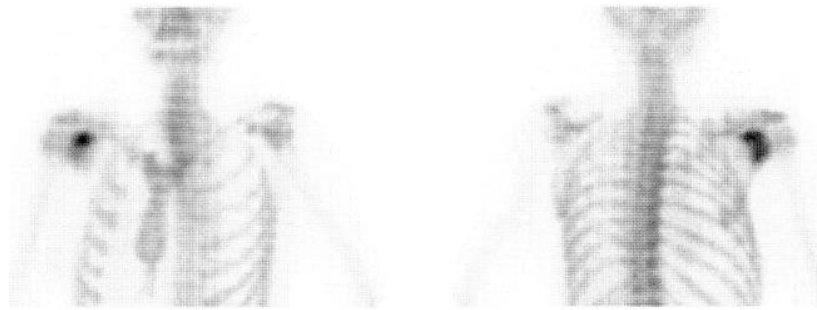
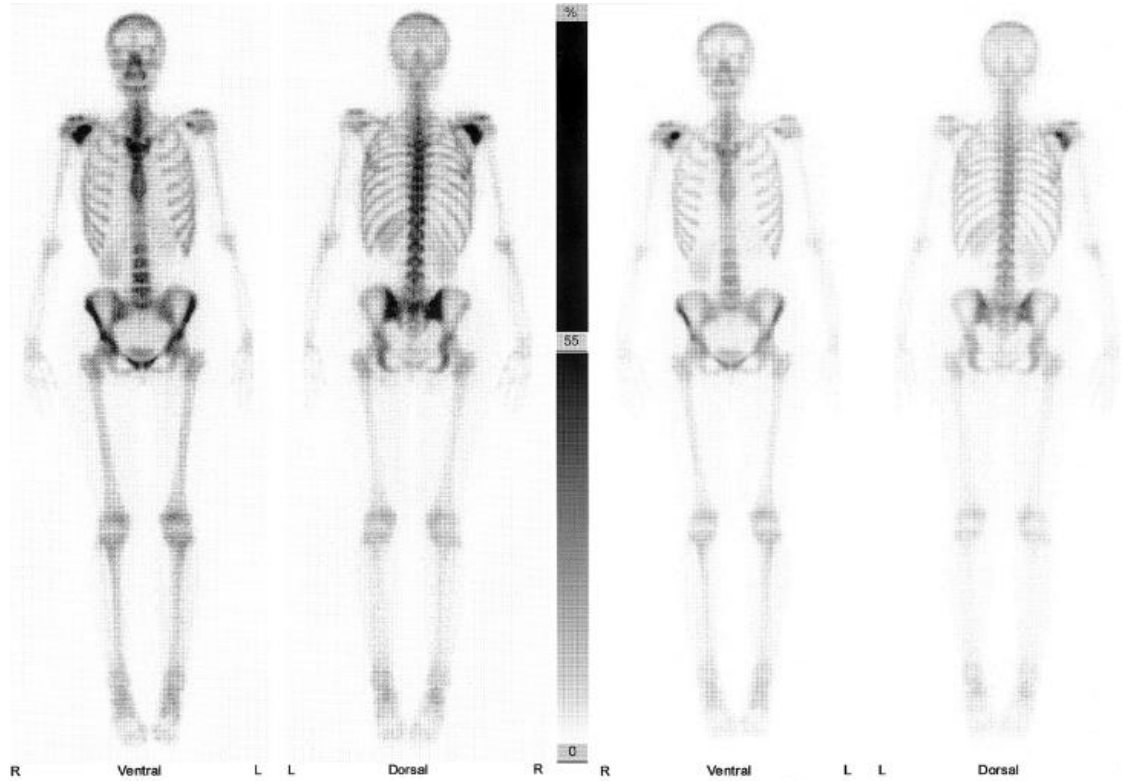
Ewing-Sarkom Glenoid R

(CD99 positiv, Translocation EWS/FLI-1 Typ A
with PCR and FISH positiv)

Scapula; complete transarticular CT chest+abd, Sept 11, 2006



Scapula; complete transarticular Szintigraphy, Sept 18, 2006



Scapula; complete transarticular

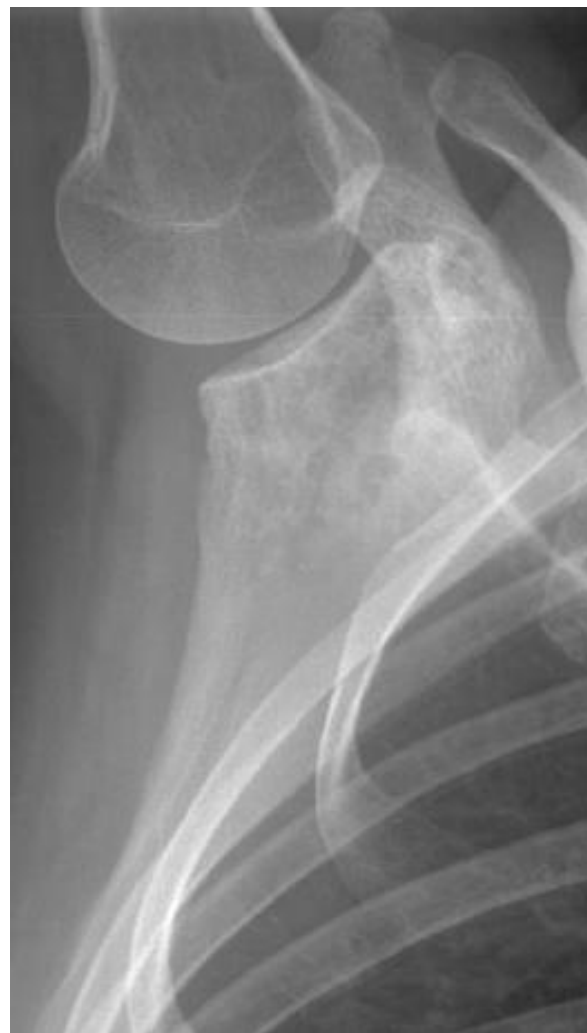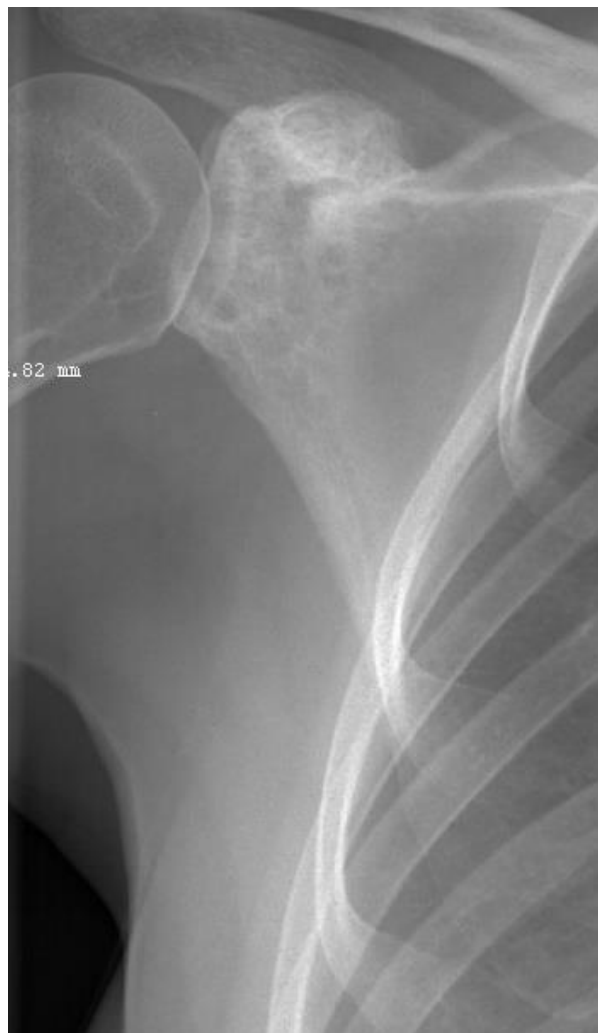Neoadjuvant ChTx after VIDE scheme

**Vincristine, Ifosamide, Doxorubicin,
Etoposide**

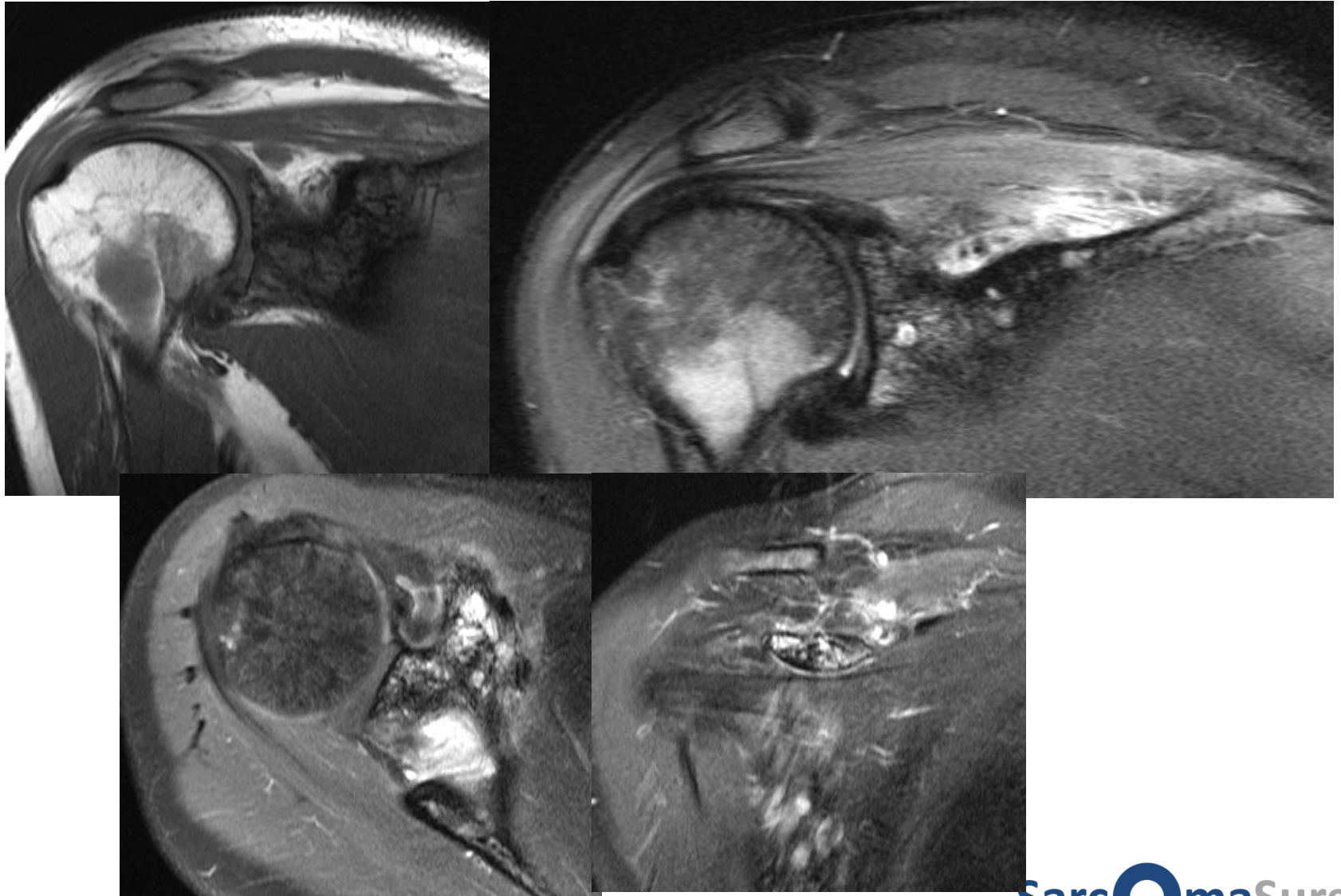
(EURO E.W.I.N.G 99)

2.10.06 - 15.12.07

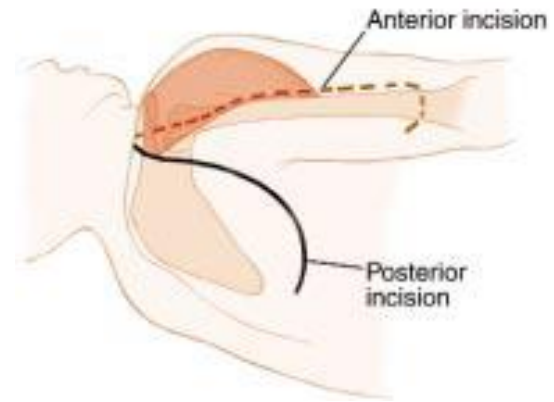
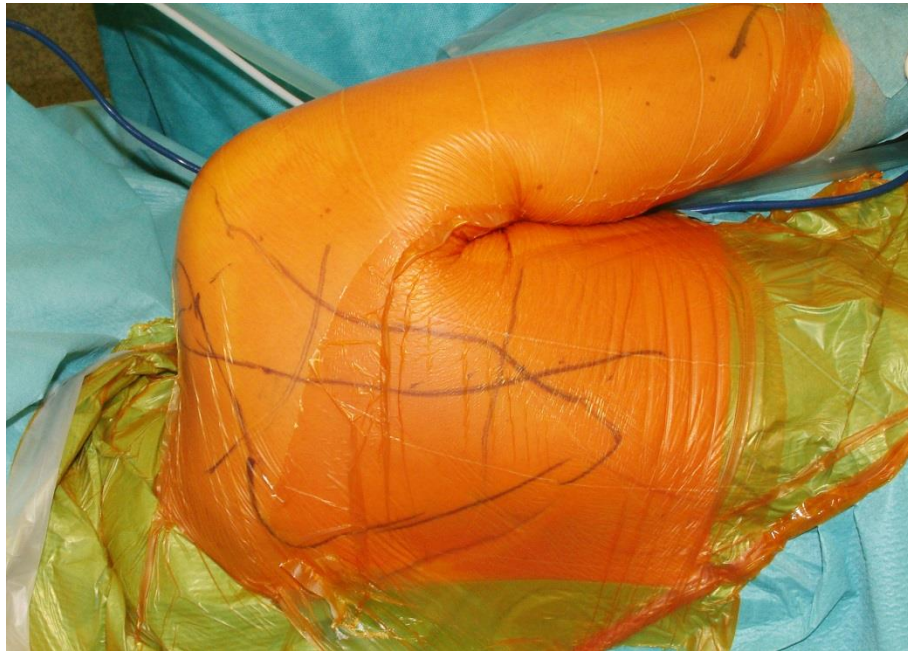Scapula; complete transarticular x-ray R shoulder, Feb 07, 2007 (post ChTx)



Scapula; complete transarticular MRI R shoulder, Feb 07, 2007 (post ChTx)



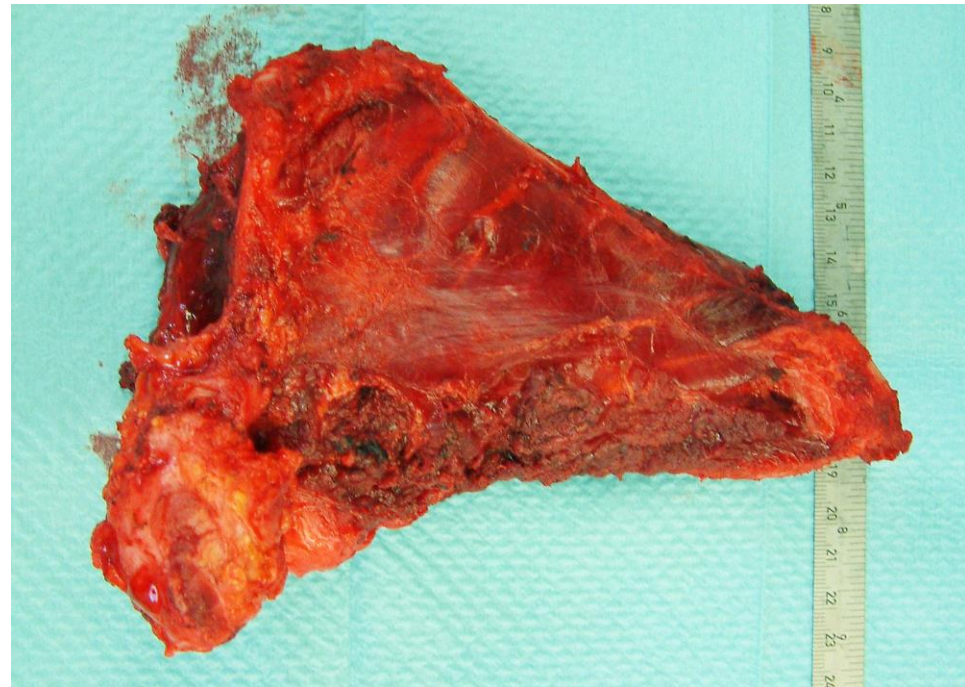
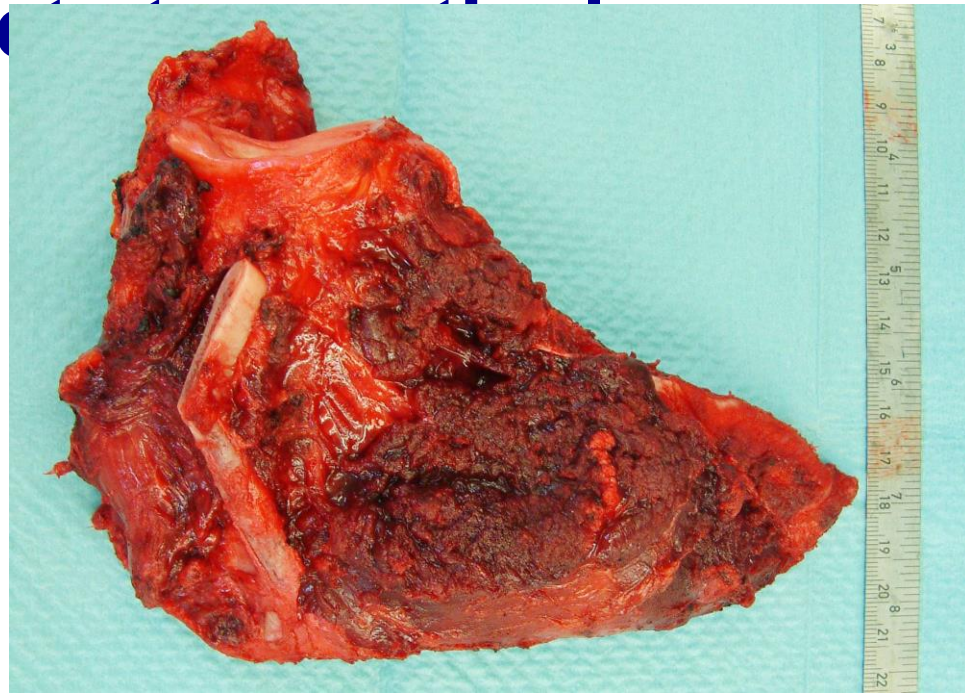
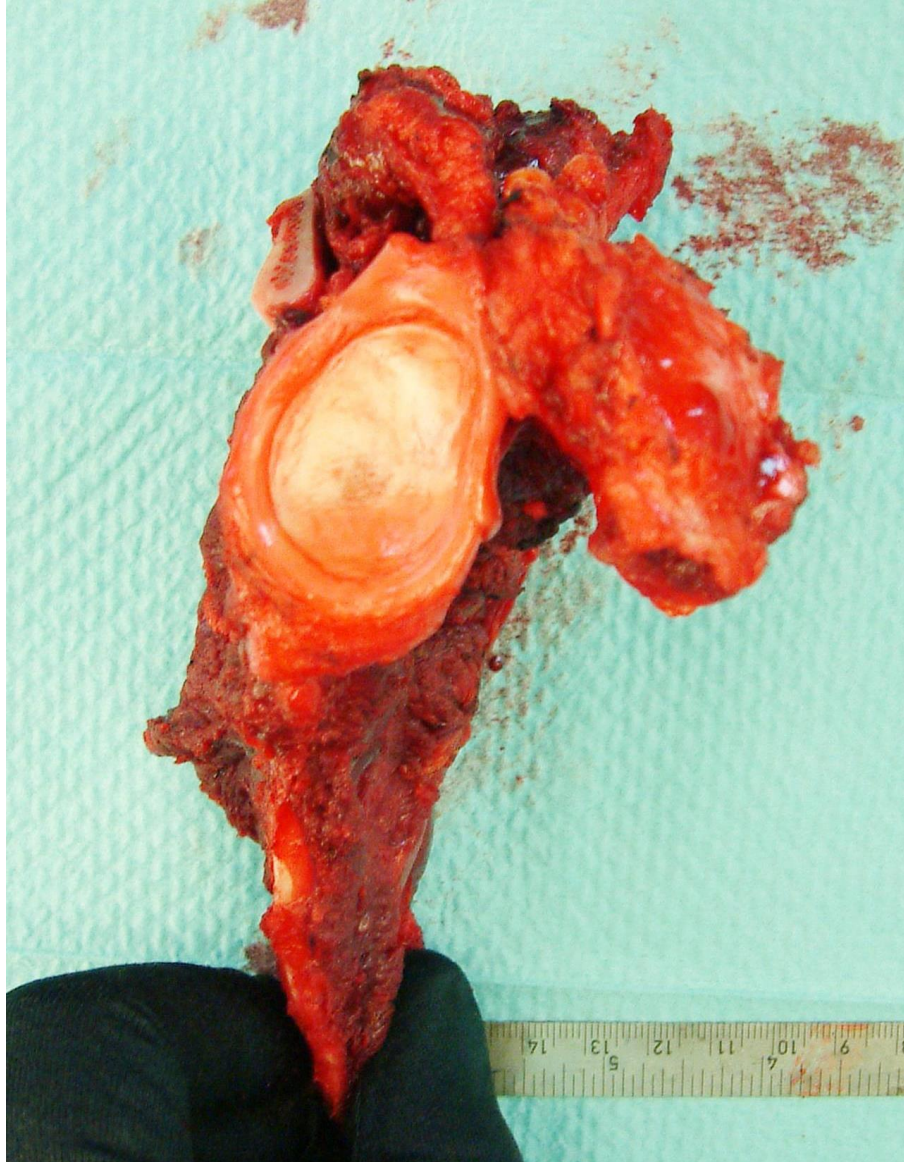
Scapula; complete transarticular surgery, Mar 08, 2007



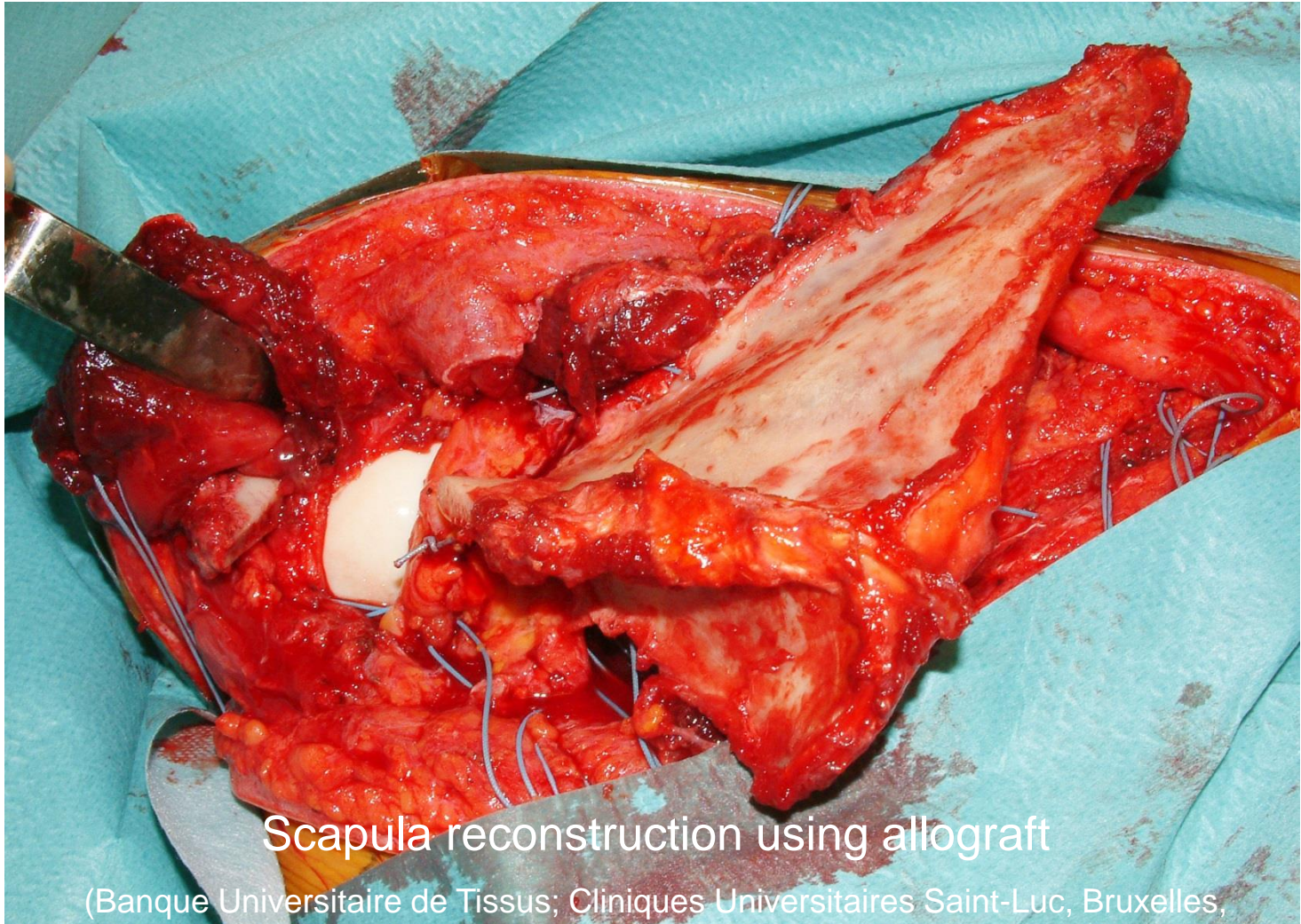
Resection of the right scapula
(Utilitarian incision),
transarticular resection
with preservation of the
N.axillaris / deltoid

Scapula; complete

Mar 08, 2007



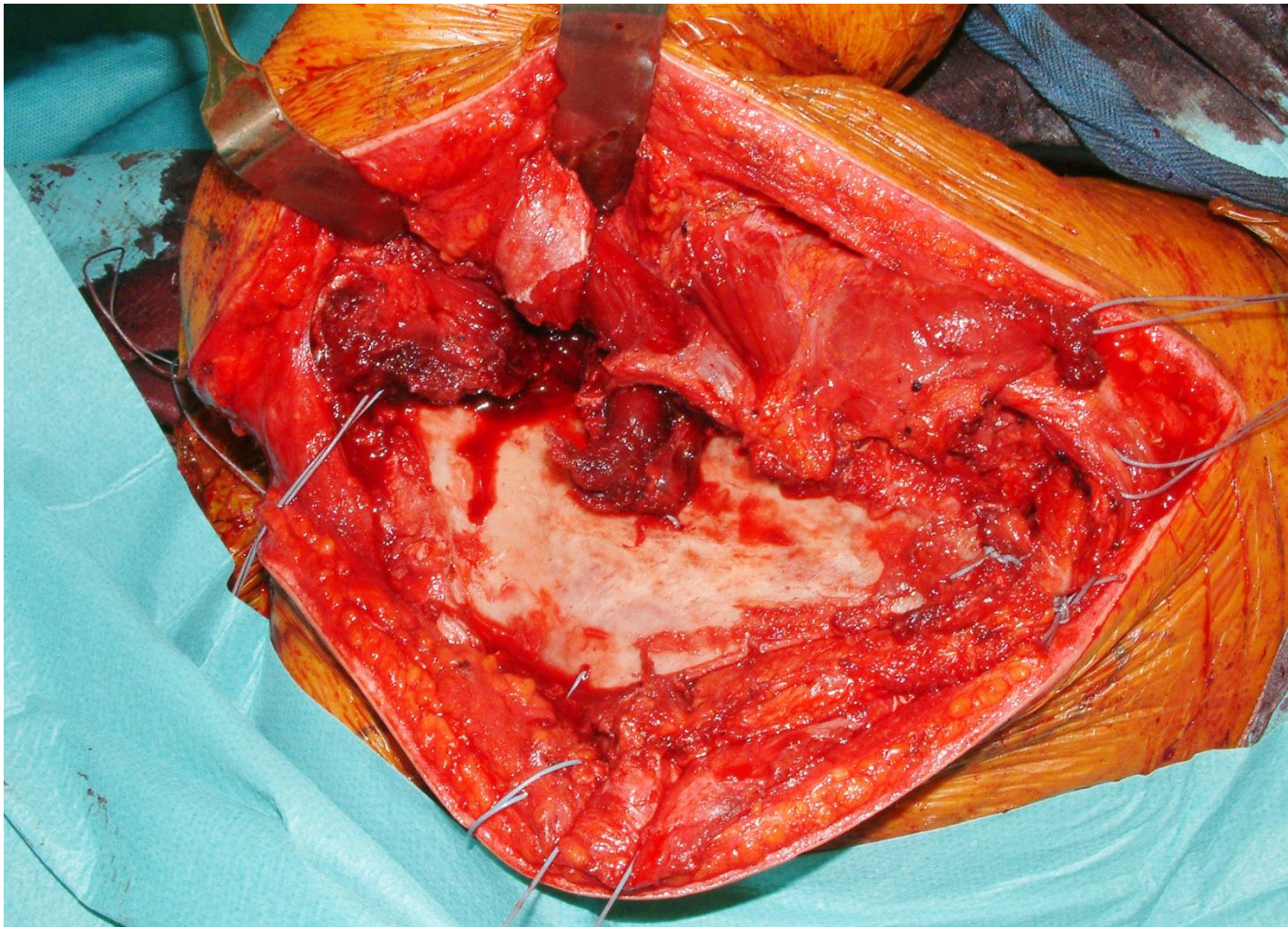
Scapula; complete transarticular surgery, Mar 08, 2007



Scapula reconstruction using allograft

(Banque Universitaire de Tissus; Cliniques Universitaires Saint-Luc, Bruxelles,

Scapula; complete transarticular surgery, Mar 08, 2007



Scapula; complete transarticular

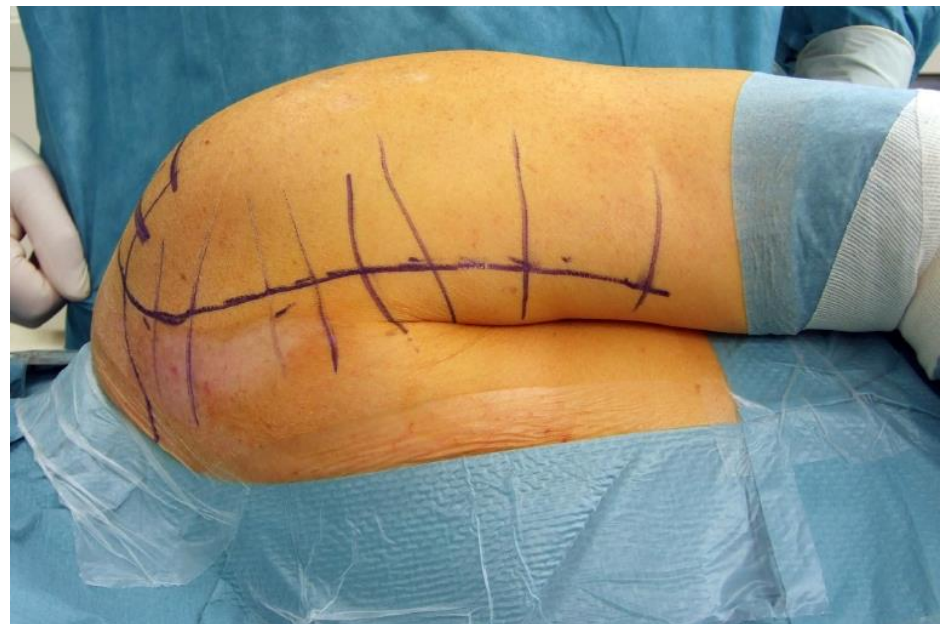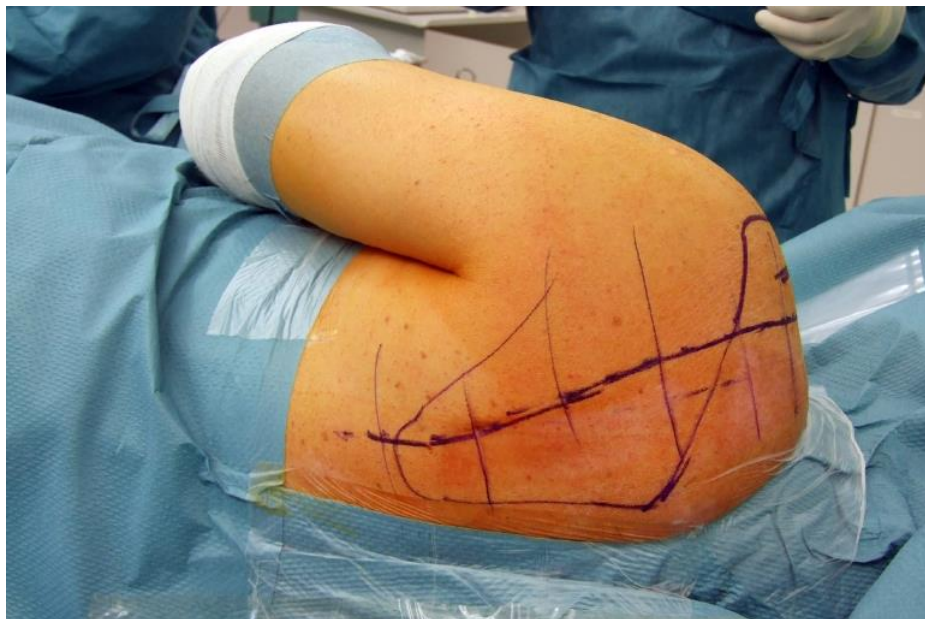♂ 45 yo

1st referral: 09.02.2011

HPI: The patient has an extensive history with Urachuscarcinoma. Since 2007 he reported shoulder pain. Late last year, he received a local radiotherapy 1 x 4 Gy and 11 x 3 Gy (37 Gy 27.10-12.11.2010)

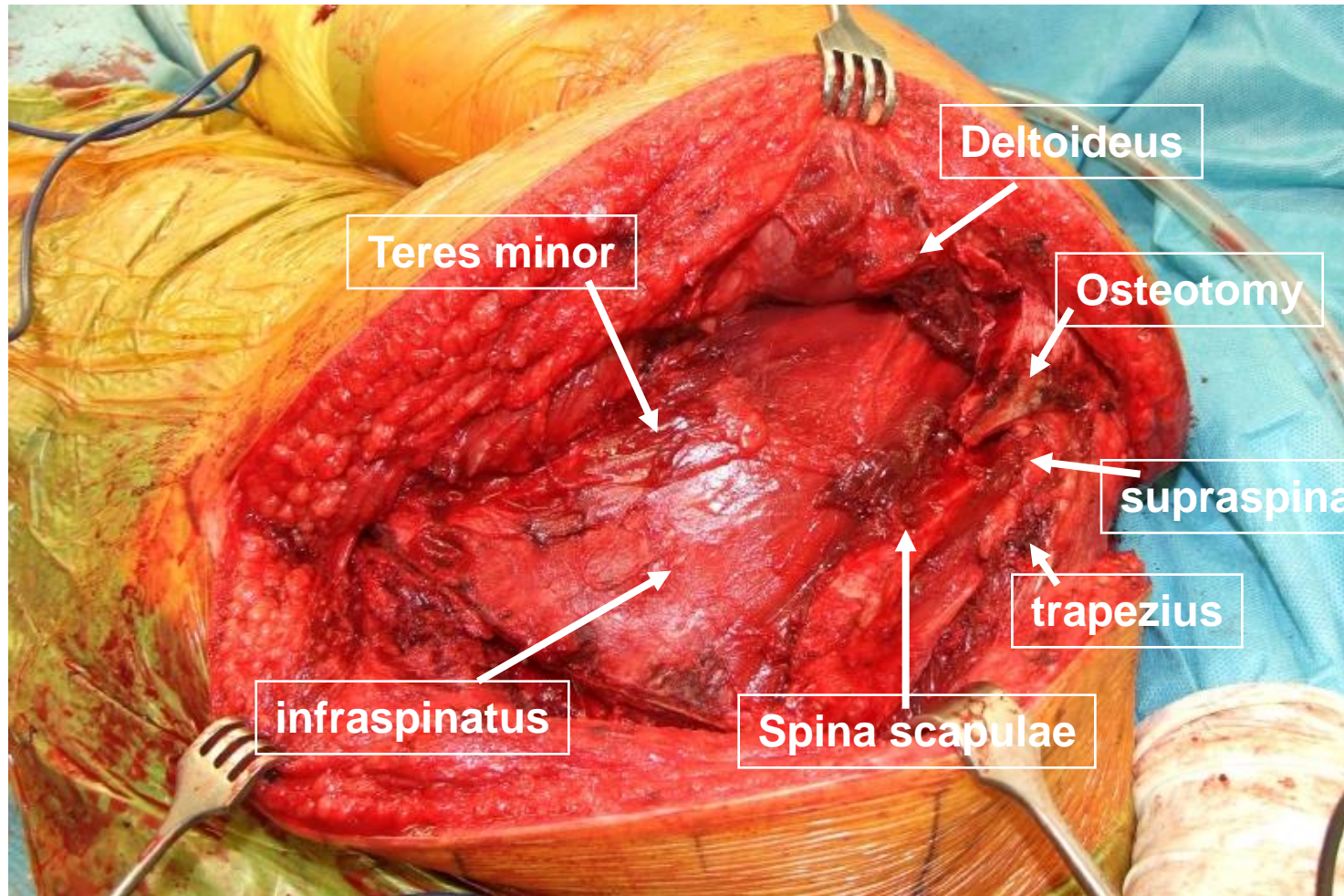
PMH: non contributory

Scapula; complete transarticular Scapulectomy, Mar 22, 2011

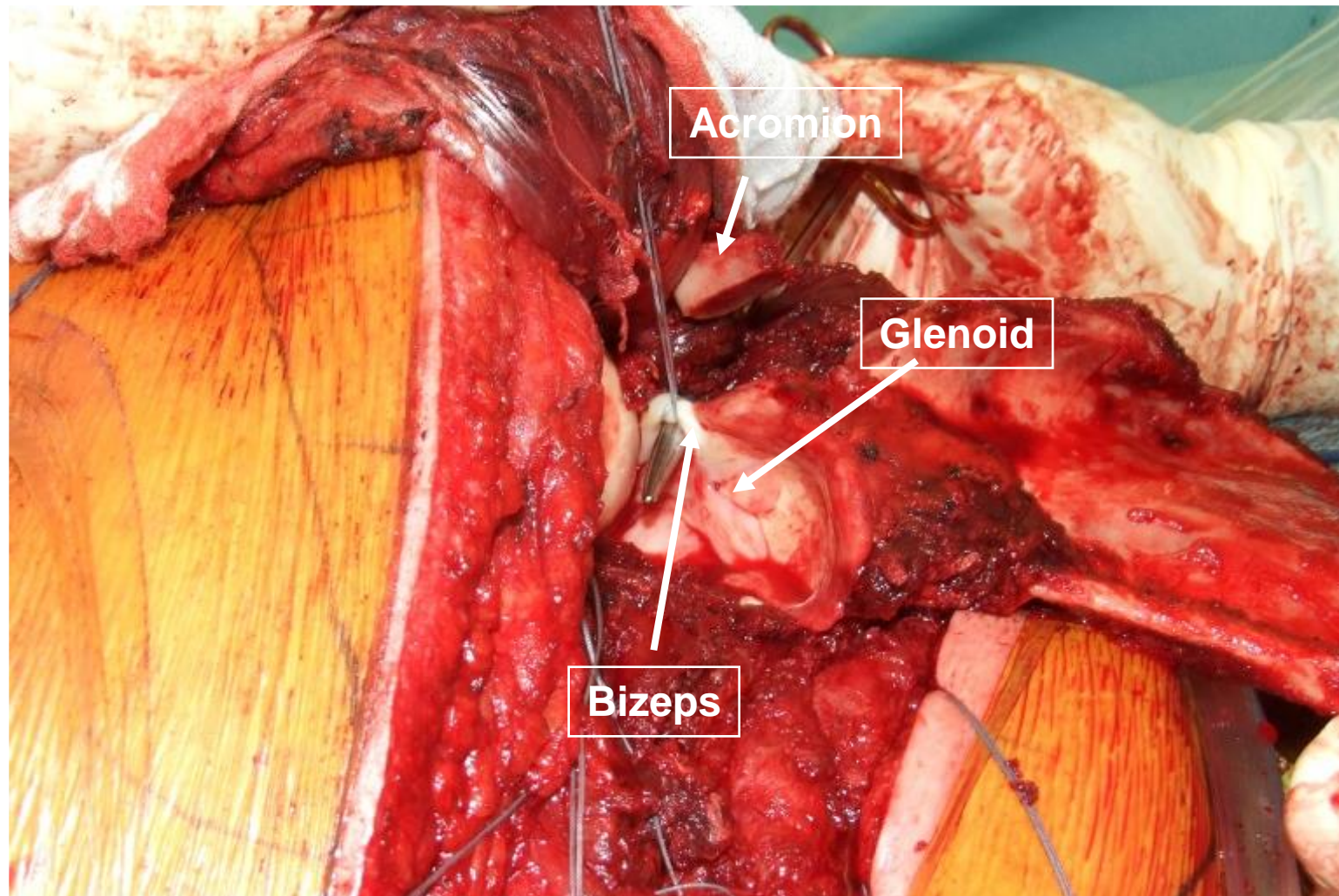


Utilitarian incision

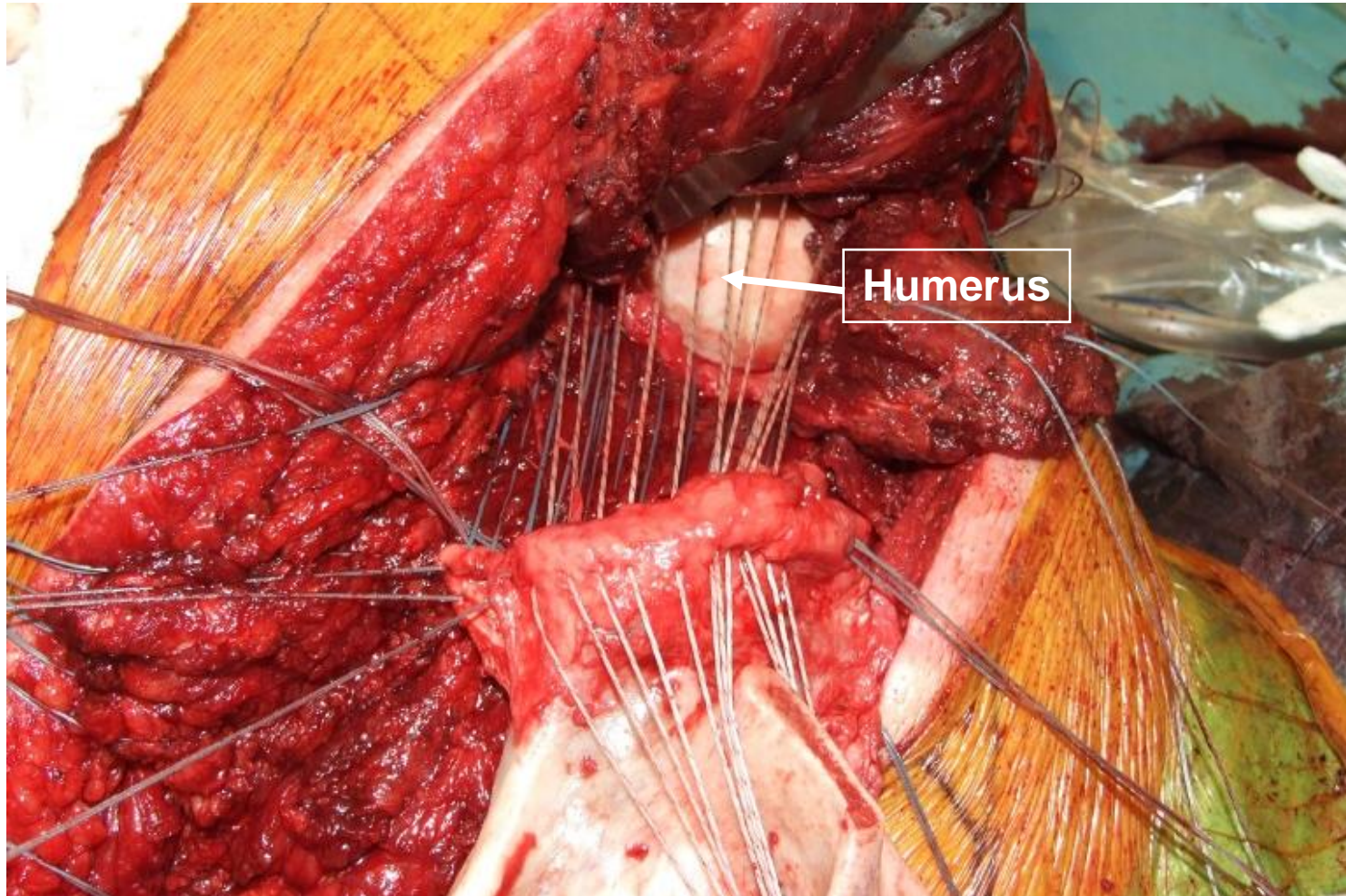
Scapula; complete transarticular Scapulectomy, Mar 22, 2011



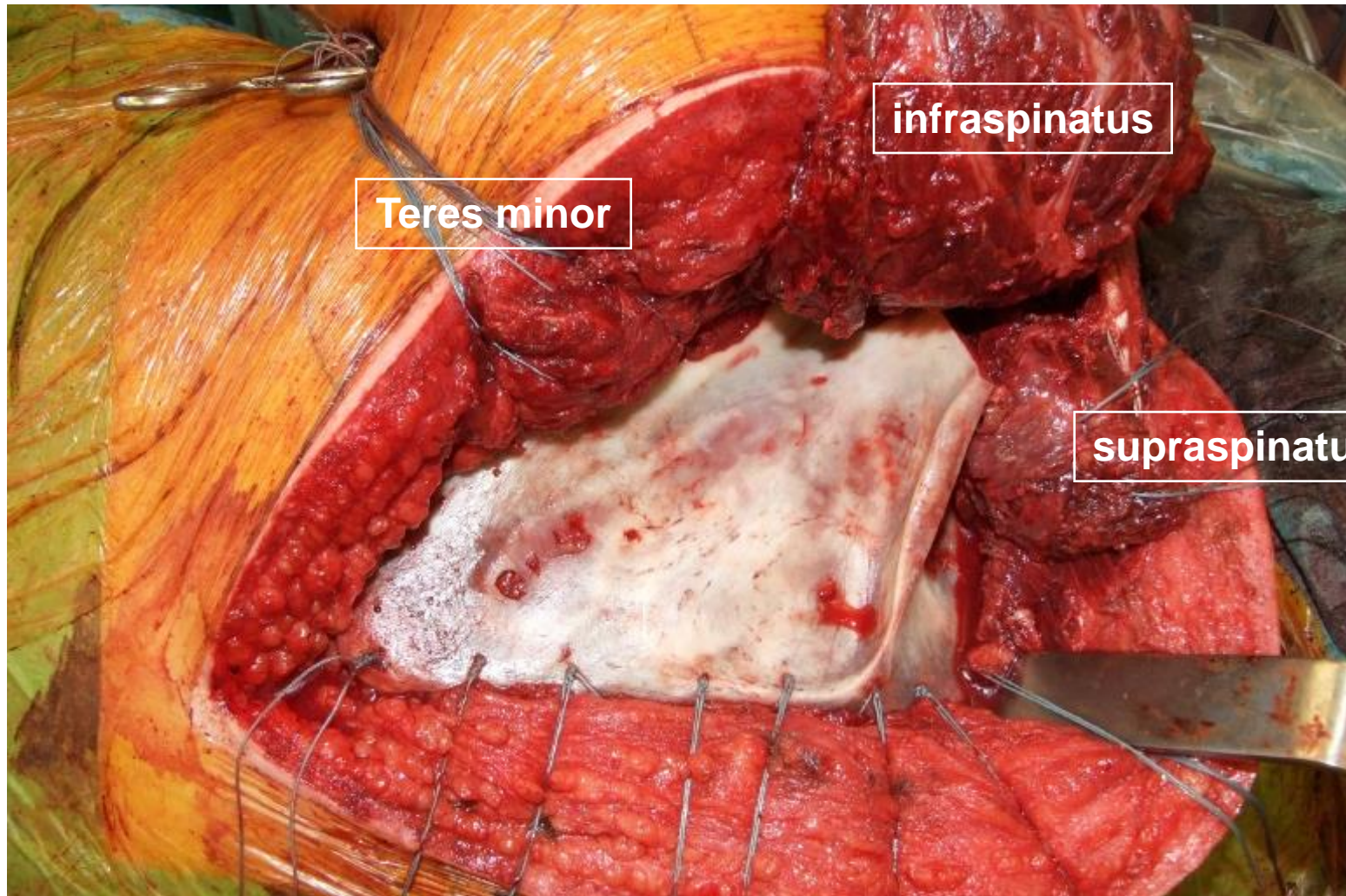
Scapula; complete transarticular Scapulectomy, Mar 22, 2011



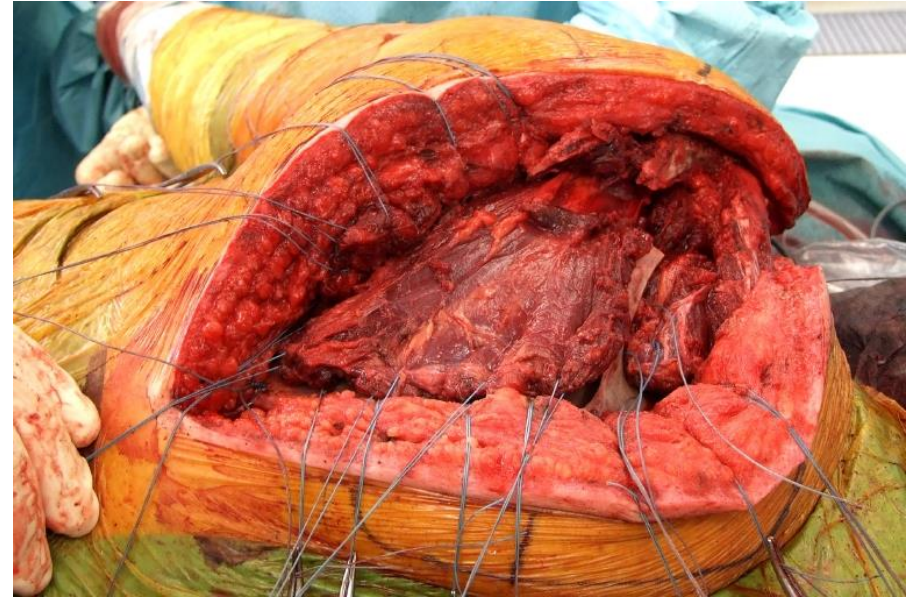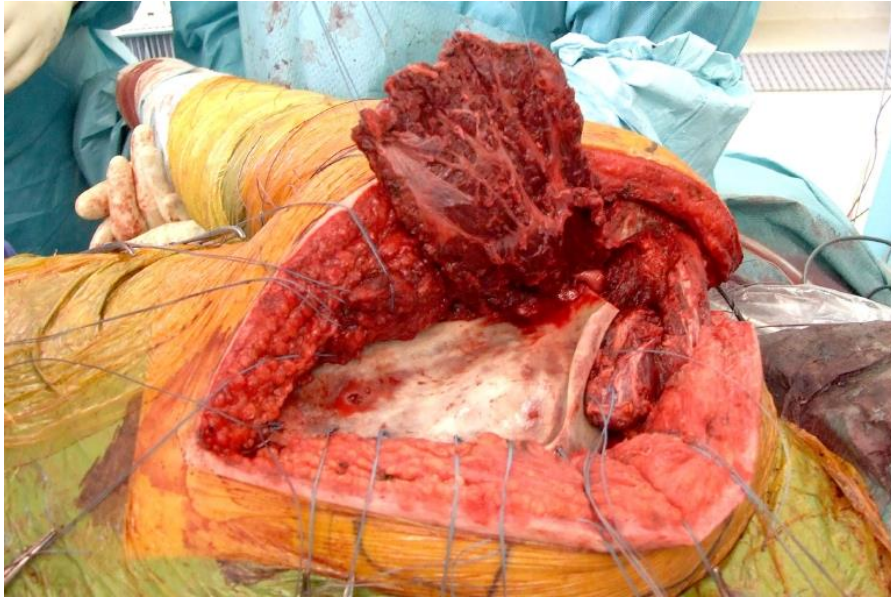Scapula; complete transarticular Scapula-Allograft, Mar 22, 2011



Scapula; complete transarticular Scapula-Allograft, Mar 22, 2011

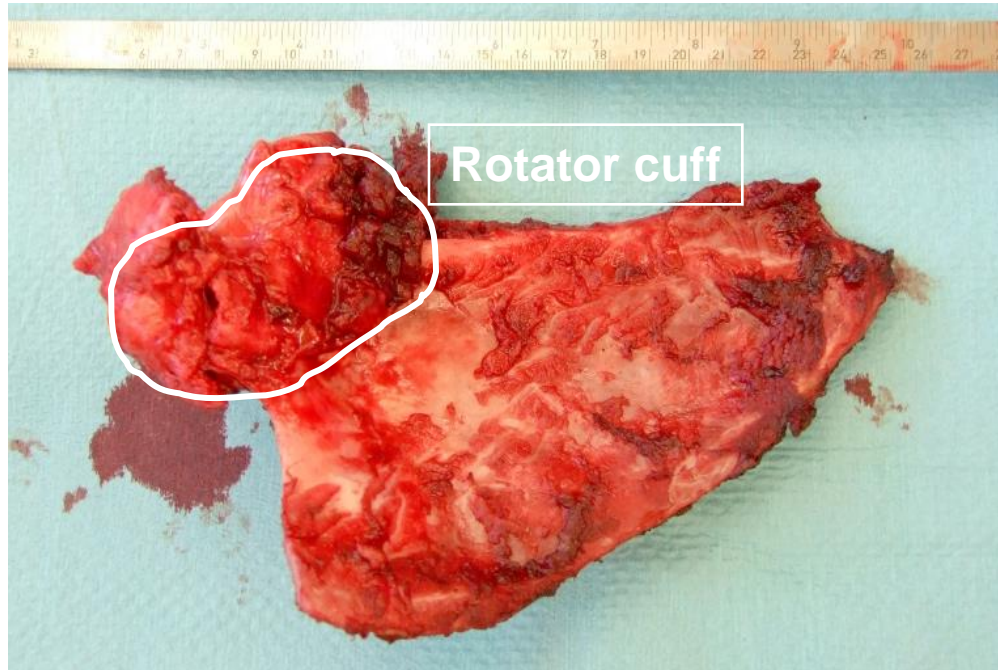


Scapula; complete transarticular Scapula-Allograft, Mar 22, 2011



Scapula; complete transarticular

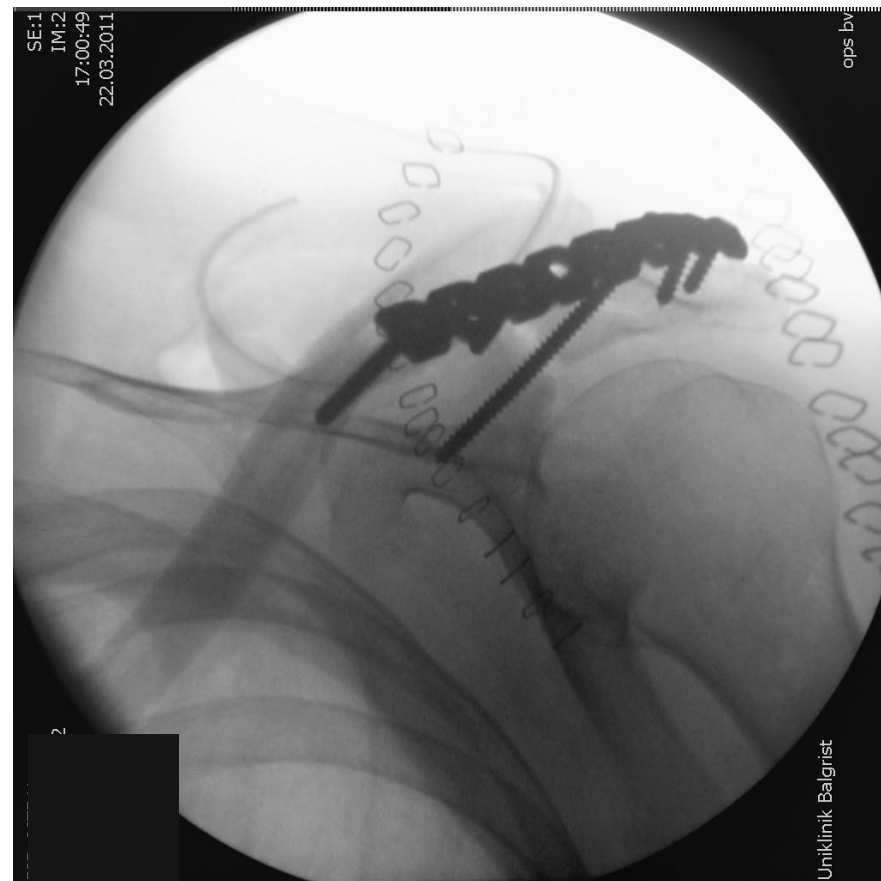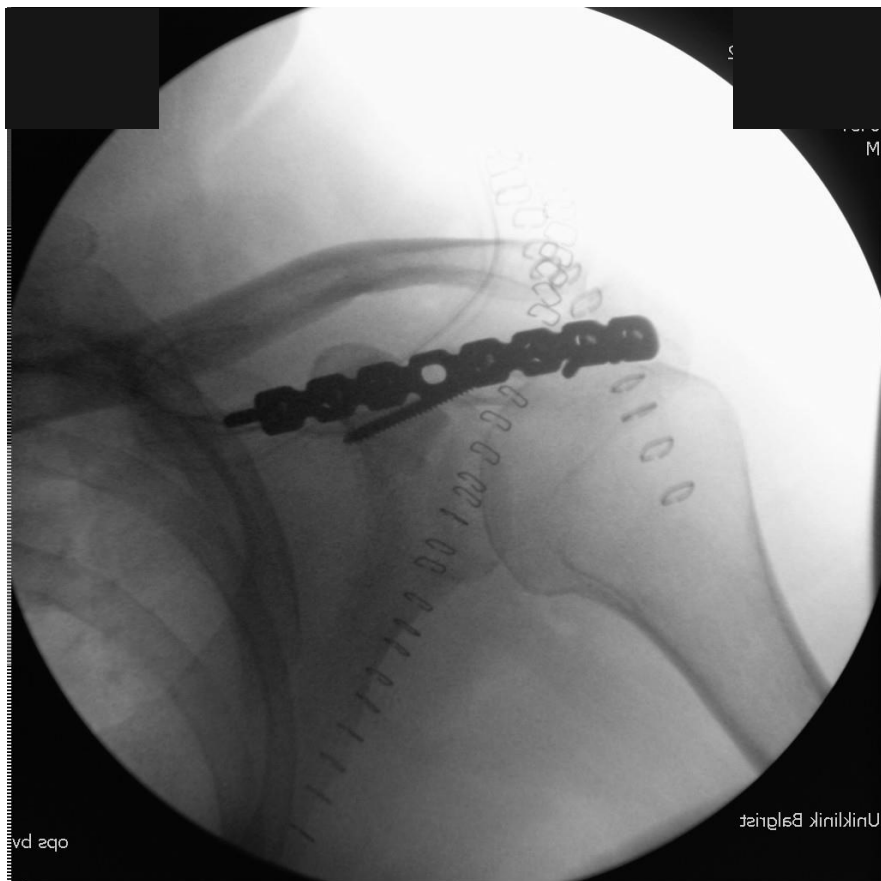Scapula, Mar 22, 2011



Diagnose

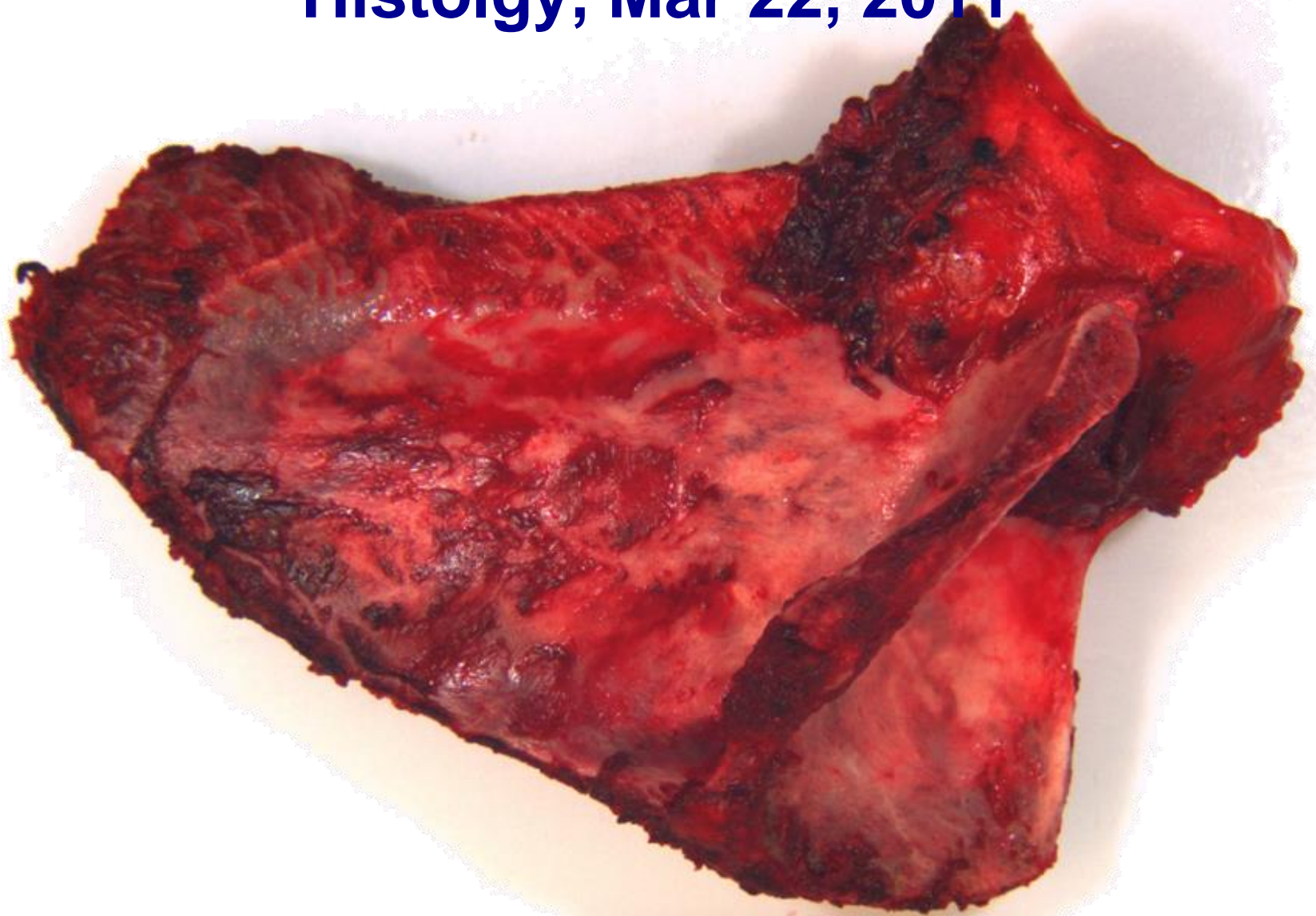Resektat der Skapula links mit einer überwiegend avitaler Metastase eines schleimbildenden Adenokarzinoms, Durchmesser: 4,9 cm (rekonstruiert am Schnitt). Das Adenokarzinom durchbricht die Kortikalis und infiltriert anhaftendes Weichgewebe und Skelettmuskulatur (vgl. Kommentar). Keine Gelenkinfiltration.

Scapula; complete transarticular xRay Scapula, Mar 22, 2011

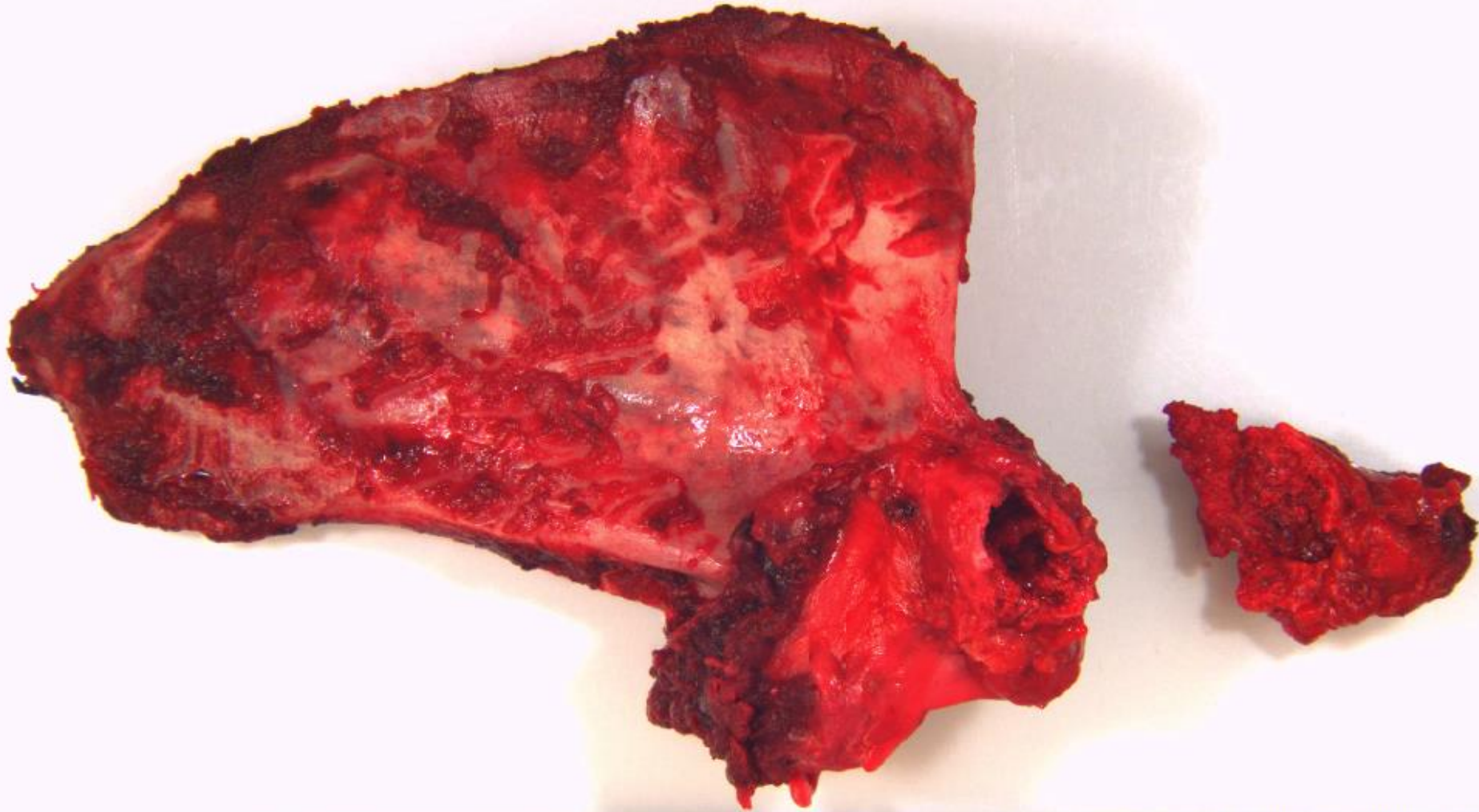


Allograft-fixation with plate

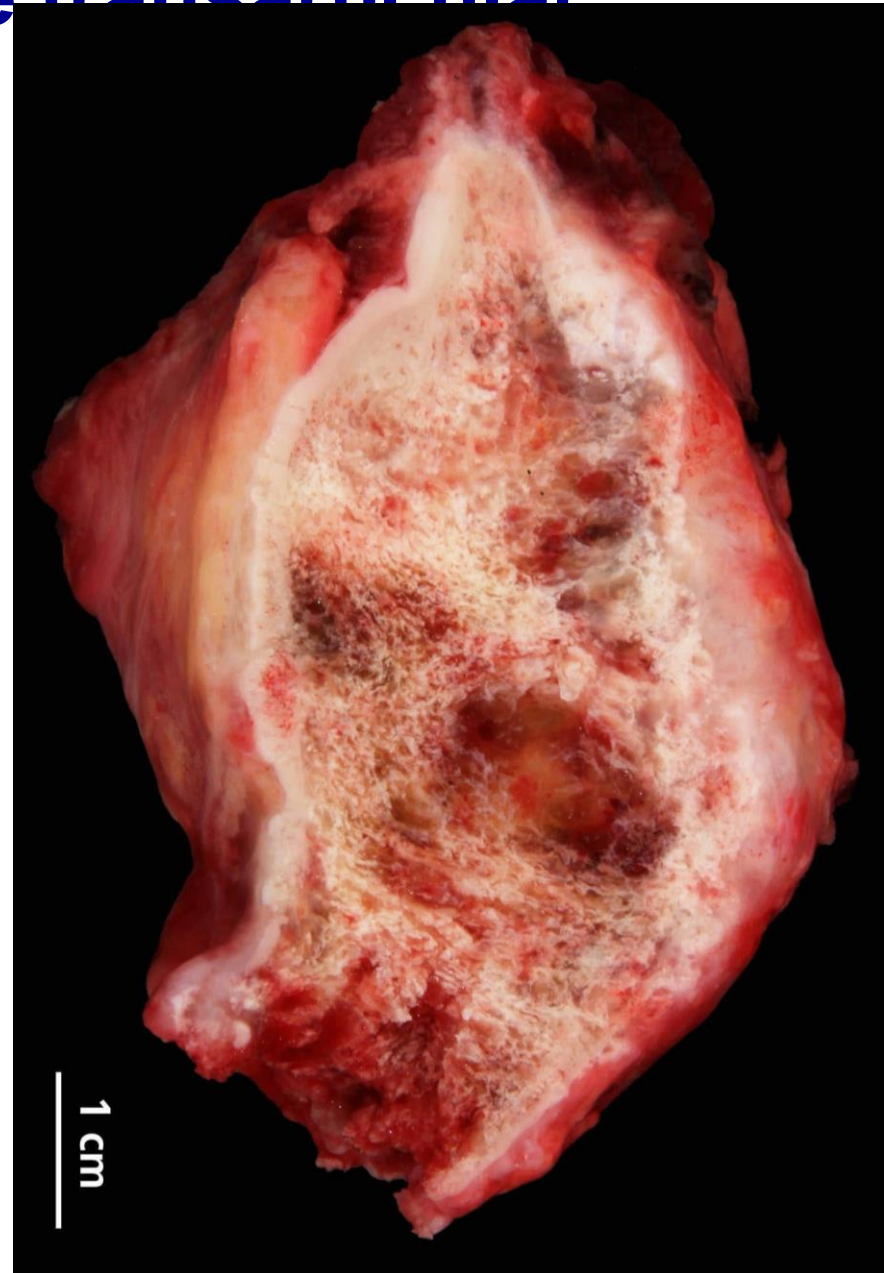
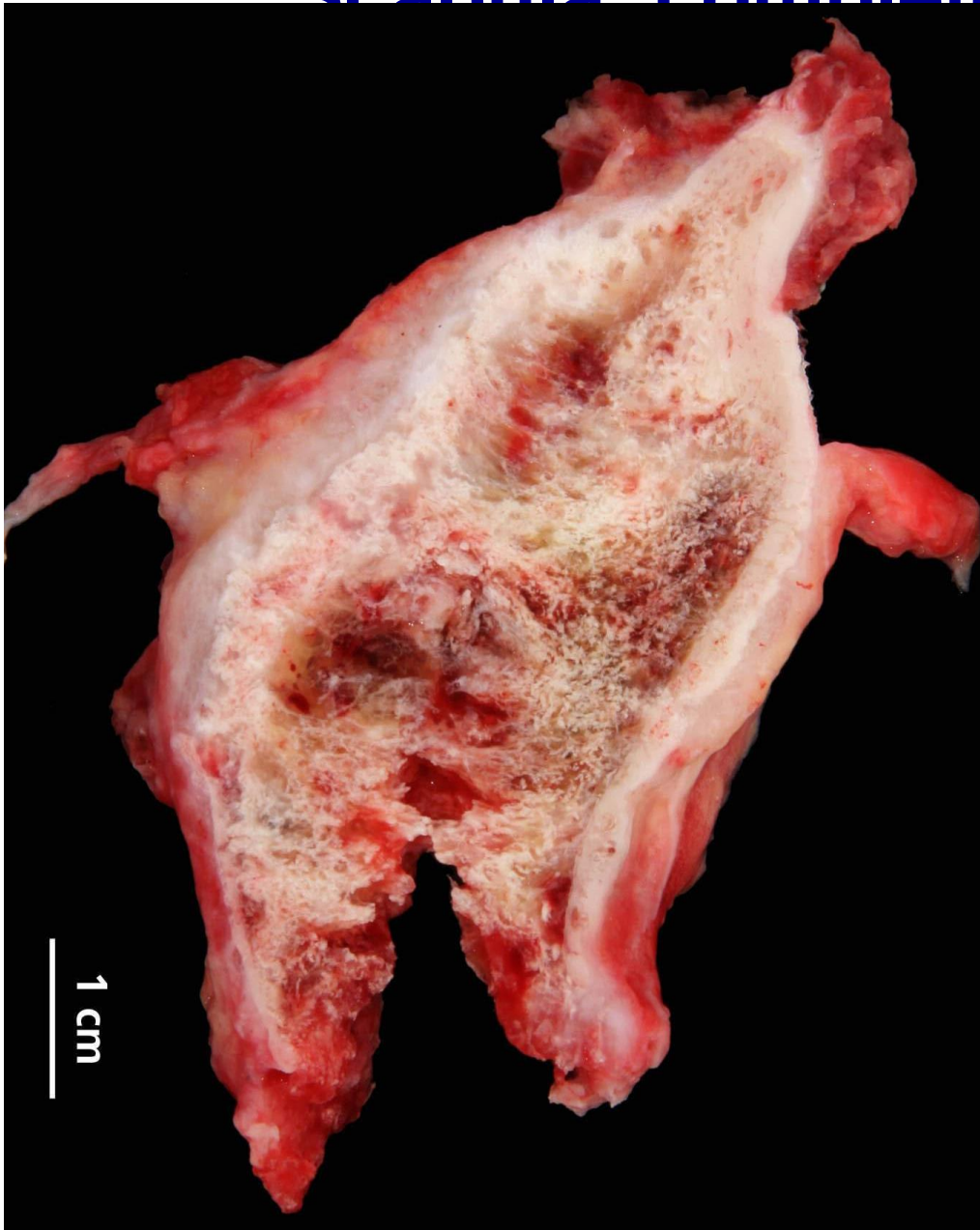Scapula; complete transarticular Histolgy, Mar 22, 2011

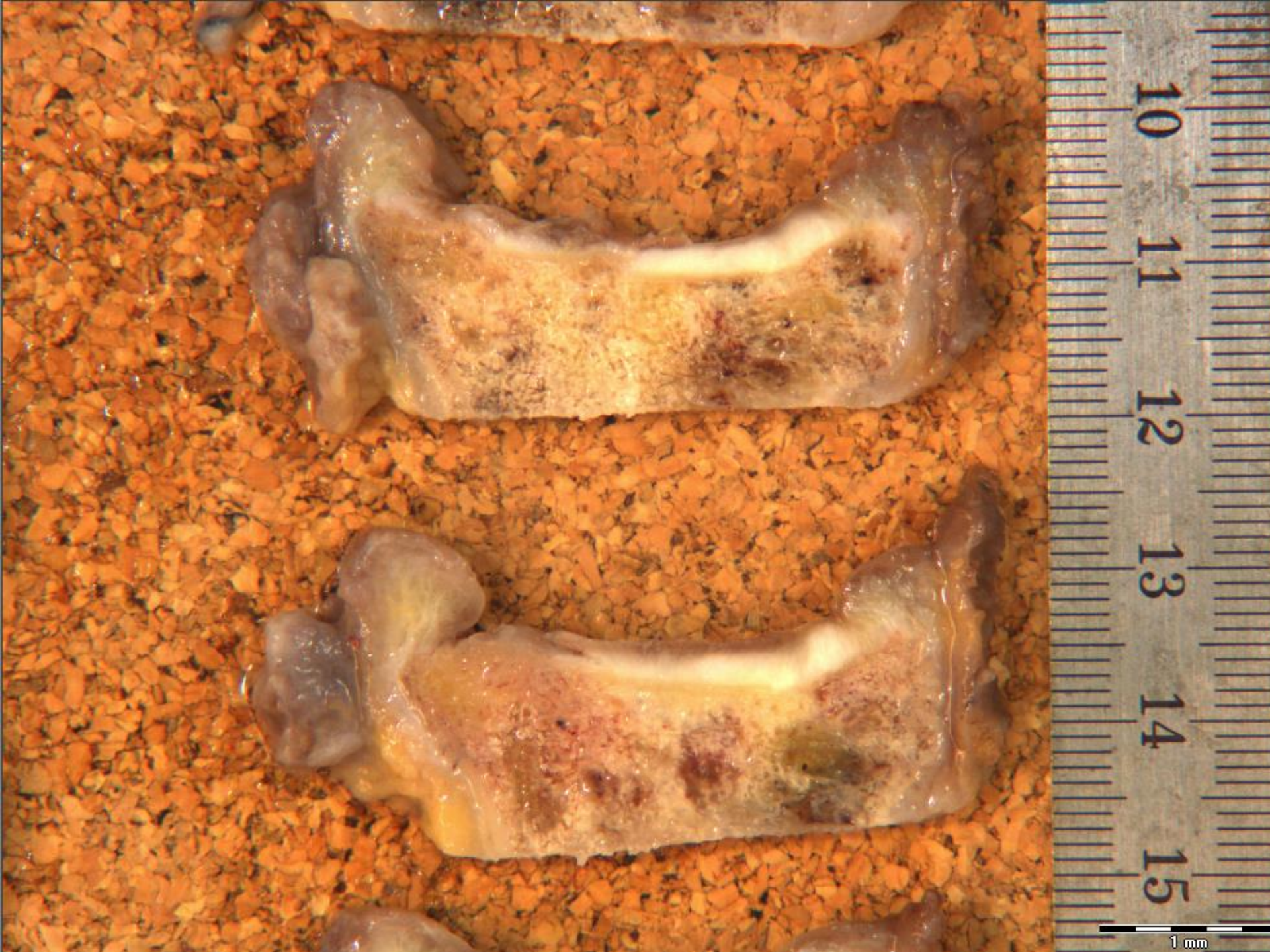

Scapula; complete transarticular Histolgy, Mar 22, 2011



Scapula: complete transarticular

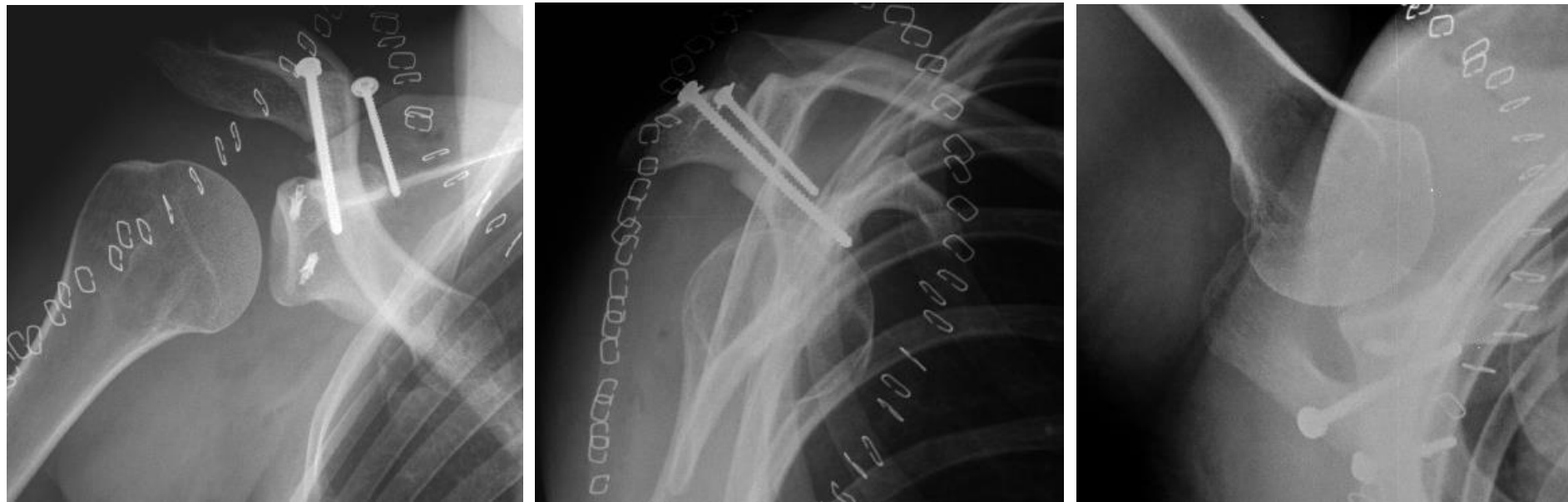



10
11
12
13
14
15

1 mm

Scapula; complete transarticular x-ray R shoulder, Mar 12, 2007



first postoperative X-ray

Scapula; complete transarticular pathology USZ, Mar 12, 2007

Histology B 2007.9457:

**Scapula with sparse vital infiltration of
Ewing's sarcoma**

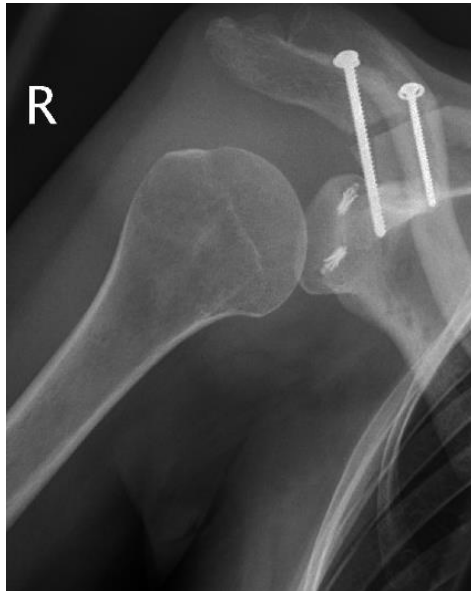Scapula; complete transarticular

Adjuvant ChTx after VAI scheme

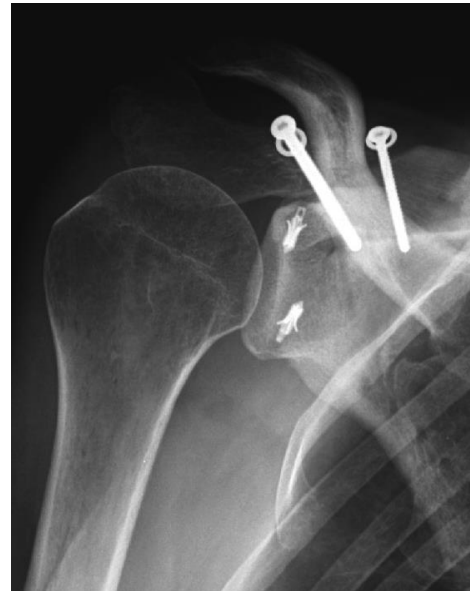Vincristine, Actinomycin, Ifosfamide

27.3.07 - 21.8.07

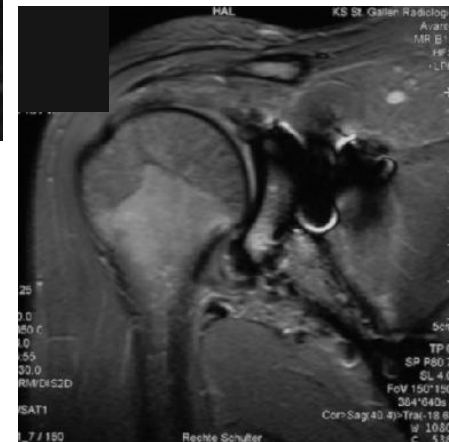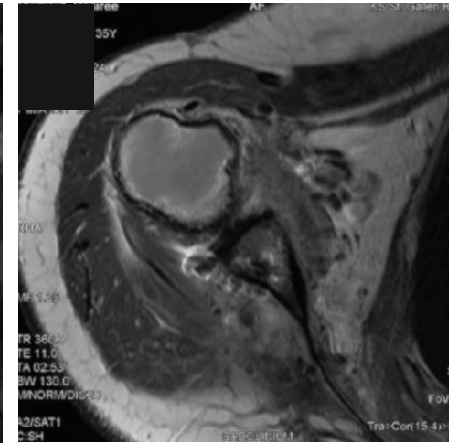
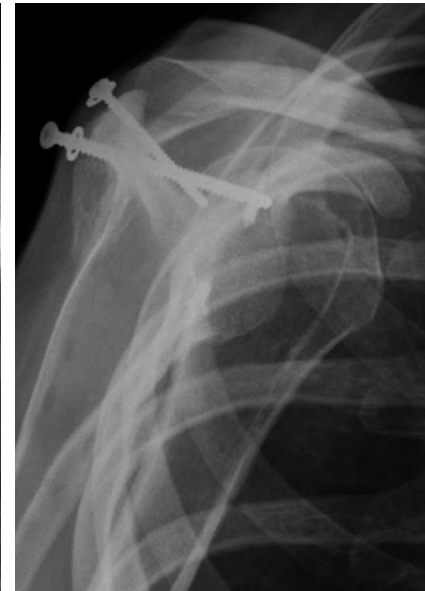Scapula; complete transarticular



6 weeks
25.04.2007

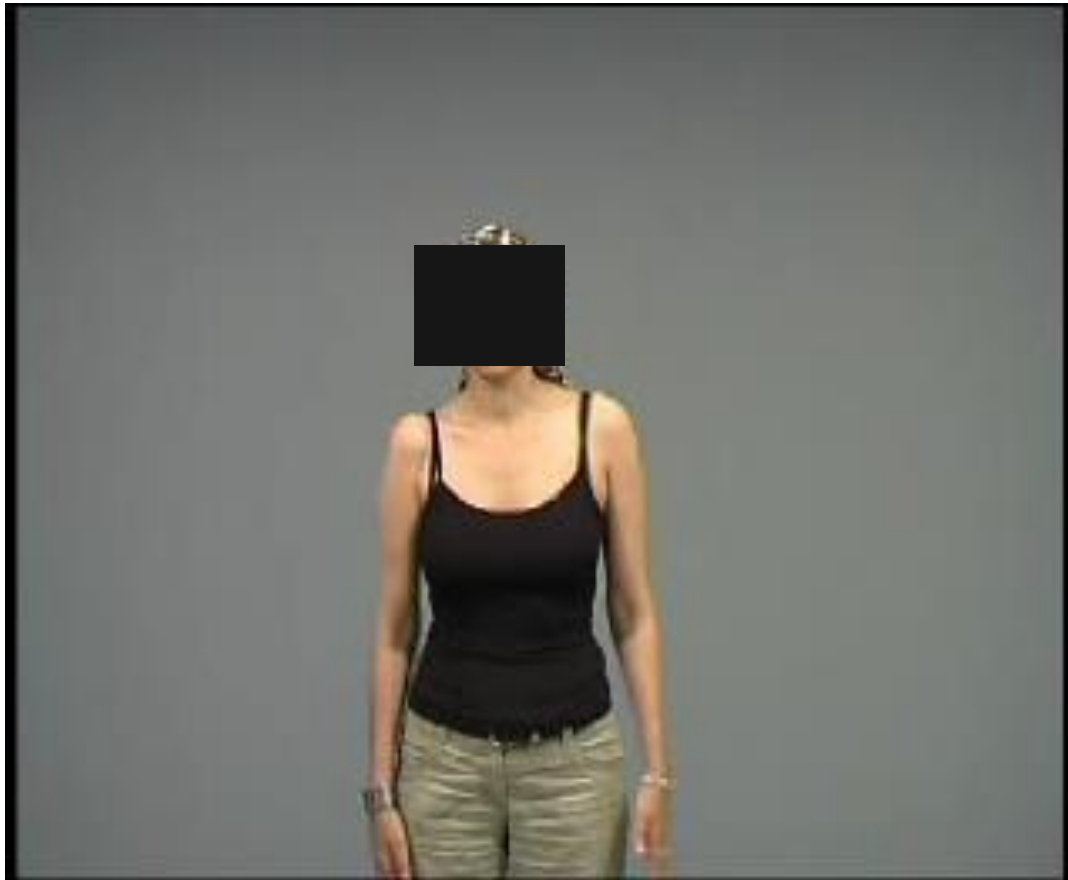

4 month
27.06.2007

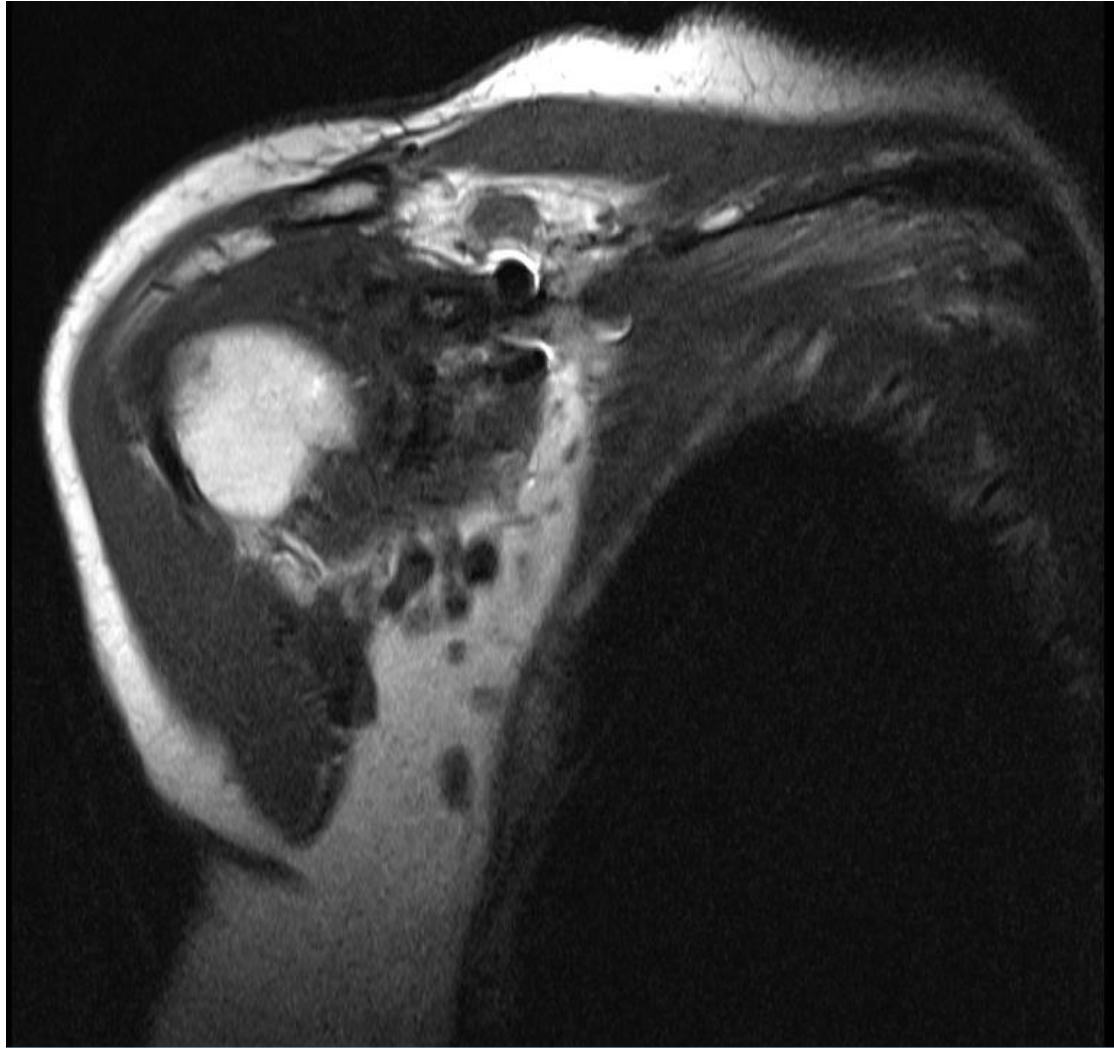


Passive flexion 90 °
IR bottom, ER 20° .
Deltoideus innervated.
Slight crepitation spine of the scapula.

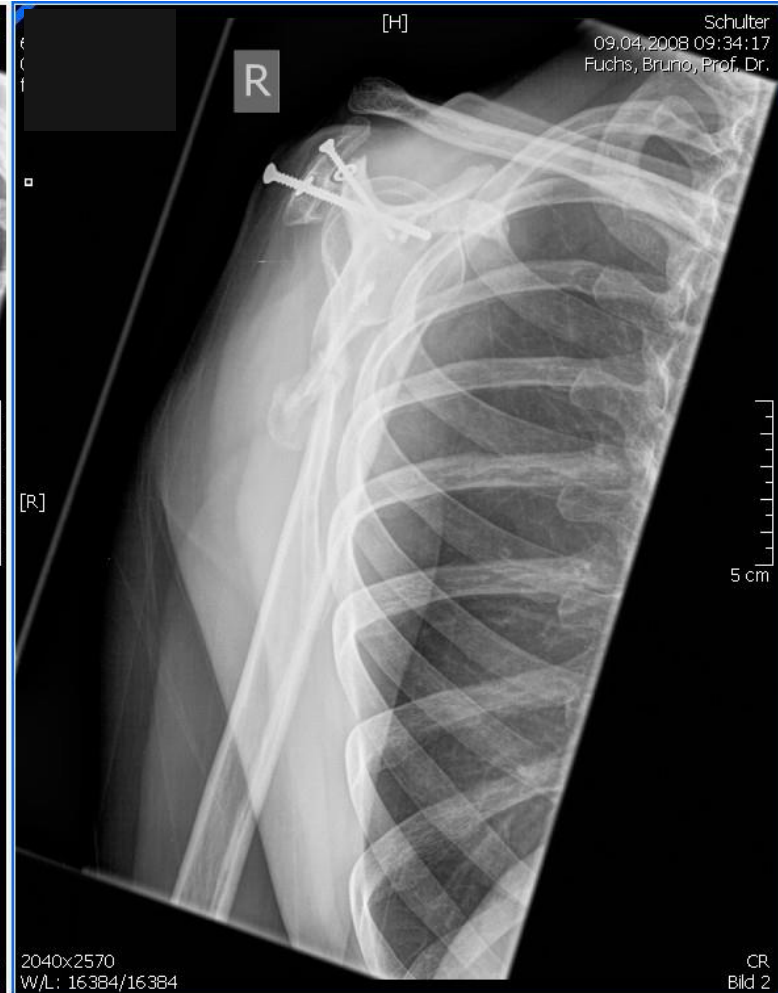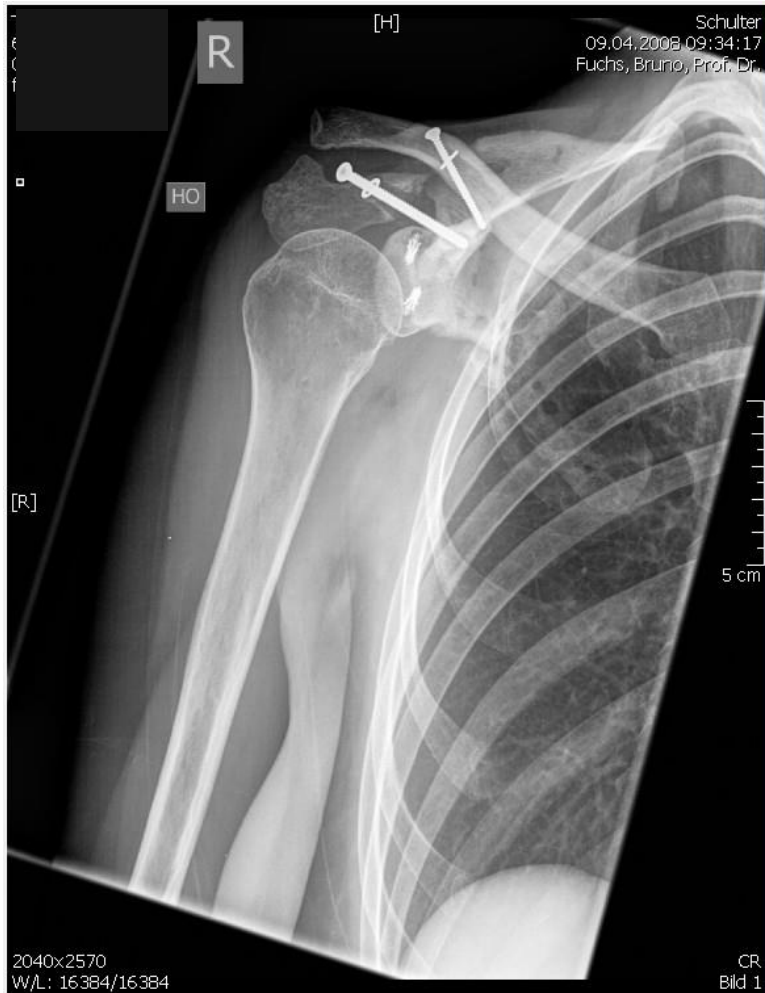Scapula; complete transarticular consultation, Jun 27, 2007



Scapula; complete transarticular MRI R shoulder, Apr 09, 2008 (1 year)



Scapula; complete transarticular x-ray R shoulder, Apr 09, 2008 (1 year)



Scapula; complete transarticular surgery, May 29, 2008

screw removal + biopsy

Histology USZ B2008.21722:

**Locally recurrent Ewing's sarcoma,
removed in toto in the healthy**

Scapula; complete transarticular

RT 5.08 - 19.09.2008

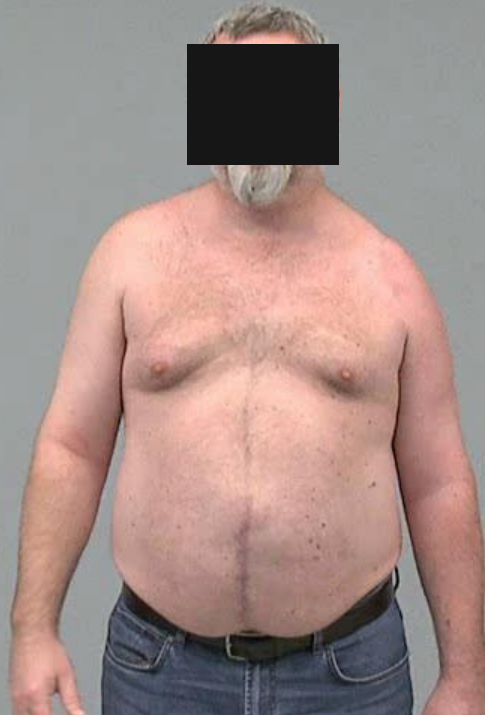2x33Gy Boostdosis

Scapula; complete transarticular

Staging with MRI shoulder and CT chest every 3 month

- no evidence of recurrence**
- no metastases**

Scapula; complete transarticular Urachus Metastasis 6ms postop



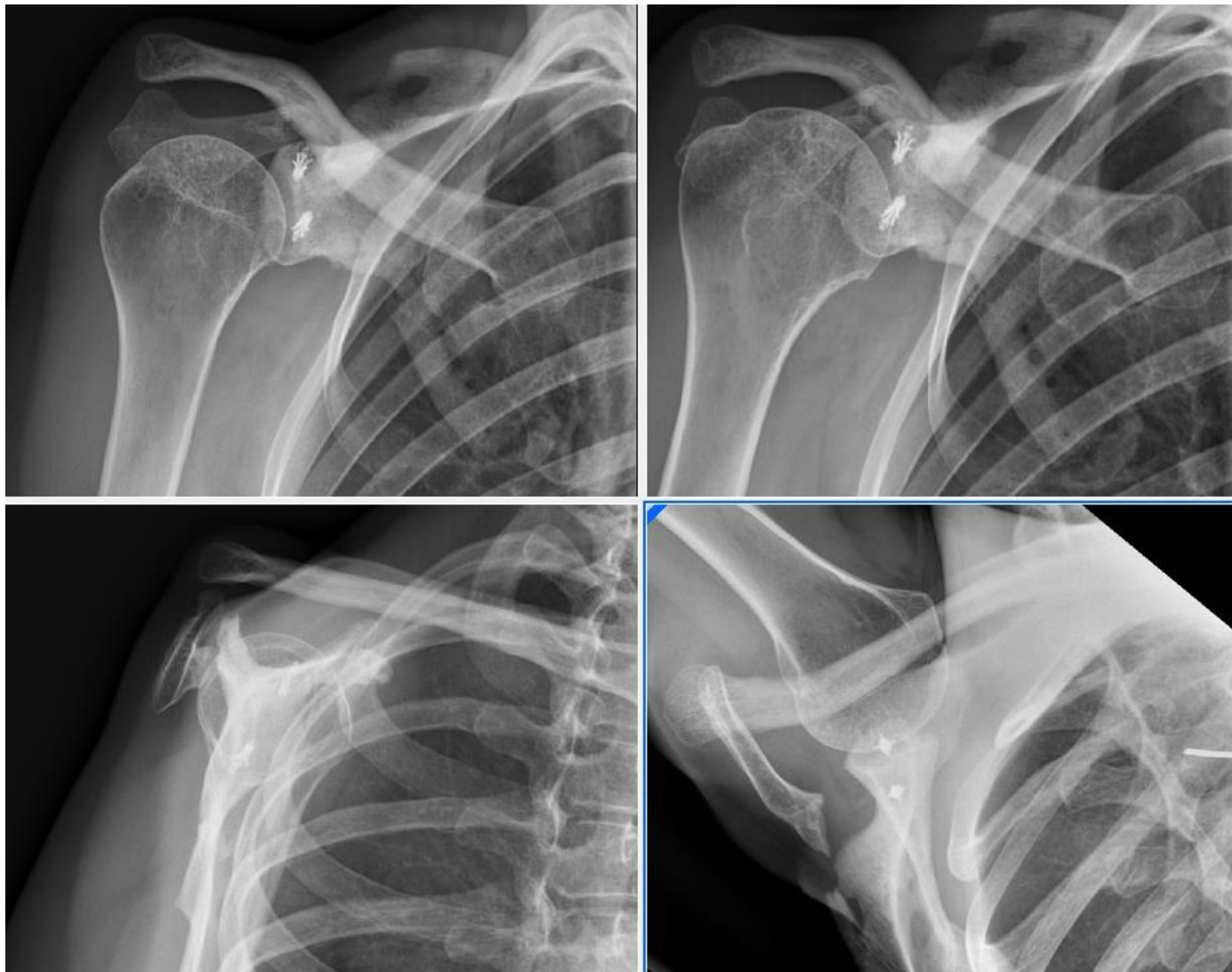
Scapula; complete transarticular consultation, Dec 12, 2008



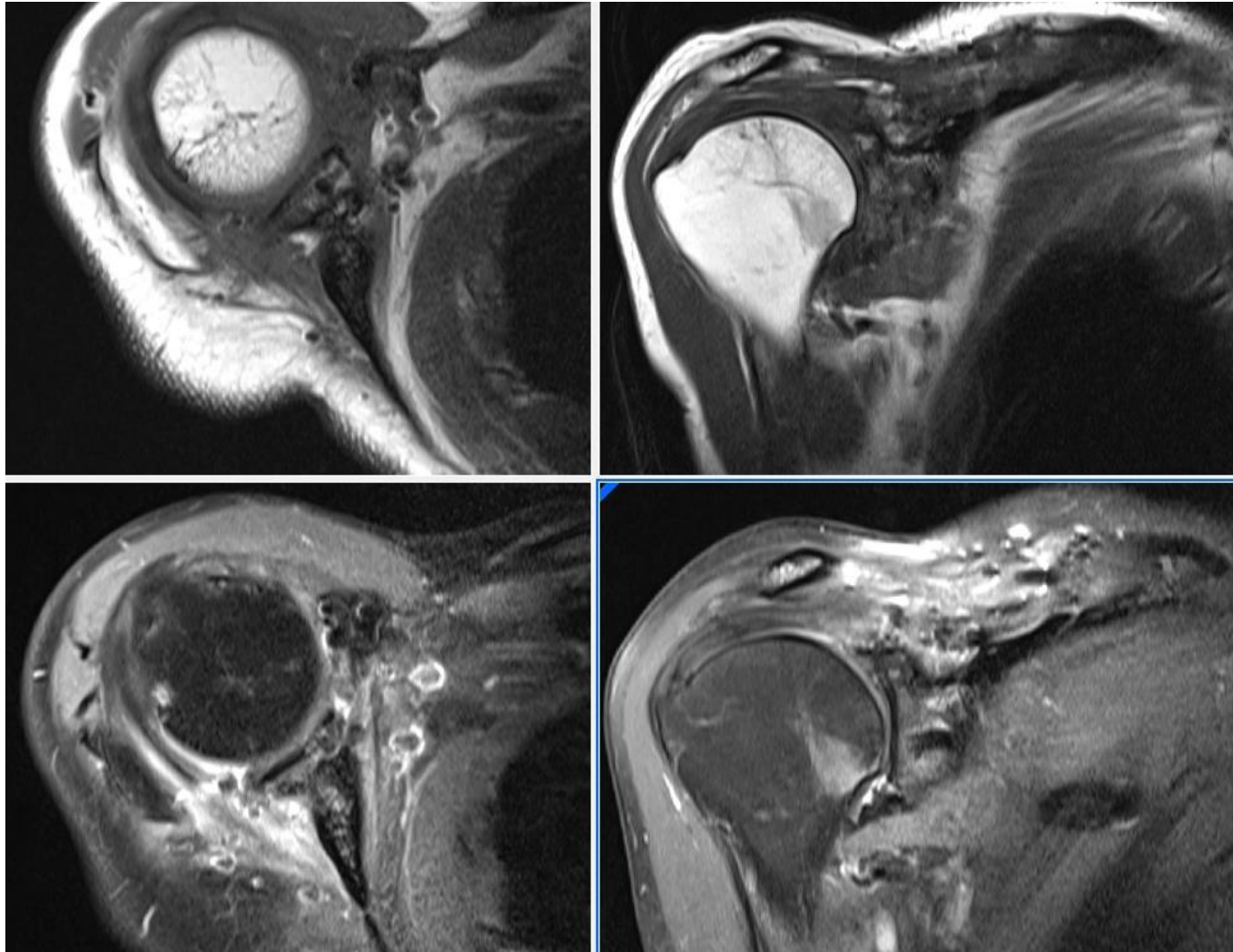
Scapula; complete transarticular consultation, Oct 28, 2009



Scapula; complete transarticular x-ray R shoulder, Jul 28, 2010



Scapula; complete transarticular MRI R shoulder, Nov 10, 2010



Scapula; complete transarticular MRI shoulder, Jan 09, 2017

