

# Finger; metacarpal transfer

♂ 35yo, teacher

1st referral: May 27, 2013

## HPI:

- Noticed small hard lump at the proximal phalanx Dig III 5 years ago
- Wait and see
- Increasing in size to about 2x1cm
- Never pain and not disturbed for a long time
- Z-plasty Resection by suspected giant cell tumor on May 1, 2013
- Histology → epithelioid sarcoma R1-Resection

## PMH:

- Healthy

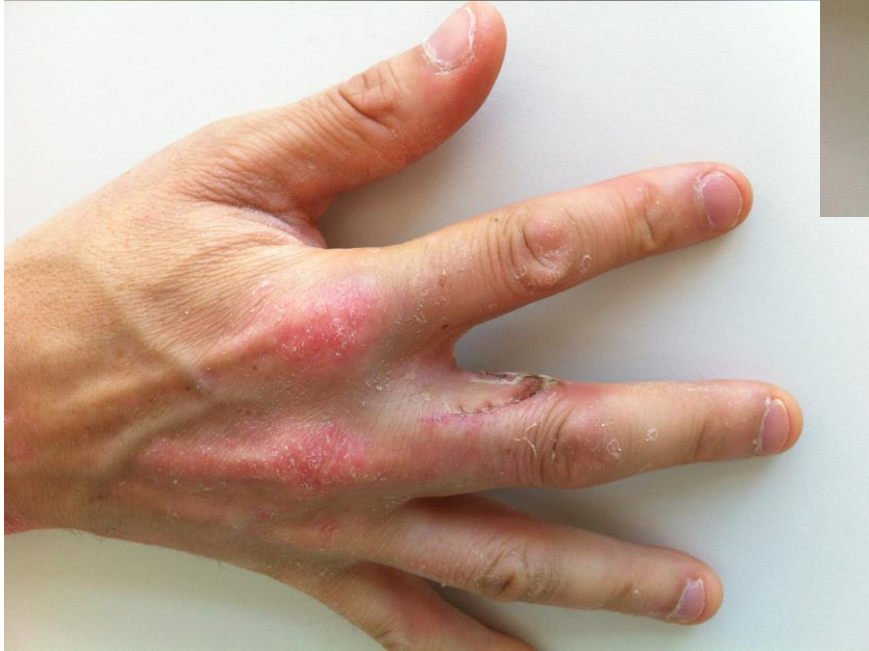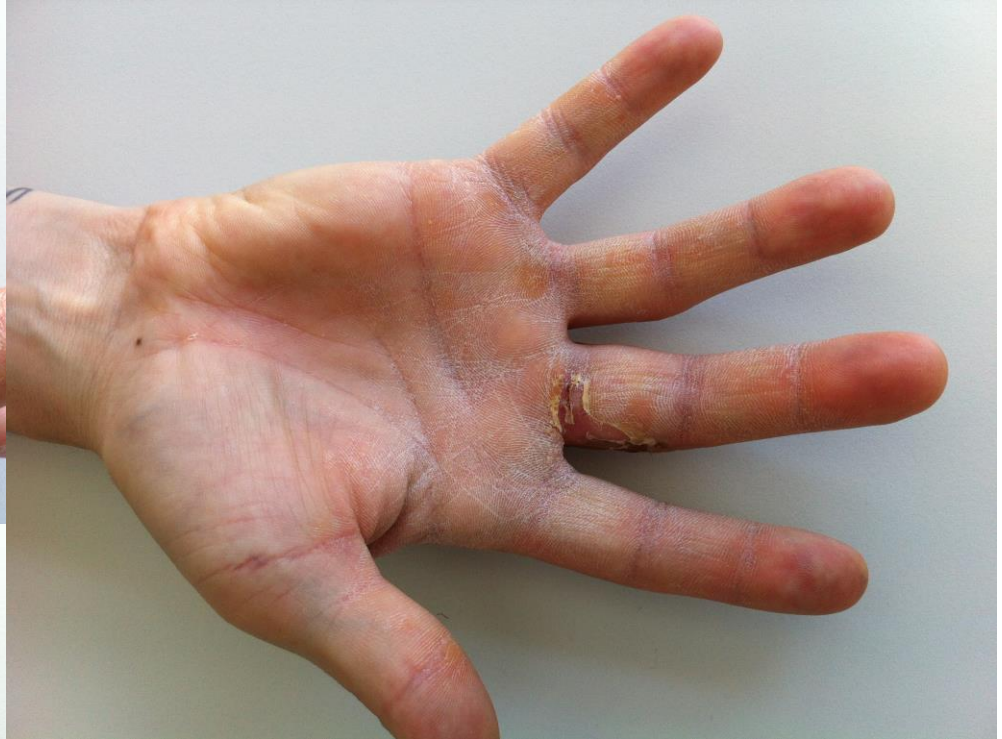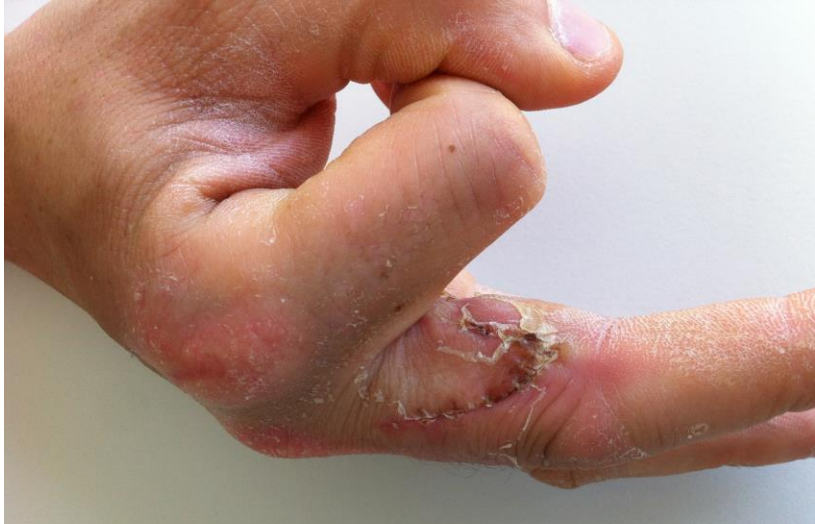# Finger; metacarpal transfer

## Clinical findings:

- Scar without signs of an infection
- Normal hand function
- Normal sensibility

# Finger; metacarpal transfer

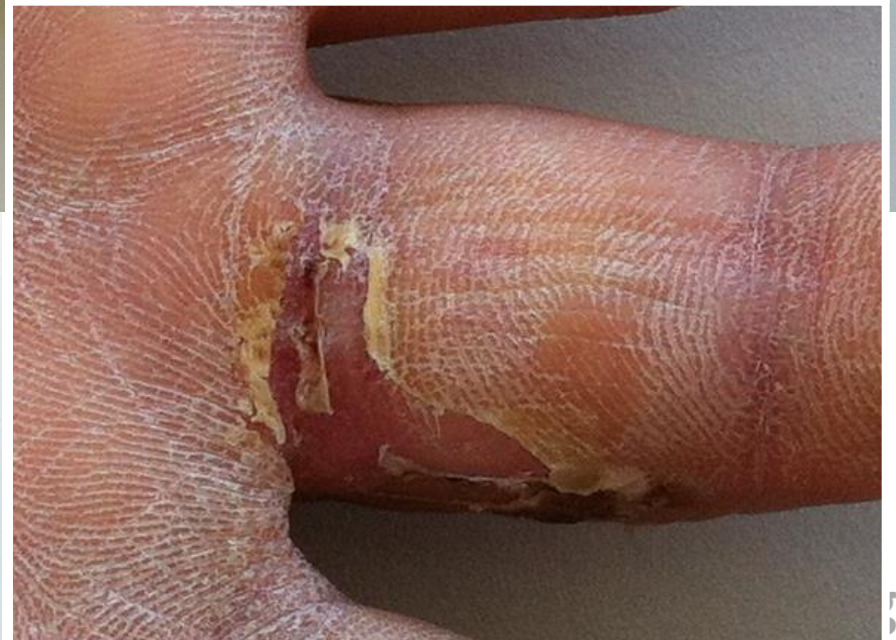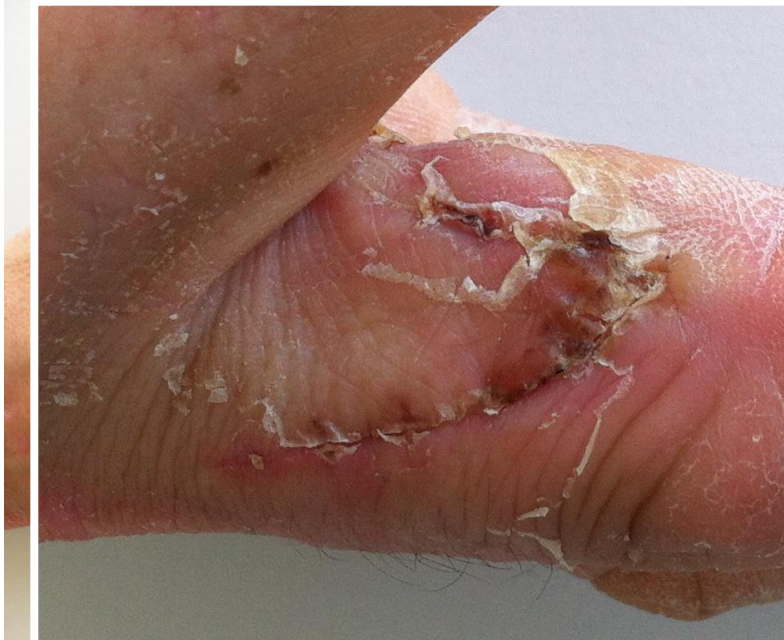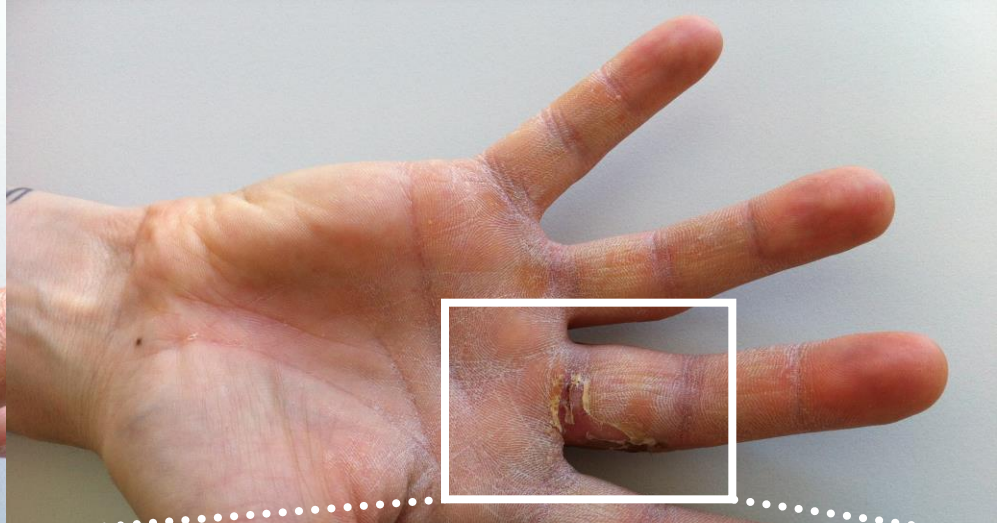
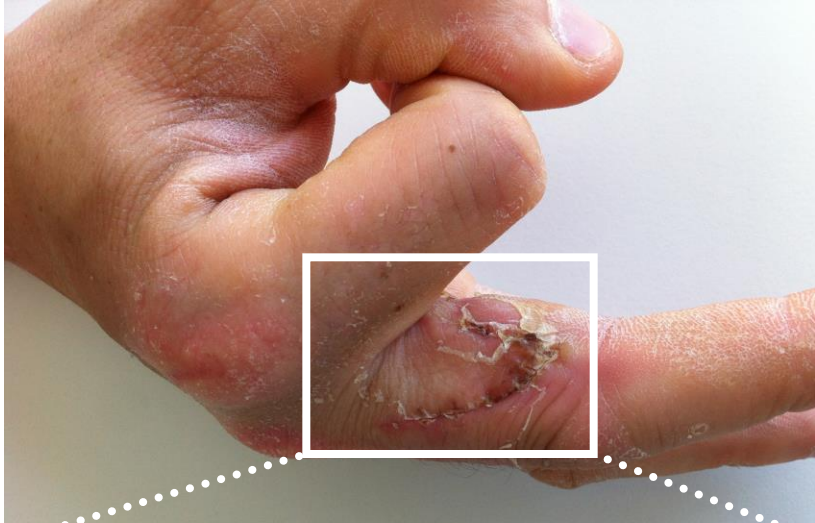1st referral: May 27, 2013





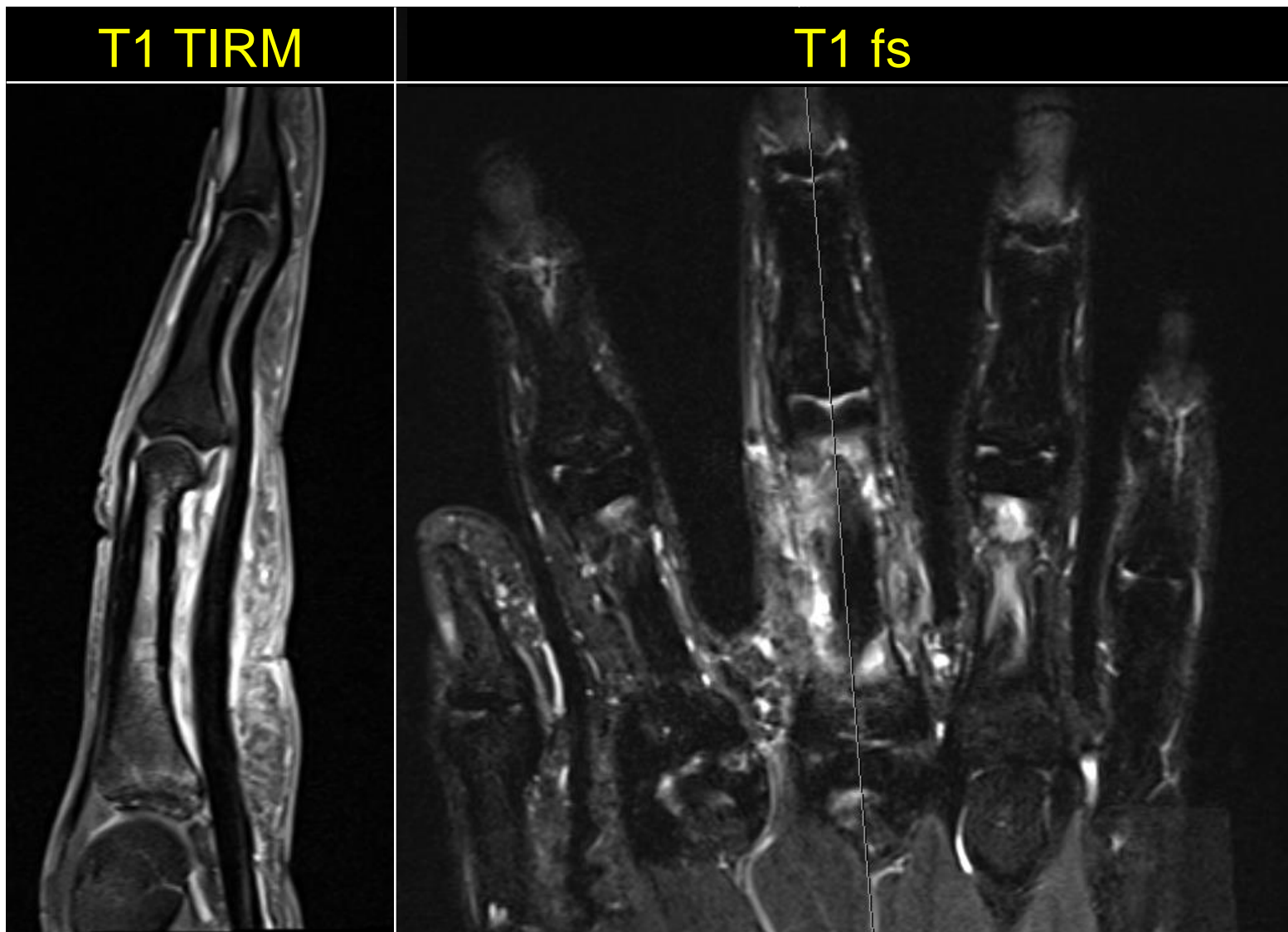
# Finger; metacarpal transfer

1st referral: May 27, 2013



# Finger; metacarpal transfer

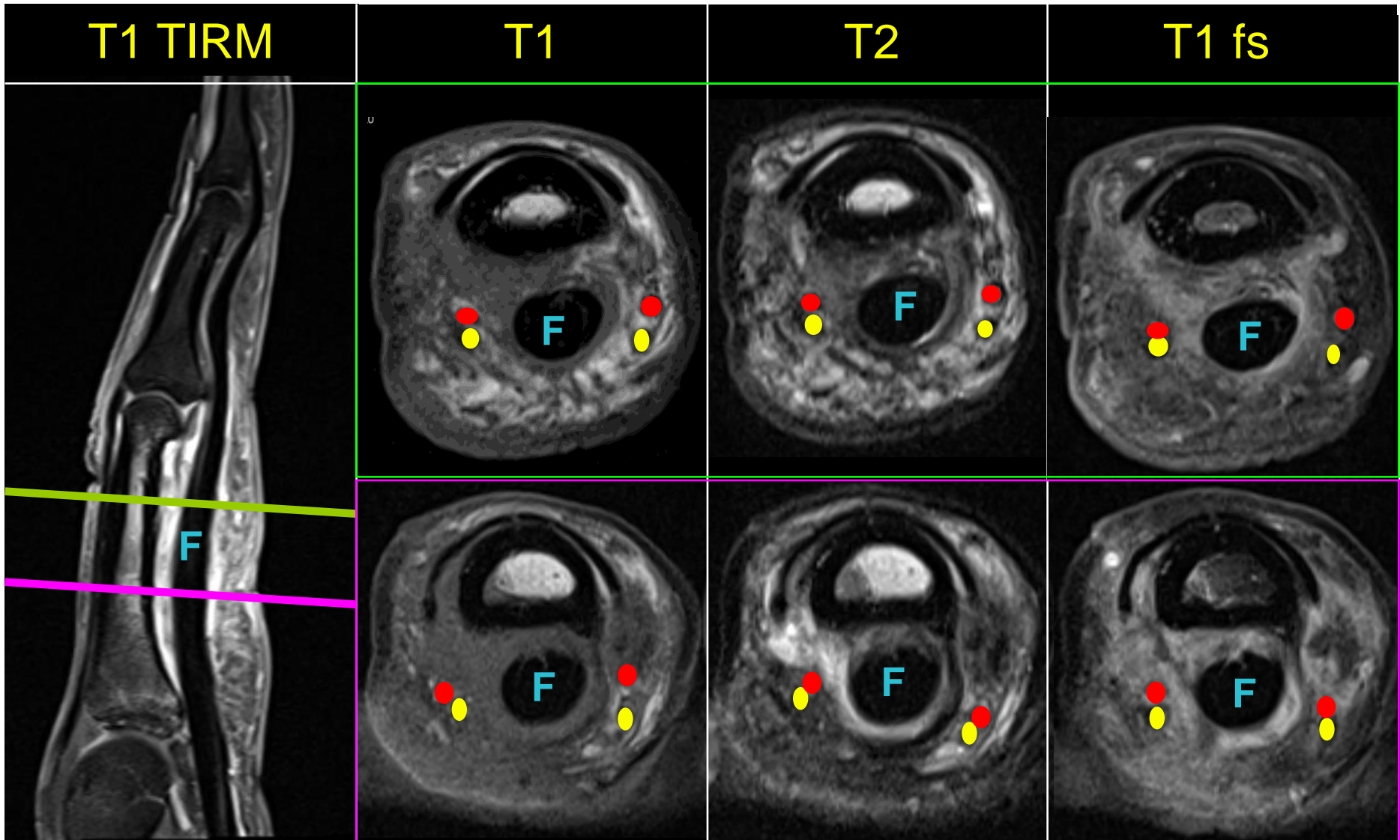
## MRI hand right: May 27, 2013





# Finger; metacarpal transfer

## MRI hand right: May 27, 2013



# **Finger; metacarpal transfer**

## **Sarcoma- Board: June 6,2013**

**Therapeutic decisions:**

**Radiotherapy:**

**Yes, after surgery an adjuvant RT is recommended**

**Chemotherapy:**

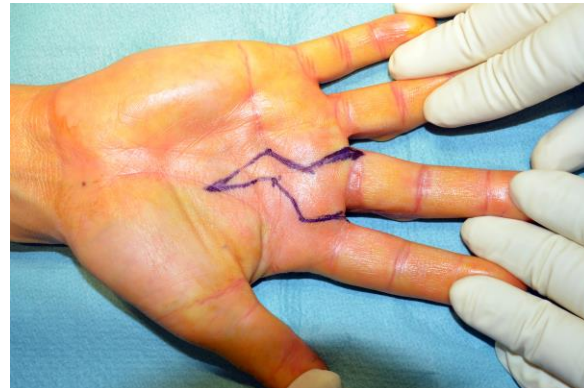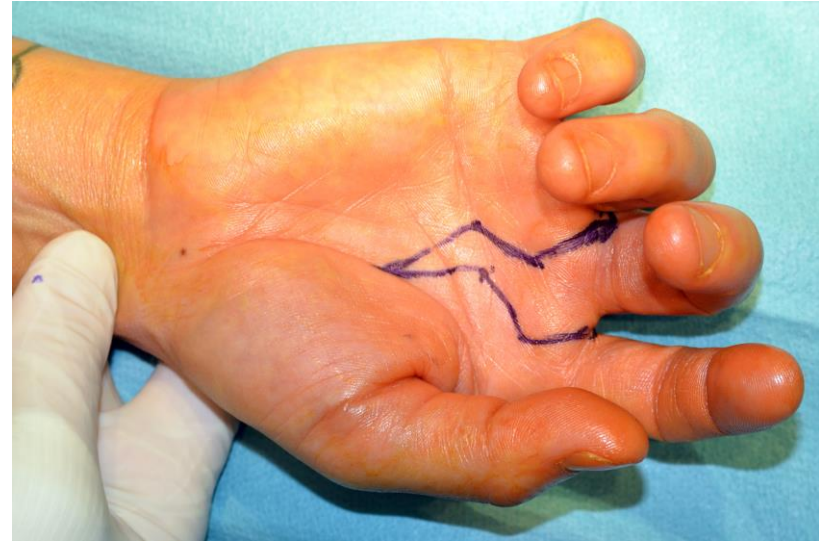
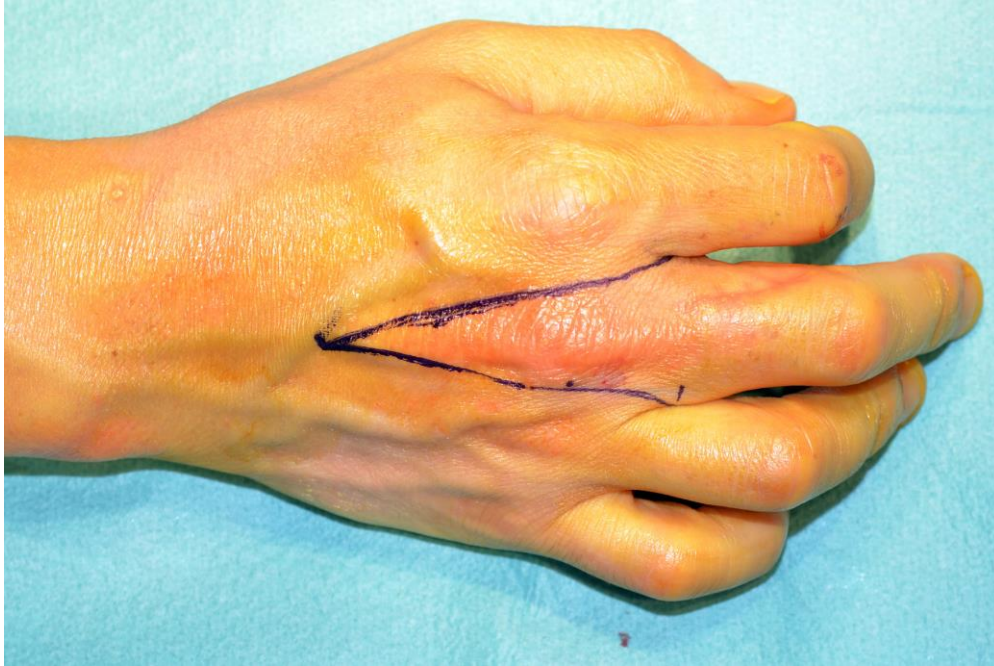**No**

**Surgery:**

**Yes**

# Finger; metacarpal transfer

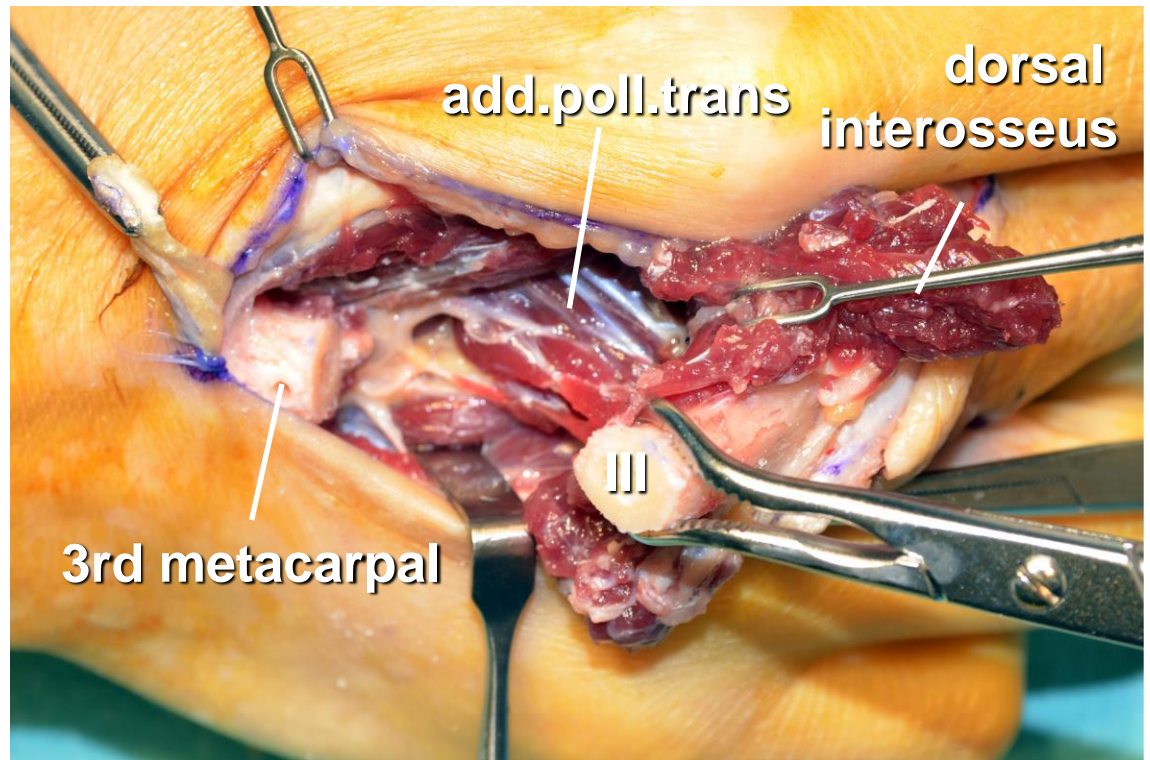
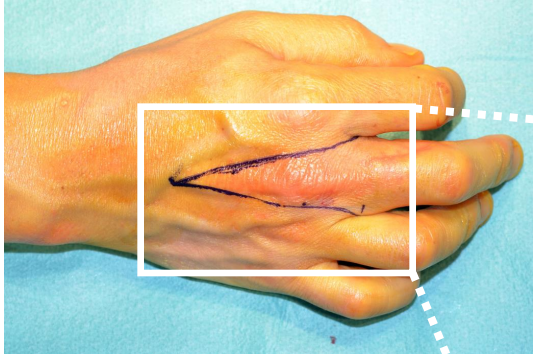
## Surgery: July 09, 2013





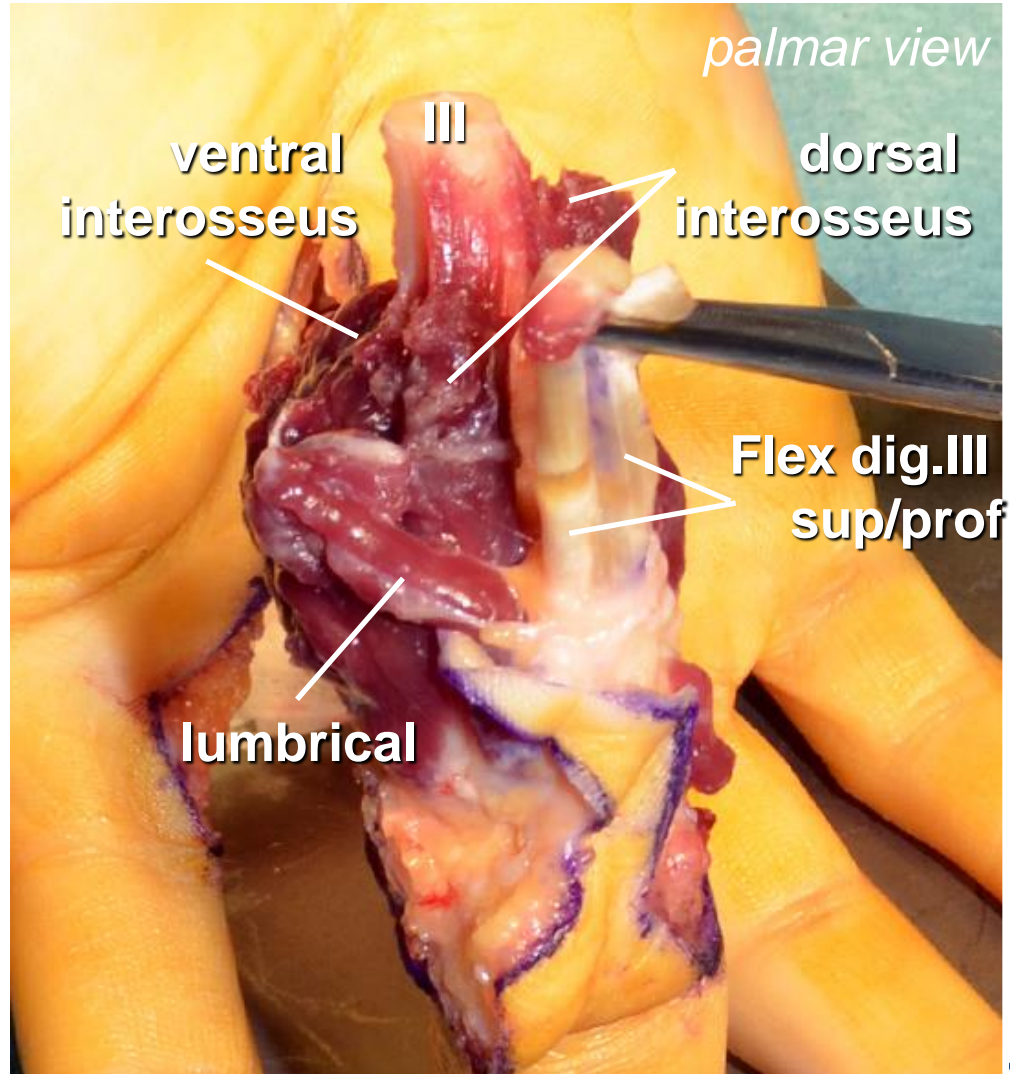
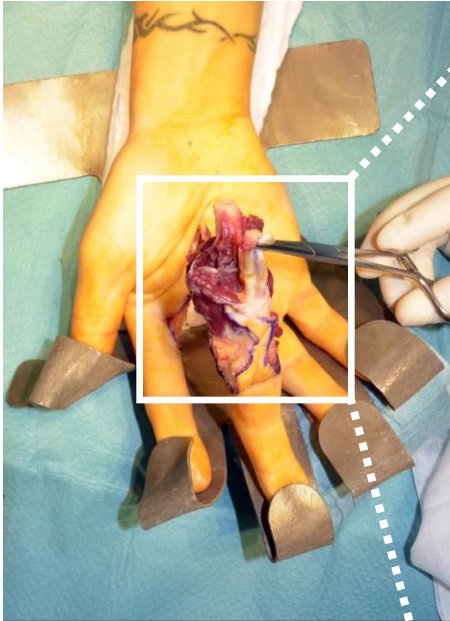
# Finger; metacarpal transfer

## Surgery: July 09, 2013



# Finger; metacarpal transfer

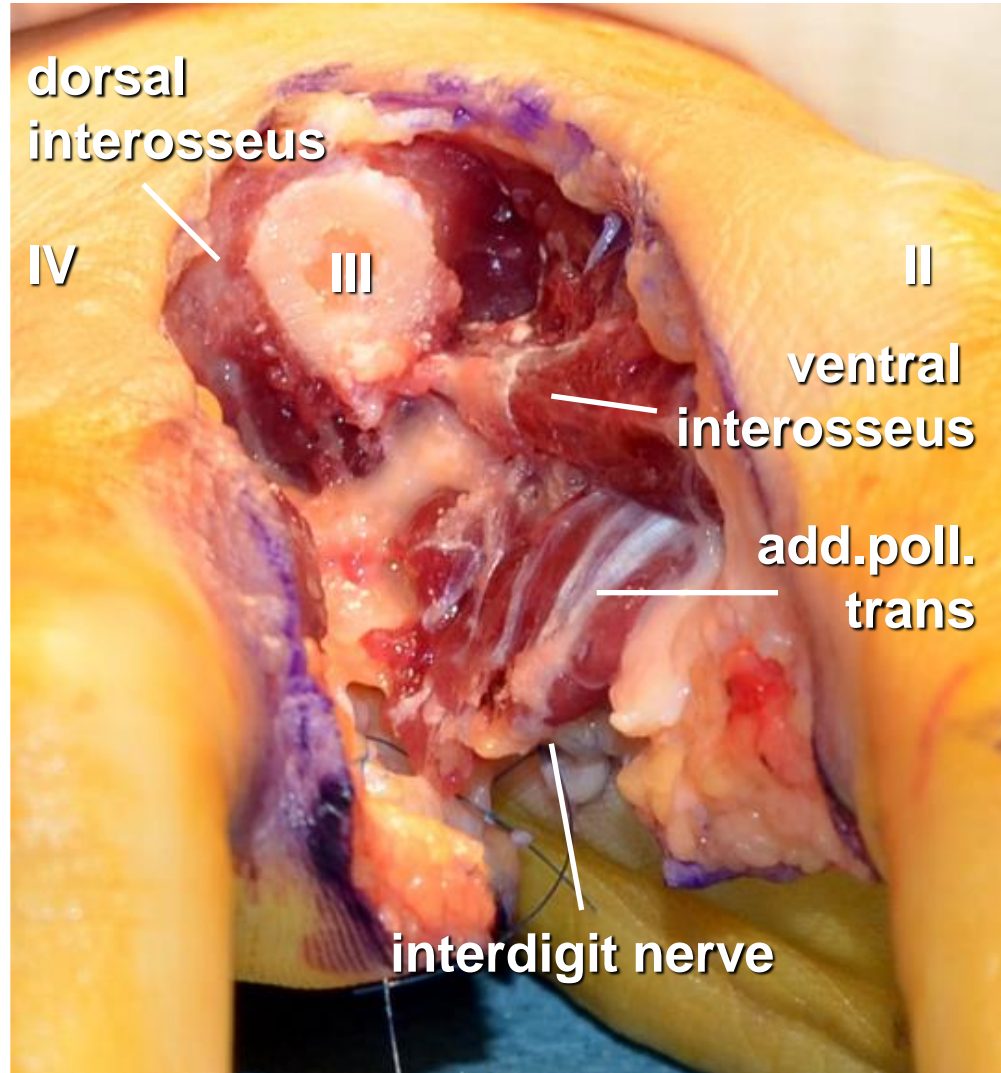
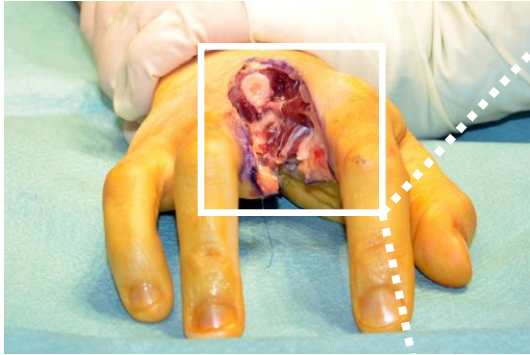
## Surgery: July 09, 2013





# Finger; metacarpal transfer

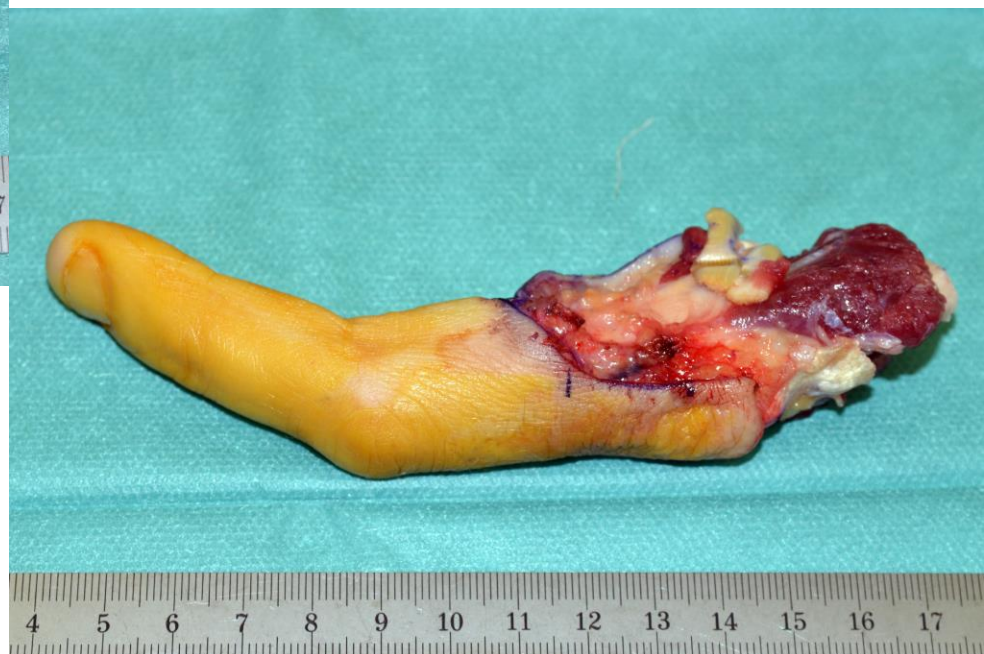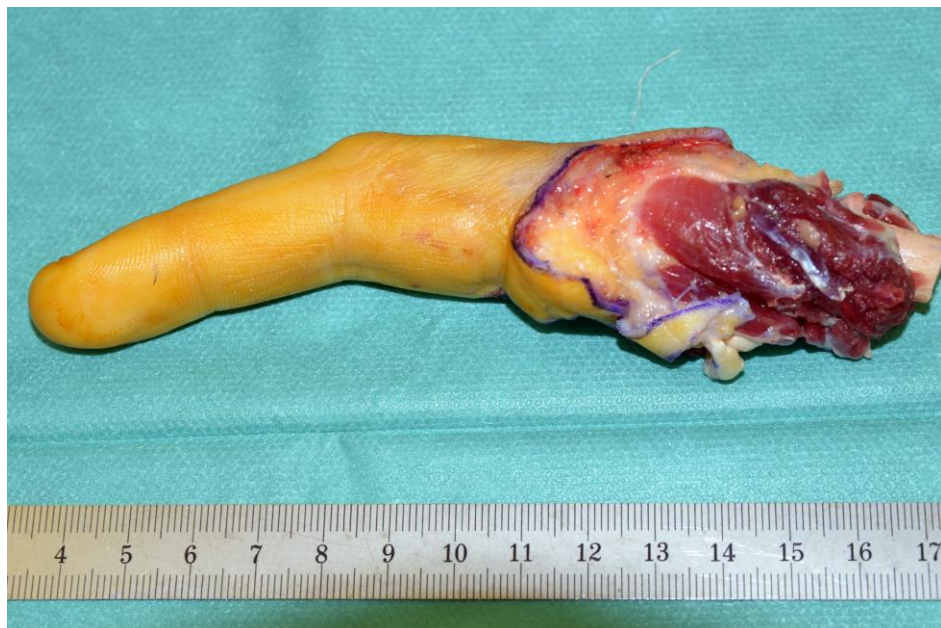## Surgery: July 09, 2013





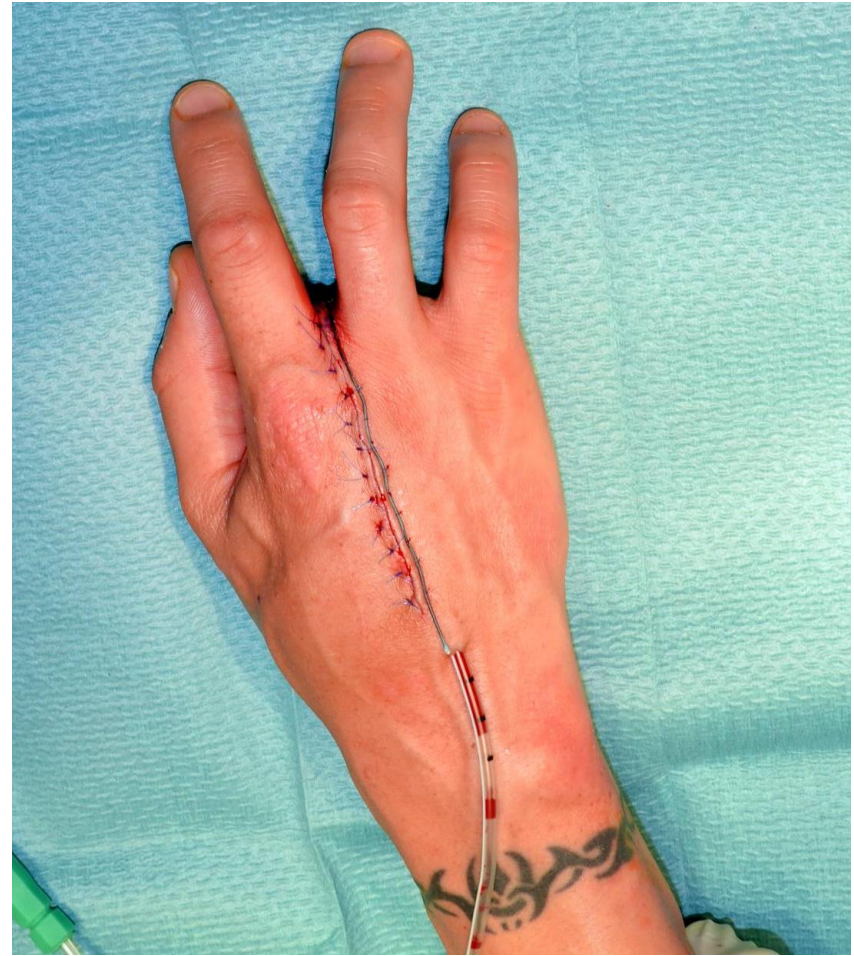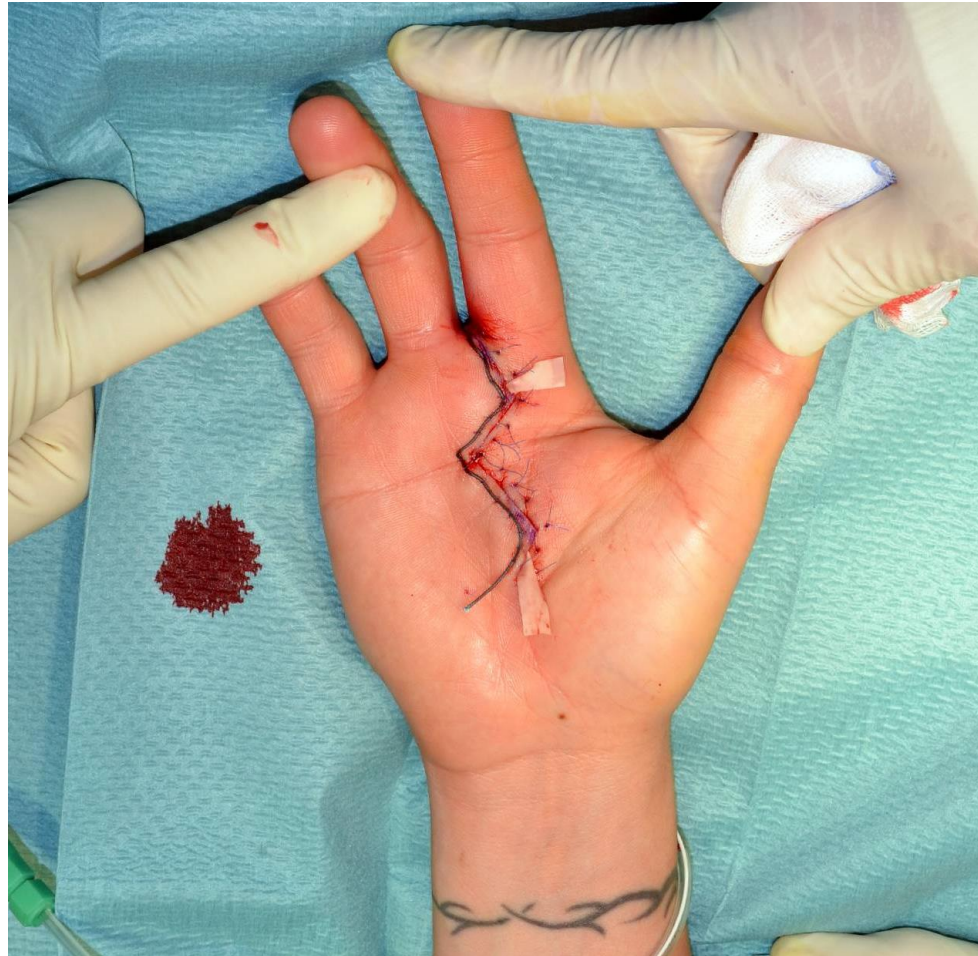
# Finger; metacarpal transfer

## Surgery: July 09, 2013



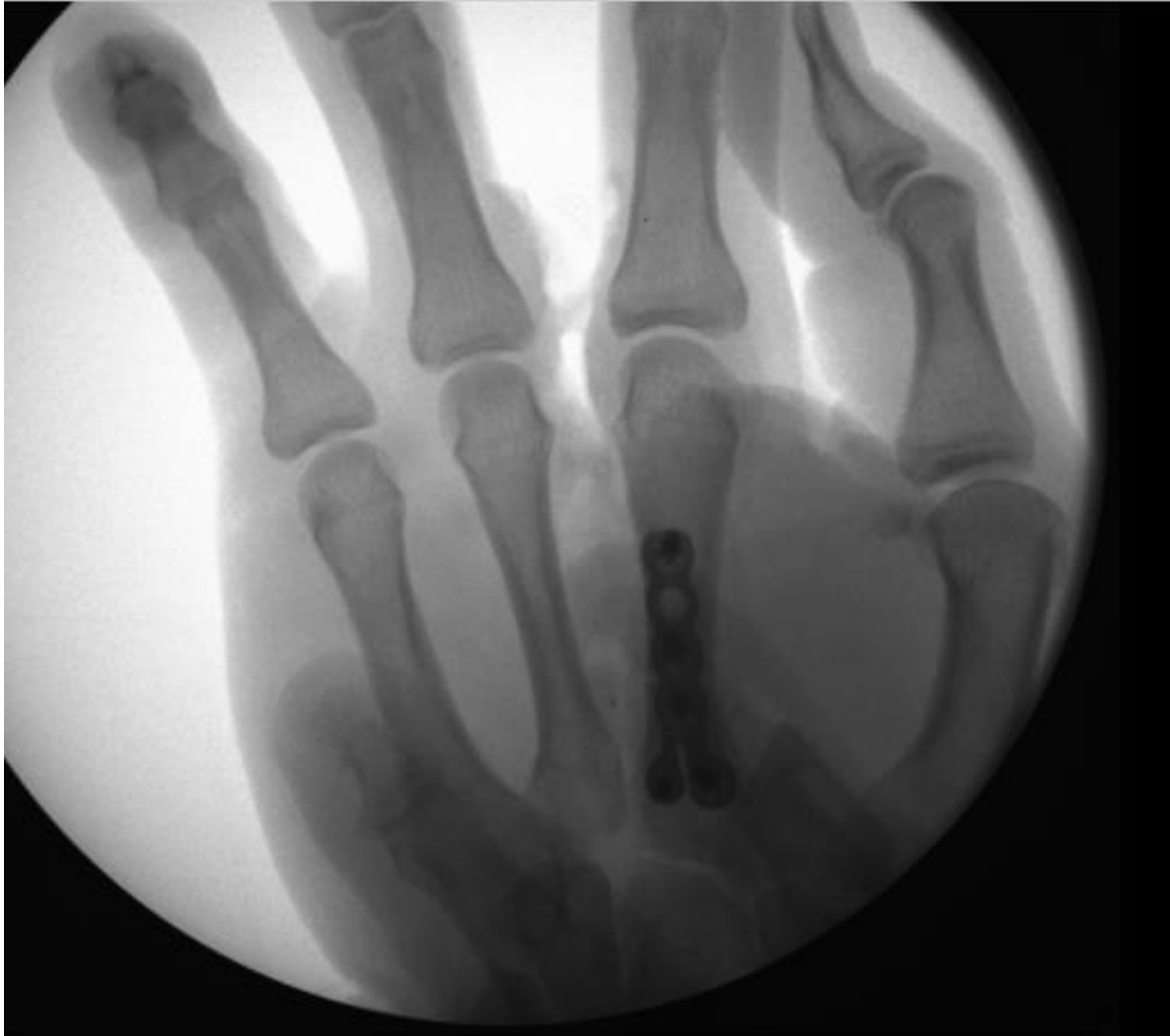# Finger; metacarpal transfer

## Surgery: July 09, 2013

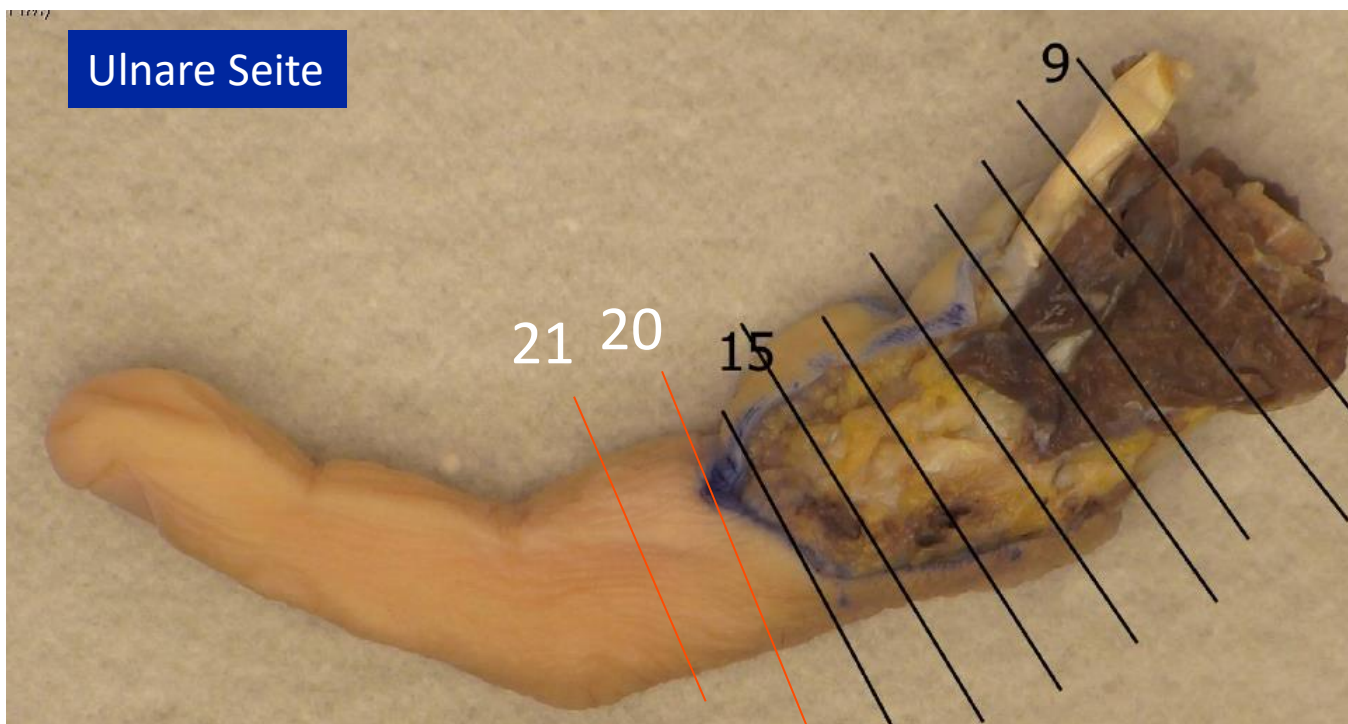
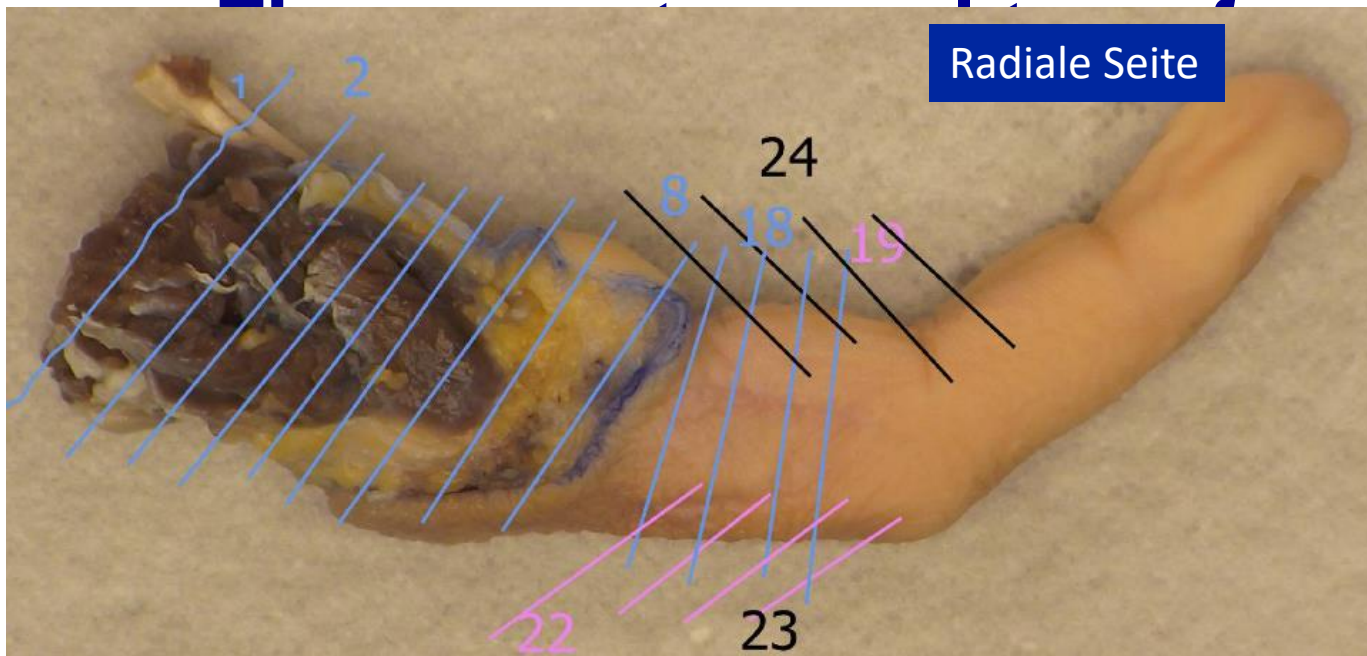




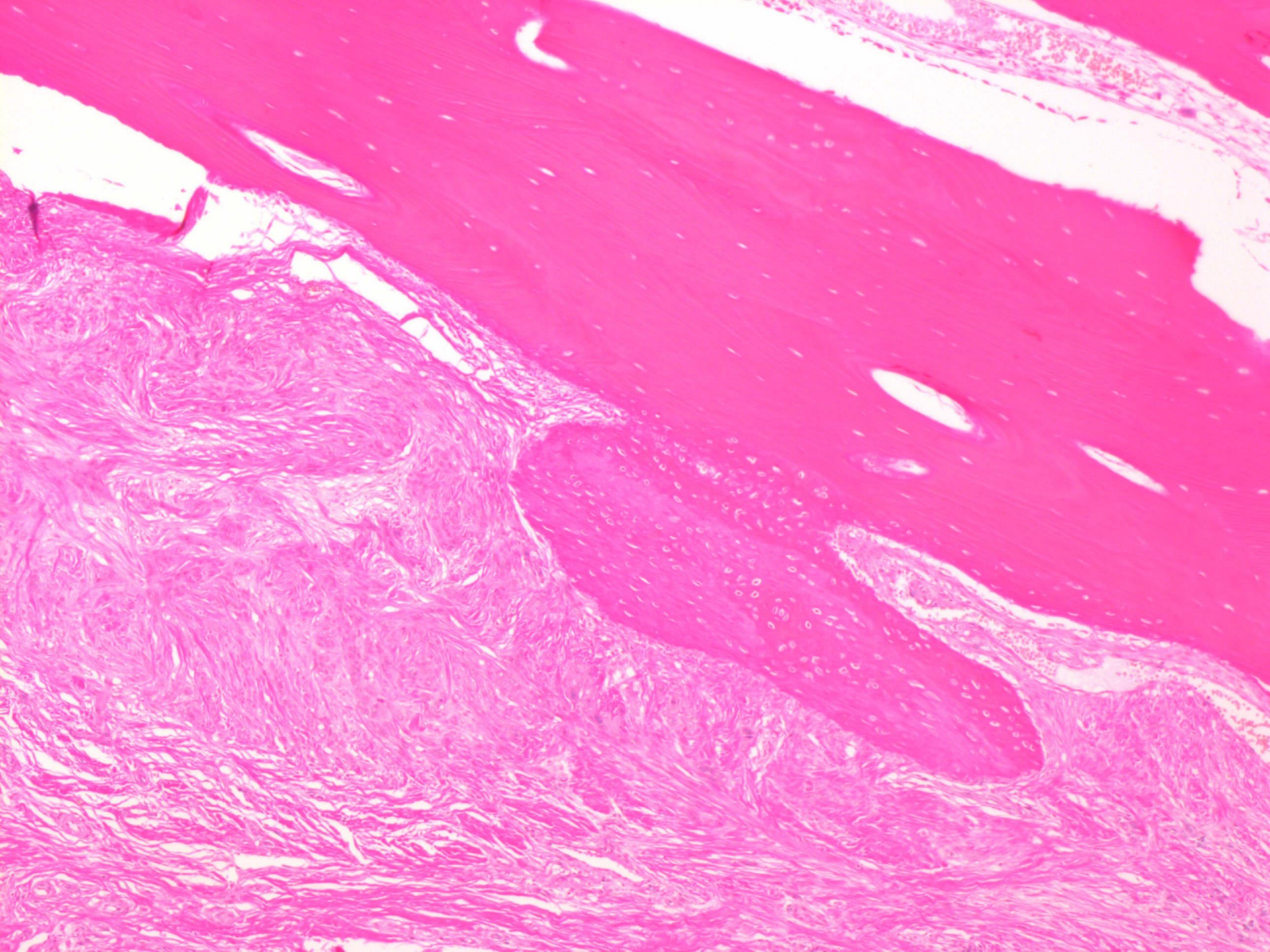
# Finger; metacarpal transfer intra-op. Rx, July 09, 2013



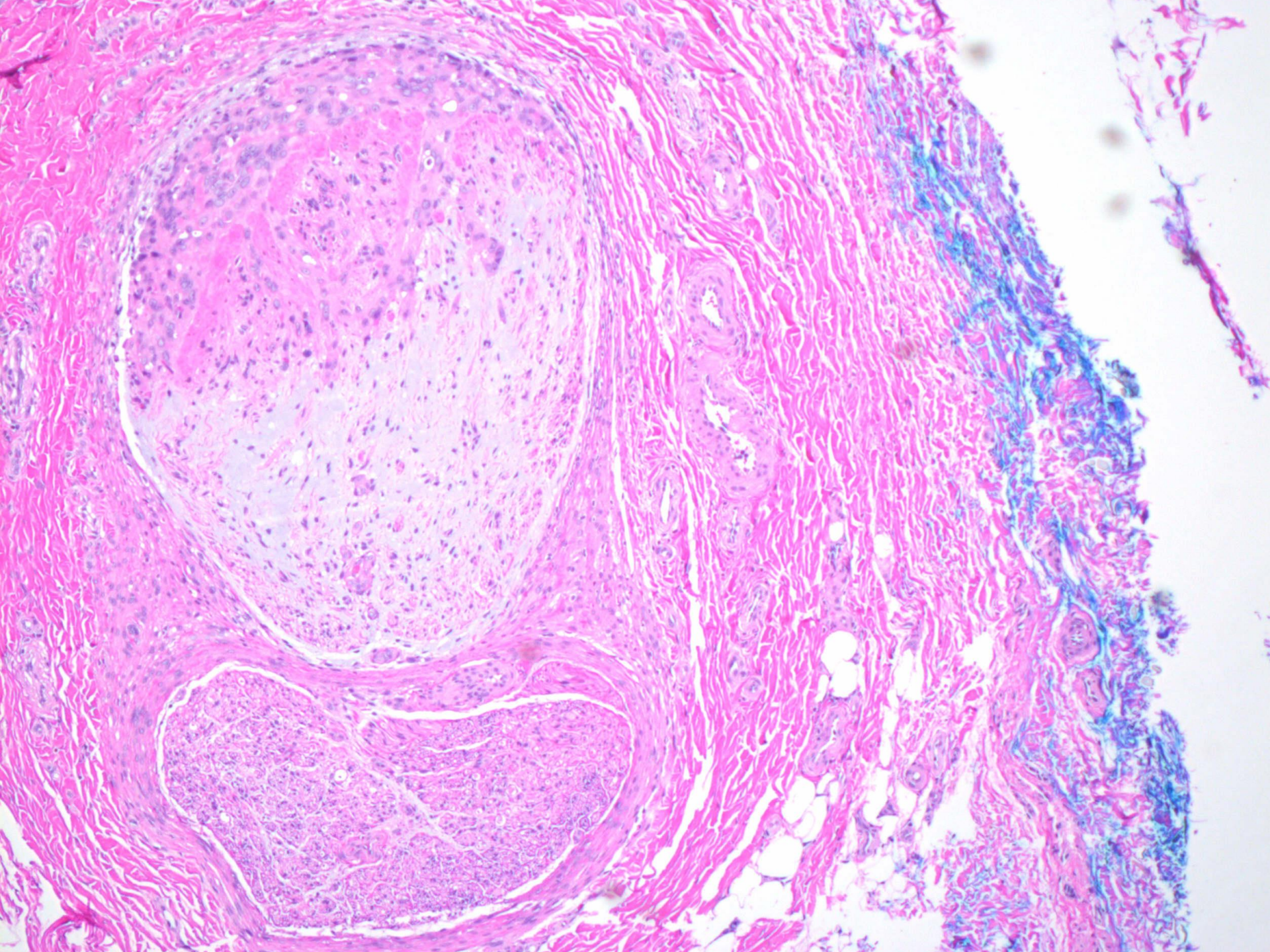




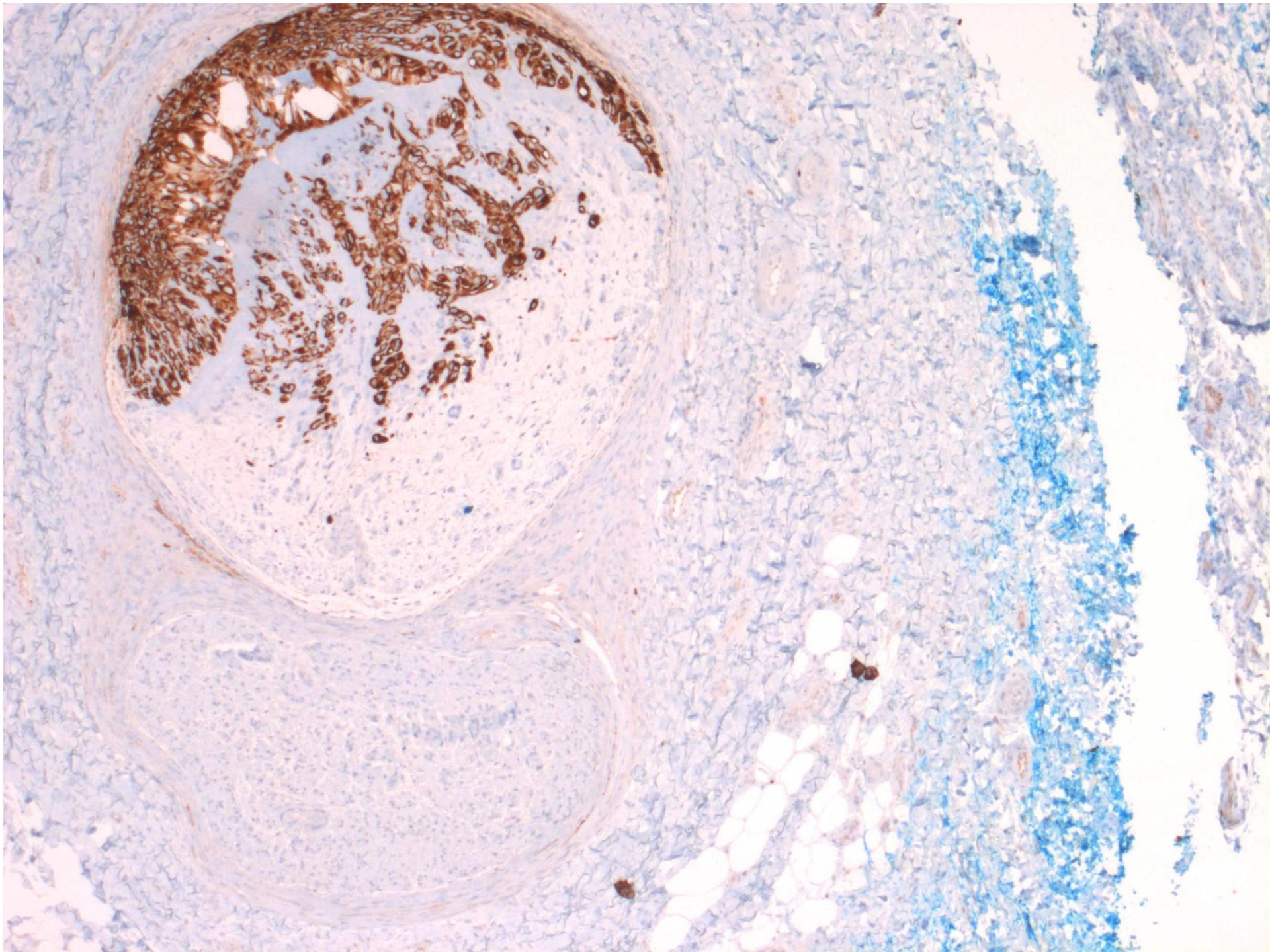












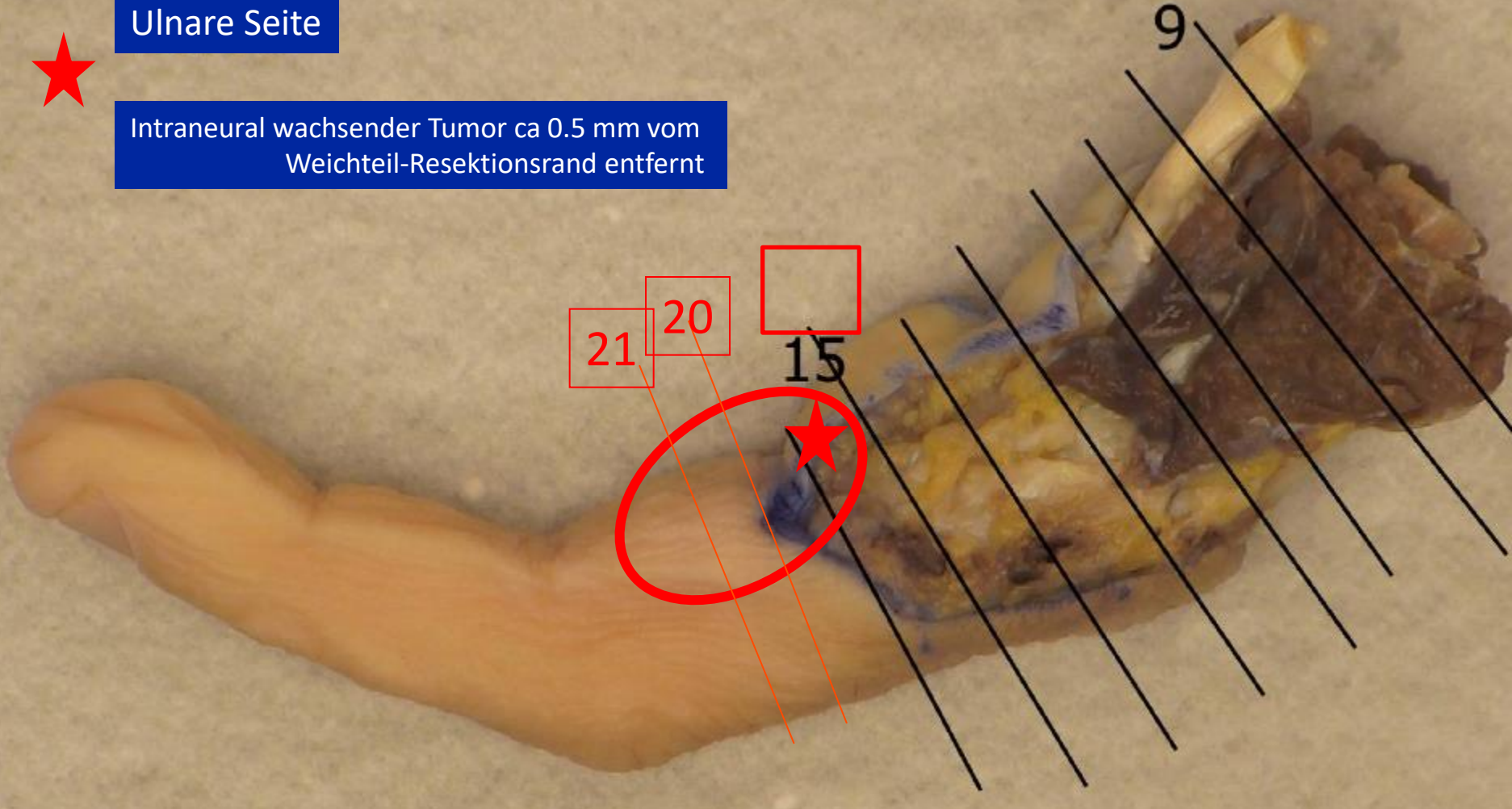




# Finger; metacarpal transfer pathology July 09, 2013

★ Ulnare Seite

Intraneural wachsender Tumor ca 0.5 mm vom Weichteil-Resektionsrand entfernt





# Finger; metacarpal transfer pathology July 09, 2013

## ***Diagnose***

Fingeramputat (Dig III Hand rechts) mit zirkumferentiell in den Weichteilen wachsenden knotigen Restanteilen des epitheloiden Sarkoms vom klassischen Typ auf der Höhe der proximalen Hälfte der Grundphalanx. Nachweis von intraneural wachsendem Tumorgewebe. Beginnende Infiltration der Kortikalis der proximalen Grundphalanx ohne Einbruch in den Markraum.

Minimaler Abstand des intraneural wachsenden Tumors von 0.5 mm zum distalen Ende der ulnaren Weichteilresektionsfläche (vgl. Bilddokumentation unten).

Übrige Weichteilresektionsränder mit Abstand von >5.0 mm zum Tumor. Tumorfreier Resektionsrand des Karpalknochens.

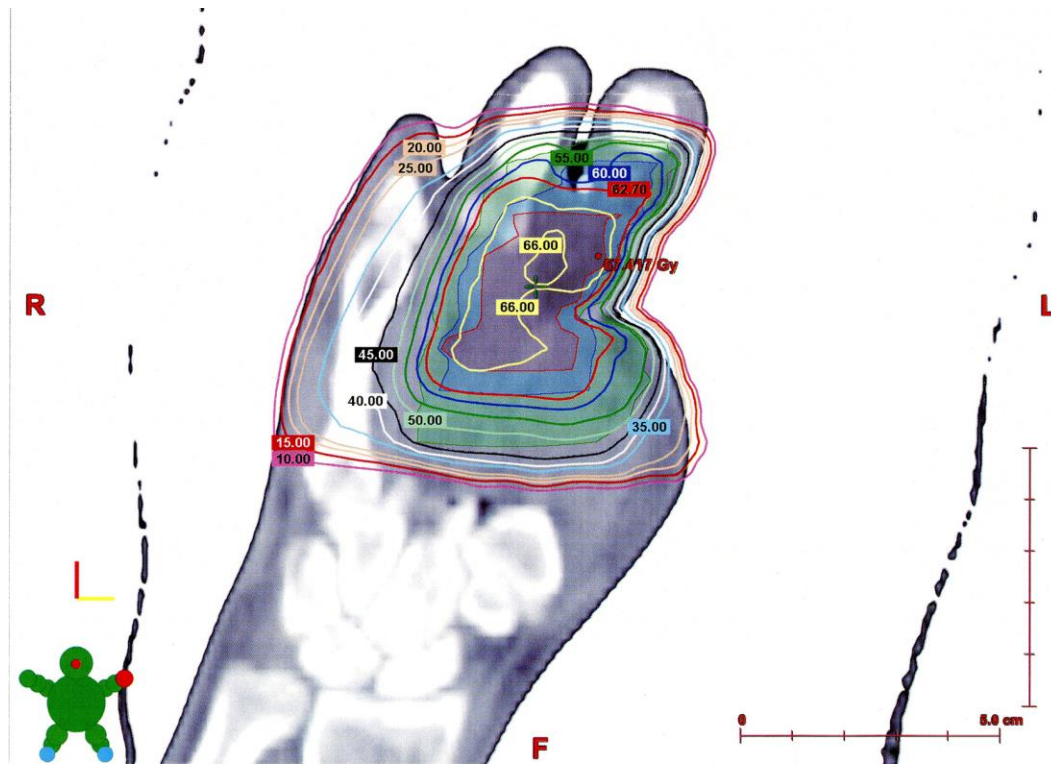
In der Immunhistochemie starke Expression der Tumorzellen für panCK intraneural an der kritischen Stellen im Bezug auf die Resektionsränder.

# Finger; metacarpal transfer

**Sarcomaboard, July 09 2013:**

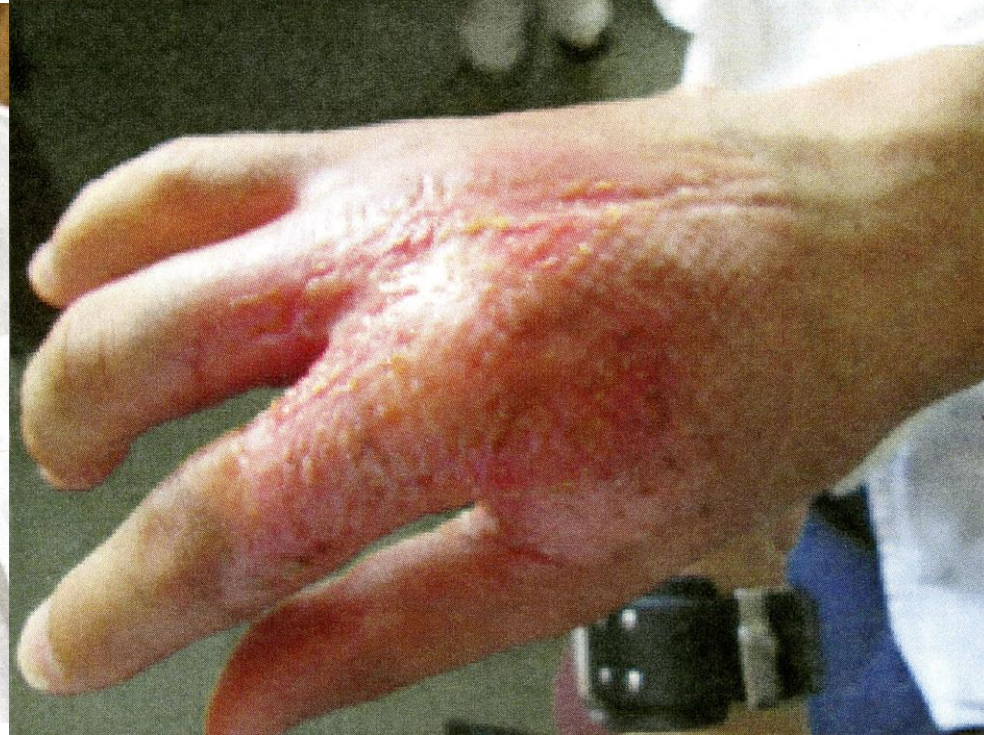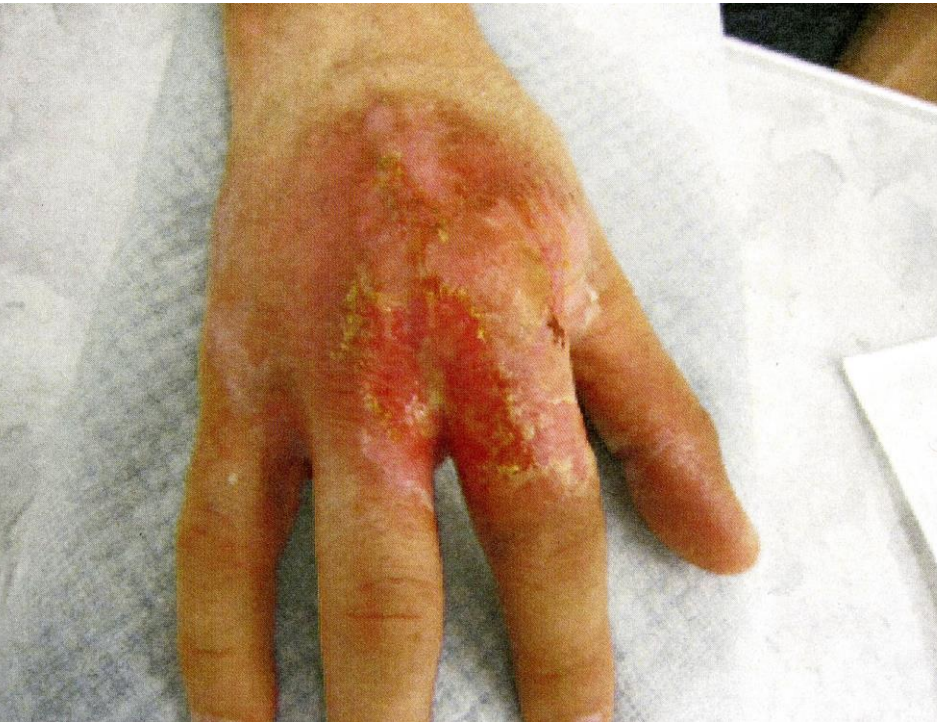- **Chemotherapy: no**
- **Surgery: rather no**
- **Radiotherapy: recommended**

# Finger; metacarpal transfer Radiotherapy October 2013





# Finger; metacarpal transfer Radiotherapy October 2013



# Finger; metacarpal transfer f-up April 2017

**No evidence of disease  
„normal“ function**